

Cardiac Manifestations of Toxocariasis: A Case Report of Loffler Endocarditis and Literature Review

Joséphine Dorin, Laura Filippetti, Anne Debourgogne, Damien Voilliot,
Olivier Huttin, Marie Machouart

► **To cite this version:**

Joséphine Dorin, Laura Filippetti, Anne Debourgogne, Damien Voilliot, Olivier Huttin, et al.. Cardiac Manifestations of Toxocariasis: A Case Report of Loffler Endocarditis and Literature Review. *Journal of Bacteriology*

Parasitology, 2015, 06 (03), pp.1000226. <<https://www.omicsonline.org/open-access/cardiac-manifestations-of-toxocariasis-a-case-report-of-loffler-endocarditis-and-literature-review-2155-9597-1000226.php?aid=52254>>. <10.4172/2155-9597.1000226>. <hal-01484282>

HAL Id: hal-01484282

<https://hal.univ-lorraine.fr/hal-01484282>

Submitted on 7 Mar 2017

HAL is a multi-disciplinary open access archive for the deposit and dissemination of scientific research documents, whether they are published or not. The documents may come from teaching and research institutions in France or abroad, or from public or private research centers.

L'archive ouverte pluridisciplinaire **HAL**, est destinée au dépôt et à la diffusion de documents scientifiques de niveau recherche, publiés ou non, émanant des établissements d'enseignement et de recherche français ou étrangers, des laboratoires publics ou privés.

Cardiac Manifestations of Toxocariasis: A Case Report of Löffler Endocarditis and Literature Review

Joséphine Dorin^{1*}, Laura Filippetti², Anne Debourgogne^{1,3}, Damien Voilliot², Olivier Huttin², and Marie Machouart^{1,3}

¹Structure de Parasitologie-Mycologie, Département de Microbiologie, Centre Hospitalo-Universitaire de Nancy (CHU-Nancy), Hôpitaux de Brabois, 11 allée du Morvan, 54511 Vandoeuvre-les-Nancy, France

²Service de Cardiologie, Centre Hospitalo-Universitaire de Nancy (CHU-Nancy), Institut Lorrain du Cœur et des Vaisseaux, 11 allée du Morvan, 54511 Vandoeuvre-les-Nancy, France

³Laboratoire Stress Immunité Pathogène - EA 7300 - Université de Lorraine, 9 avenue de la forêt de Haye, 54511 Vandoeuvre-les-Nancy, France

*Corresponding author: Joséphine Dorin, Structure de Parasitologie-Mycologie, Département de Microbiologie, Centre Hospitalo-Universitaire de Nancy (CHU-Nancy), Hôpitaux de Brabois, 11 allée du Morvan, 54511 Vandoeuvre-les-Nancy, France, Tel: +33 (0)383 154 388; Fax: +33(0)383 154 386; E-mail: j.dorin@chu-nancy.fr

Received date: February 23, 2015; Accepted date: May 20, 2015; Published date: May 25, 2015

Copyright: © 2015 Dorin, et al. This is an open-access article distributed under the terms of the Creative Commons Attribution License, which permits unrestricted use, distribution, and reproduction in any medium, provided the original author and source are credited.

Abstract

This paper reports a case of toxocariasis with cardiac manifestations. The patient was a 48-year-old man suffering from a Löffler endocarditis with hypereosinophilia. ELISA and Western blot tests confirmed the diagnosis of toxocariasis. The disease was successfully managed by a combination of albendazole and corticosteroids.

A few cases of cardiac toxocariasis have been described previously in the literature focusing on this unusual location. Eosinophils may have a key role in the pathogenesis of the disease. Therefore, clinicians should always investigate toxocariasis in case of hypereosinophilia with cardiac involvement.

Keywords: *Toxocara*; Larva migrans syndrome; Hypereosinophilia; Löffler endocarditis; Albendazole; Corticoids

Introduction

Toxocariasis is one of the most frequent zoonotic helminthiasis although its frequency is underestimated due to common asymptomatic manifestations.

Toxocara is a nematode that infects the intestine of animals and includes *Toxocara canis* in dogs and *Toxocara cati* in cats. Embryonated eggs of *Toxocara* become adults after three to four weeks and emit up to 200 000 eggs per day [1]. *Toxocara* infection in humans and other paratenic hosts is a parasitic impasse. In such hosts, L2 larvae are pending in tissues forming eosinophilic granuloma lasting several years. Contamination is mostly linked to the presence of dogs or cats in the entourage, poor hygiene, frequentation of public gardens, or in rare cases, consumption of undercooked paratenic hosts [1]. Clinical signs are extremely varied and depend on the importance of infestation and its repetition, larvae localization, and individual sensitivity.

The major clinical form is visceral larva migrans (VLM) syndrome that occurs more frequently in children in tropical countries after massive contamination. In developed countries, asymptomatic or mild forms are more common with limited infestation rates [1]. The digestive tract is the main definitive location. However, unusual localizations leading to organ damage are typically restricted to some systems including eyes, heart, lungs, skin, spleen, gastrointestinal tract, and central nervous system (CNS) [2]. Despite a favorable evolution of the disease in most cases, the outcome could be fatal if such particular localizations are infested.

In the literature, 18 observations of cardiac toxocariasis have been reported including 11 cases of myocarditis, three cases of tamponades,

three cases of Löffler fibroblastic endocarditis, and one case of myopericarditis [3-5]. This paper describes a fourth case of endocarditis [6-8] due to *Toxocara* sp. and reviews the literature describing this uncommon localization, highlighting the difficulties of follow-up.

Case Report

On August 29, 2014, a 48-year-old man with a medical history of hereditary myopathy was admitted to the University Hospital of Nancy (France) for recurrent bronchitis with fever and purpura in the lower limbs. Blood analyses revealed a small inflammatory syndrome with a C-reactive protein (CRP) value of 15 mg/L and hypereosinophilia of 13 G/L. Analyses were conducted to explain this hypereosinophilia as bacteria, viruses, autoimmune researches and also oncological marker genetic investigations sought to reveal eosinophilic leukemia; all results were negative. Parasitological examination of stools was carried out together with serological analyses for toxocariasis, toxoplasmosis, echinococcosis, and anguillulosis.

Hypereosinophilia was further investigated by transthoracic and transesophageal echocardiography, which revealed the presence of 3 cm vegetations on the left ventricular wall and a small pericardial effusion (Figure 1). A thoracic computed tomography scan confirmed these findings, together with pulmonary micronodules and hypodensity. Blood cultures were sampled to eliminate bacterial endocarditis; the results were negative.

A biopsy of the purpura lesions was performed and revealed eosinophilic infiltration in the dermis and the hypodermis compatible with the hypereosinophilic context. The diagnosis of Löffler endocarditis secondary to chronic hypereosinophilia was retained.

The medical history of the patient described the presence of anti-*Toxocara* sp. antibodies in 2007 associated with persistent hypereosinophilia (0.86 G/L). This episode was treated by a single dose of ivermectin. No serological control was performed, although the eosinophils rate was still high in 2013 at 1.5 G/L.

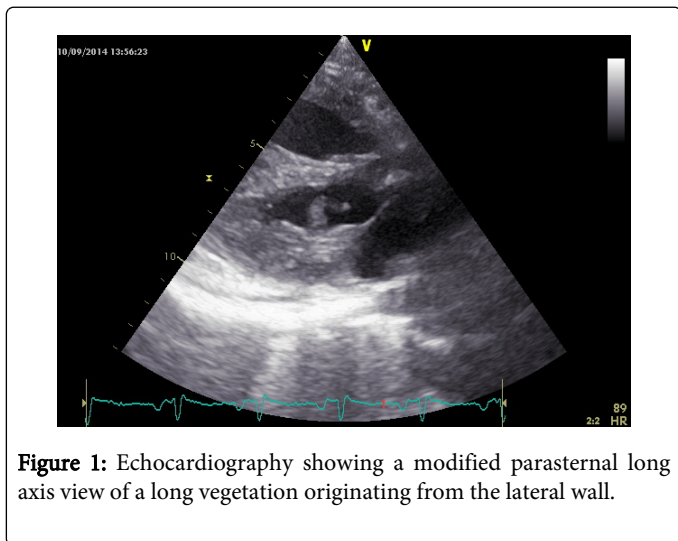


Figure 1: Echocardiography showing a modified parasternal long axis view of a long vegetation originating from the lateral wall.

During the patient's hospitalization, hypereosinophilia increased to 22 G/L. Stool examinations revealed numerous pinworm eggs (*Enterobius vermicularis*); nevertheless, this helminth was probably not the leading cause of the high hypereosinophilia because it does not usually invade human tissues. Three days later, toxocariasis serology was weakly positive (0.96 for a threshold of 1 (grey zone between 0.6 and 1) - *Toxocara canis* BORDIER Affinity Products). Confronted with these first results, a Western blot test was performed and confirmed the antibody specificity (Figure 2) (*Toxocara* Western blot LDBio diagnostics). The other serologies were all negative.

After the introduction of corticosteroids at a dose of 60 mg daily combined with albendazole at a dose of 400 mg twice daily, eosinophilia regressed to 0.38 G/L after one week. One month later, the overall clinical evolution was favorable with almost total disappearance of the cardiac vegetations.

Discussion

Hypereosinophilia may be associated with various etiologies including autoimmune or neoplastic diseases, parasites, drugs, allergic reactions, etc., justifying broad etiological investigations [2]. Helminthiasis is one of the first causes to investigate in case of hypereosinophilia, particularly if the patient has travelled in the tropics [9]. In our case, as the patient had never travelled outside France and owned cats and dogs, the most probable suspected helminth etiology was contamination by *Toxocara* sp., probably transmitted by his pets.

Biological, clinical, and epidemiological investigations are essential to confirm the diagnosis of toxocariasis. Guidance signs are represented by hypereosinophilia and an increase of total IgE. Nevertheless, definitive diagnosis is based on the search for specific antibodies (IgG) against the larval excretory-secretory (TES) antigens of *Toxocara* by ELISA techniques (enzyme-linked immunosorbent assay). Because of cross reaction with other nematodes antibodies, the test must be confirmed by Western Blot, highlighting the more specific, low molecular weight bands (Figure 2) [1]. However, a

positive immunodiagnostic test cannot distinguish between a recent infection, a past infection, or reactivation of dormant larvae. In addition, the long-term persistence of IgM antibodies and the lower affinity of early stage antibodies are not helpful. The most promising approach seems to be the detection of TES-Ag high IgG avidity excluding a recent infection over a period of three months [10]. This method is not yet widespread and thus was not performed here. However, in view of the patient's biological history, he was probably infected a long time ago without any particular symptoms and his heart damage could be more recent causing a significant increase in the eosinophil count, leading to hospitalization.




Figure 2: Positive *Toxocara* Western blot test obtained in our case. High molecular weight (HMW) bands >80 kDa associated with lower specificity and a cross reaction with other helminthiasis. Low molecular weight (LMW) bands specific of *Toxocara* antigens: a positive test highlights at least two bands between 24 and 35 kDa.

Of the 18 reported cases of toxocariasis with cardiac manifestations [3-5], with the exception of three asymptomatic cases discovered incidentally (surgery and hypereosinophilia), patients first suffered from dyspnea (nine patients), thoracic pain (five patients), edema (three patients), and extracardiac symptoms of digestive origin (two cases of abdominal pain, one case of diarrhea, and one case of hepatomegaly) or cutaneous origin (three cases of hives and in our case, purpura). Death occurred in two children with myocarditis [11].

Globally, for all cases, even if eosinophil rates are inconstantly reported, they remain often high with three reported cases of mild eosinophilia (0.5-1.5 G/L), four cases of marked eosinophilia (1.5-3 G/L), and seven cases of massive eosinophilia episodes (>3 G/L), including our patient. Eosinophils play an essential role in the pathogenesis of the disease by producing a wide range of pro-inflammatory mediators including cationic proteins, such as eosinophil major basic protein (MBP) or eosinophil peroxidase (EPO), released by degranulation. Their biological properties create direct toxicity against microorganisms, but also against host organ cells. This effect activates inflammatory cells and platelets, which contribute to local inflammation and leukocyte recruitment, leading to host organ damage [2]. In the heart, all layers can be affected by these disorders, mostly the myocardium. Three stages are commonly

described during eosinophil invasion: acute necrotizing phase, thrombotic phase, and at the end of the disease, endomyocardial fibrosis phase. Globally, toxocariasis is not easily diagnosed until the final pathological stage [3,12].

Cardiac manifestations may result from larvae invasion or inflammatory reaction; only a few reported cases have described larvae in cardiac tissues [13]. A cardiac biopsy was performed in seven cases only and - except in one case [5] - always showed inflammatory infiltrate implying eosinophils, but only two cases revealed the presence of larval debris [4]. However, as this is an invasive technique, often difficult to perform and may lead to procedural complications, it is rarely used. Transthoracic and transesophageal echocardiography is the main tool to diagnose cardiac involvement [9]. Both types of echocardiography were performed in our case and revealed the presence of several vegetations on the left ventricular wall (Figure 1).

Among the reported cases, therapeutic attitudes differed greatly: six patients were treated with a combination of corticosteroids and antiparasitic drugs such as albendazole, two were treated with corticosteroids only, three were treated with antiparasite drugs only, five were given symptomatic treatment, two patients were not treated, and treatment was not specified in two patients [3-5]. Treatment is unnecessary for asymptomatic persons; otherwise, combined therapy using corticosteroids and antiparasitic drugs such as albendazole is more frequently used. Theoretically, based on the potential symptomatology, this treatment seems to be the most appropriate, but studies including large populations are lacking [12]. Before initiating the antiparasitic treatment, an ophthalmologic examination is necessary because of the risk of a parasitic lysis that may worsen eye lesions. Treatment effectiveness should then be assessed almost one month after its completion and should reveal a decrease of clinical symptoms and eosinophilia [1]. In case of cardiac manifestations occurring during toxocariasis, there is no consensus on treatment. Finally, essential prophylactic measures must be well known to avoid worm contamination: thoroughly washing hands and vegetables, worming puppies, and protecting gardens and playgrounds from animal waste.

In conclusion, cardiac manifestations of toxocariasis are rare, but probably underestimated, and may lead to death or irreversible complications. Therefore, a diagnosis of toxocariasis must be sought as

soon as possible when faced with cardiac involvement and hypereosinophilia.

References

1. Pelloux H, Faure O (2004) Toxocariasis in adults. *Rev Med Interne* 25: 201-206.
2. Valent P, Gleich GJ, Reiter A, Roufousse F, Weller PF, et al. (2012) Pathogenesis and classification of eosinophil disorders: a review of recent developments in the field. *Expert Rev Hematol* 5: 157-176.
3. Kim JH, Chung WB, Chang KY, Ko SY, Park MH, et al. (2012) Eosinophilic myocarditis associated with visceral larva migrans caused by *Toxocara canis* infection. *J Cardiovasc Ultrasound* 20: 150-153.
4. Lemaire A, Trouillier S, Samou F, Delevaux I, Aumaitre O (2014) Visceral larva migrans with cardiac manifestation: a case report and literature review. *Rev Med Interne* 35: 831-837.
5. Park HJ, You GI, Cho KI, Yang JW, Kim SY, et al. (2014) Cardiac involvement in hypereosinophilia associated with toxocariasis. *J Cardiovasc Ultrasound* 22: 224-227.
6. De Cock C, Lemaire J, Deuvaert FE (1998) Löeffler endomyocarditis: a clinical presentation as right ventricular tumor. *J Heart Valve Dis* 7: 668-671.
7. Thomas K, Nixdorff U, Manger B, Geiler T, Lorenz HM, et al. (2000) Hypereosinophilia with myocardial involvement due to toxocariasis. Diagnosis of regional myocardial perfusion abnormalities by pulsed tissue Doppler echocardiography. *Med Klin* 95: 163-167.
8. Prunier F, Delépine S, Victor J, de Gentile L, Moreau C, et al. (2001) Löffler's fibroblastic endocarditis. A report of a case complicating toxocarosis. *Arch Mal Coeur Vaiss* 94: 226-230.
9. Harzy T, Allali F, Amine B, Rahmouni R, Hajjaj-Hassouni N (2005) Cardiac manifestations of idiopathic hypereosinophilic syndrome. *Rev Med Interne* 26: 386-392.
10. Dziemian E, Zarnowska H, Kołodziej-Sobocińska M, Machnicka B (2008) Determination of the relative avidity of the specific IgG antibodies in human toxocariasis. *Parasite Immunol* 30: 187-190.
11. Vargo TA, Singer DB, Gillatte PC, Fernbach DJ (1977) Myocarditis due to visceral larva migrans. *J Pediatr* 90: 322-323.
12. Ogbogu PU, Rosing DR, Horne MK 3rd (2007) Cardiovascular manifestations of hypereosinophilic syndromes. *Immunol Allergy Clin North Am* 27: 457-475.
13. Bolívar-Mejía A, Rodríguez-Morales AJ, Paniz-Mondolfi AE, Delgado O (2013) Cardiovascular manifestations of human toxocariasis. *Arch Cardiol México* 83:120-129.