



HAL
open science

Cancer Immunotherapy with Anti-CTLA-4 Monoclonal Antibodies Induces an Inflammatory Bowel Disease

L. Marthey, C. Mateus, C. Mussini, M. Nachury, S. Nancey, F. Grange, C. Zallot, L. Peyrin-Biroulet, J. F. Rahier, M. Bourdier de Beaugard, et al.

► **To cite this version:**

L. Marthey, C. Mateus, C. Mussini, M. Nachury, S. Nancey, et al.. Cancer Immunotherapy with Anti-CTLA-4 Monoclonal Antibodies Induces an Inflammatory Bowel Disease. *Journal of Crohn's and Colitis*, 2016, 10 (4), pp.395-401. 10.1093/ecco-jcc/jjv227 . hal-01659102

HAL Id: hal-01659102

<https://hal.univ-lorraine.fr/hal-01659102v1>

Submitted on 12 Feb 2025

HAL is a multi-disciplinary open access archive for the deposit and dissemination of scientific research documents, whether they are published or not. The documents may come from teaching and research institutions in France or abroad, or from public or private research centers.

L'archive ouverte pluridisciplinaire **HAL**, est destinée au dépôt et à la diffusion de documents scientifiques de niveau recherche, publiés ou non, émanant des établissements d'enseignement et de recherche français ou étrangers, des laboratoires publics ou privés.



Distributed under a Creative Commons Attribution 4.0 International License



Original Article

Cancer Immunotherapy with Anti-CTLA-4 Monoclonal Antibodies Induces an Inflammatory Bowel Disease

L. Marthey^{a,b}, C. Mateus^c, C. Mussini^d, M. Nachury^e, S. Nancey^f,
F. Grange^g, C. Zallot^h, L. Peyrin-Biroulet^h, J. F. Rahierⁱ, M. Bourdier de
Beauregard^j, L. Mortier^k, C. Coutzac^l, E. Soularue^a, E. Lanoy^{m,n}, N. Kapel^o,
D. Planchard^p, N. Chaput^{l,q,r}, C. Robert^c, F. Carbonnel^a

^aDepartment of Gastroenterology, Kremlin Bicêtre Hospital, Assistance publique-Hôpitaux de Paris (AP-HP), Paris Sud University, Le Kremlin Bicêtre, France ^bDepartment of Gastroenterology, Antoine Bécélère Hospital, Assistance publique-Hôpitaux de Paris (AP-HP), Paris Sud University, Clamart, France ^cDermatology Unit, Department of Medical Oncology, Gustave Roussy, Paris Sud University, Villejuif, F-94805, France ^dDepartment of Pathology, Kremlin Bicêtre Hospital, Assistance publique-Hôpitaux de Paris (AP-HP), Paris Sud University, Le Kremlin Bicêtre, France ^eDepartment of Gastroenterology, Claude Huriez Hospital, Lille, France ^fDepartment of Gastroenterology, Lyon Sud Hospital, Hospices Civils de Lyon, Pierre-Benite, France ^gDepartment of Dermatology, Robert Debré Hospital, Reims, France ^hDepartment of Gastroenterology, Nancy Hospital, Inserm U954, Lorraine University, Vandoeuvre Les Nancy, France ⁱDepartment of Hepato-Gastroenterology, CHU Dinant Godinne UCL Namur, Yvoir, Belgium ^jDepartment of Gastroenterology, Jean Minjot Hospital, Besançon, France ^kDepartment of Dermatology, Claude Huriez Hospital, Lille, France ^lLaboratoire d'Immunomonitoring en Oncologie, Gustave Roussy, Villejuif, F-94805, France ^mBiostatistics and Epidemiology Unit, Gustave-Roussy, Villejuif, France ⁿInserm Unit U1018, CESP, Paris Sud University, Paris-Saclay University, Villejuif, France ^oDepartment of Functional Coprology, Pitié Salpêtrière Hospital, Assistance publique-Hôpitaux de Paris (AP-HP), Paris, France ^pPneumology Unit, Department of Medical Oncology, Gustave Roussy, Villejuif, F-94805, France ^qCNRS, UMS 3655, Villejuif, F-94805, France ^rINSERM, US23, Villejuif, F-94805, France

Corresponding author: Professor Franck Carbonnel, Department of Gastroenterology, Kremlin Bicetre Hospital, Assistance Publique-Hopitaux de Paris (AP-HP), Paris Sud University, 78 rue du Général Leclerc, 94275 Le Kremlin Bicêtre, France. Tel: +33 1 45 21 37 27; Fax: +33 1 45 21 20 42. Email: fcarbonnel7@gmail.com

Abstract

Background: Therapeutic monoclonal anti-cytotoxic T-lymphocyte-associated antigen 4 (CTLA-4) antibodies are associated with immune-mediated enterocolitis. The aim of this study was to provide a detailed description of this entity.

Methods: We included patients with endoscopic signs of inflammation after anti-CTLA-4 infusions for cancer treatment. Other causes of enterocolitis were excluded. Clinical, biological and endoscopic data were recorded. A single pathologist reviewed endoscopic biopsies and colectomy specimens from 27 patients. Patients with and without enterocolitis after ipilimumab-treated melanoma were compared, to identify clinical factors associated with enterocolitis.

Results: Thirty-nine patients with anti-CTLA-4 enterocolitis were included (ipilimumab $n = 37$; tremelimumab $n = 2$). The most frequent symptom was diarrhoea. Ten patients had extra-intestinal manifestations. Most colonoscopies showed ulcerations involving the rectum and sigmoid, 66% of patients had extensive colitis, 55% had patchy distribution and 20% had ileal inflammation. Endoscopic colonic biopsies showed acute colitis in most patients, while half of the patients had chronic duodenitis. Thirty-five patients received steroids that led to complete clinical remission in

13 patients (37%). Twelve patients required infliximab, of whom 10 (83%) responded. Six patients underwent colectomy (perforation $n = 5$; toxic megacolon $n = 1$); one of them died postoperatively. Four patients had a persistent enterocolitis at follow-up colonoscopy. Patients with enterocolitis were more frequently prescribed NSAIDs compared with patients without enterocolitis (31 vs 5%, $p = 0.003$).

Conclusions: Ipilimumab and tremelimumab may induce a severe and extensive form of inflammatory bowel disease. Rapid escalation to infliximab should be advocated in patients who do not respond to steroids. Patients treated with anti-CTLA-4 should be advised to avoid NSAIDs.

Key Words: Anti-CTLA-4; enterocolitis; ipilimumab

1. Introduction

Anti-tumour immunotherapy has become a major therapeutic tool in oncology. Therapeutic monoclonal antibodies against cytotoxic T-lymphocyte-associated antigen 4 (CTLA-4) have been tested and are now routinely prescribed in cancer patients.

T-cell activation requires binding of the T-cell receptor to the antigen in association with MHC molecules. It also needs binding of CD80 and CD86 ligands on the antigen-presenting cells to the CD28 co-stimulatory receptor on the T cells.^{1,2} CTLA-4 is a homologue of CD28 that binds CD80 and CD86 with higher affinity, and thereby down-regulates T-cell activation. Anti CTLA-4 monoclonal antibodies block its interaction with CD80 and CD86 and favours CD28 engagement and consequently T-cell activation and proliferation.³⁻⁵ Anti-CTLA-4 antibodies might also induce the depletion of regulatory T cells (Tregs), which express CTLA-4. These cells are susceptible to antibody-dependent cell-mediated cytotoxicity after binding of anti-CTLA-4 antibody to CD16-expressing monocytes and macrophages.⁶⁻⁹ In summary, anti CTLA-4 monoclonal antibodies exert their anti-tumour effect by T-cell activation and Treg depletion.

Ipilimumab is a fully human IgG1 monoclonal antibody that binds to CTLA-4. Ipilimumab increases overall survival in patients with metastatic or advanced melanoma.¹⁰⁻¹² It received approval in 2011 for the treatment of metastatic melanoma from the United States Food and Drug Administration and the European Medicines Agency. Ipilimumab has also been proposed for the treatment of lung,¹³ ovarian,^{14,15} renal¹⁶ and prostate carcinoma.^{17,18} Tremelimumab is a fully human IgG2 monoclonal antibody that also blocks CTLA-4. It has been evaluated in the treatment of melanoma,¹⁹⁻²¹ mesothelioma²² and prostate,²³ pancreatic²⁴ and hepatocellular²⁵ carcinomas.

Blockade of CTLA-4 activates a large repertoire of T cells, not only tumour-specific T cells. It is therefore not unexpected that patients treated with ipilimumab may have immune-related events. Enterocolitis is among the most frequent immune-related adverse events associated with ipilimumab. Approximately one-third of patients treated with ipilimumab have diarrhoea, while colitis is observed in 7–22% of patients.^{19,20,26-28} Ipilimumab-induced enterocolitis has been described in case reports, small case series (including <10 patients) and data from clinical trials, all summarized in a recent systematic review.²⁹ We are not aware of any publication reporting tremelimumab-induced enterocolitis.

Gastroenterologists are increasingly faced with anti-CTLA-4-induced enterocolitis, particularly the most severe forms. There is a need for more information, such as inflammation site and endoscopic features, as well as outcomes with medical and surgical treatment. In this report we provide a detailed description of anti-CTLA-4-induced enterocolitis in a relatively large series of patients referred to inflammatory bowel disease (IBD) specialists. Our findings suggest

that anti-CTLA-4-induced enterocolitis is a particular form of IBD with similarities to both colonic Crohn's disease and ulcerative colitis.

2. Methods

We recorded anti-CTLA-4 enterocolitis cases observed between October 2010 and September 2014 following a call to the Groupe d'Etudes Thérapeutiques dans les Affections Inflammatoires Digestives (GETAID), a French-speaking group of gastroenterologists that performs clinical studies in IBD in France and Belgium. A majority of patients were recruited from Gustave Roussy and referred to the Gastroenterology Department of Bicêtre University Hospital. Patients were eligible for inclusion if they had endoscopic signs of inflammation after having received anti-CTLA-4 infusion. Other causes of enterocolitis, such as ischaemia and infection (stool test for bacterial pathogens and *Clostridium difficile* toxin), were excluded.

Ipilimumab was administered by intravenous infusion every 3 weeks during an induction phase, at a dose of 3 or 10 mg/kg of body weight. Patients could continue ipilimumab infusions with a maintenance treatment every 12 weeks in case of tumour response or stable disease. Tremelimumab was administered by intravenous infusion every 4 weeks, at a dose of 3 or 10 mg/kg of body weight. Sociodemographic, clinical, biological and endoscopic data were recorded using pre-specified forms. Gastric, duodenal and colonic endoscopic biopsies and colectomy specimens of patients referred from Gustave Roussy to Bicêtre Hospital were reviewed by a single pathologist (C. Mussini).

We classified anti-CTLA-4 enterocolitis into 3 groups based on clinical management of the enterocolitis: (1) those who had a spontaneous favourable outcome; (2) those who required steroids; and (3) those who required immediate colectomy. For each of these groups, we noted the short- and long-term outcomes of the enterocolitis. We also recorded the effects of anti-CTLA-4 re-infusions.

Finally, the association between clinical factors and occurrence of enterocolitis was studied. For this purpose, patients with melanoma treated by ipilimumab who had enterocolitis were compared with a control group of patients with melanoma treated with ipilimumab at Gustave Roussy and who did not have enterocolitis. We also performed a sensitivity analysis restricted to the patients treated at Gustave Roussy. For this purpose, we compared patients with melanoma and enterocolitis treated with ipilimumab at Gustave Roussy with a control group of patients with melanoma and no enterocolitis, treated with ipilimumab at Gustave Roussy.

Quantitative data are described with the median (range) and qualitative data are described as number and percentage. Quantitative

data were compared using Student's test and qualitative data using the χ^2 test.

The study was submitted to the ethics committee of Paris-Ile de France VII. This committee stated that there was no ethical issue related to this study.

3. Results

Seven centres participated in this study. Thirty-nine patients with anti-CTLA-4 enterocolitis were reported. The baseline characteristics of these patients are summarized in Table 1. Most patients received ipilimumab for melanoma; none of them received any concomitant chemotherapy or immunosuppressive treatment. Two patients (5%) received tremelimumab and gefitinib for non-small-cell lung carcinoma. Eighteen patients received anti-CTLA-4 at a dose of 3 mg/kg, five received a dose of 10 mg/kg and 16 received either 3 or 10 mg/kg in blinded trials (GEFTREM trial NCT02040064; BMS CA184-169 trial NCT01515189; Ipilimumab + Stereotactic Radiotherapy EUDRACT 2012-000852-32; MellpiRx trial EUDRACT 2010-020317-93; EORTC 18071 trial EUDRACT 2007-001974-10). The median number of anti-CTLA-4 infusions was 2 (1–8). Eight patients (20.5%) had a personal history of autoimmune or inflammatory disorders prior to anti-CTLA-4 infusion. One patient (2.5%) had a family history of Crohn's disease.

3.1. Clinical characteristics of anti-CTLA4 enterocolitis

The clinical characteristics of patients with anti-CTLA-4 enterocolitis are described in Table 1. The most frequent symptoms were diarrhoea

Table 1. Characteristics of patients with anti-CTLA-4-induced enterocolitis ($N = 39$).

Characteristic		
Median age, years (range)	63	23–85
Male sex	20	51%
Personal history of immune disorder		
Arthritis	3	8%
Dermatitis	5	13%
Thyroid dysfunction	2	5%
Total number of patients	8	21%
Anti-CTLA-4 indication		
Melanoma	35	90%
Prostate carcinoma	2	5%
Lung carcinoma	2	5%
Tachycardia (>100 beats/min)	22	56%
Fever	18	46%
Median body weight loss, %, (range)	8%	0–27%
Nausea–vomiting	14	36%
Diarrhoea	36	92%
Median number of stools/24h (range)	10	1–20
Haematochezia	25	64%
Abdominal pain	32	82%
Mild	4	13%
Moderate	18	56%
Severe	10	31%
Oral aphthoid ulcers	1	3%
Anal fissuration	2	5%
Anal fistula with abscess	2	5%
Intra abdominal abscess	4	10%
Colonic obstruction	1	3%
Colonic perforation	5	13%

Data are n , % unless indicated otherwise.

(92%), abdominal pain (82%), haematochezia (64%), fever (46%) and vomiting (36%). Median body weight loss was 8% (0–27). In the 36 patients who received anti-CTLA-4 without interruption, the median time between the first infusion of anti-CTLA-4 and symptoms was 34 days (3–91). Three patients discontinued ipilimumab for several months, and after re-introduction of treatment developed enterocolitis after 1, 4 and 4 infusions respectively. The median time between first symptoms and diagnosis of enterocolitis was 14 days (1–77). One patient had aphthous mouth ulcers and 3 patients had anal lesions (2 fistulas with abscesses, 2 fissures). Ten patients had one or more extra-intestinal manifestations associated with anti-CTLA-4 enterocolitis, namely arthralgia ($n = 5$), hypophysitis ($n = 2$), hepatitis ($n = 1$), nephritis ($n = 1$), pericarditis ($n = 1$), pancreatitis ($n = 1$), thyroiditis ($n = 1$) and pyoderma gangrenosum ($n = 1$). Five patients had a colon perforation, of whom 1 had a colonic obstruction and 4 had intra-abdominal abscesses. One of these patients died.

3.2. Laboratory analyses

The main biological abnormalities were anaemia (median haemoglobin level 11.6 g/dL [7–15]), increased serum C-reactive protein (CRP) (111 mg/L [5–622]) and low serum albumin levels (27 g/L [14–39]). Faecal calprotectin, measured in 8 patients at the time of enterocolitis, was markedly increased (1755 μ g/g [299–12900]). Anti-*Saccharomyces cerevisiae* antibodies [ASCA] and perinuclear antineutrophilic cytoplasmic antibodies [pANCA] were positive in 1 out of 4 and 1 out of 18 patients respectively.

3.3. Endoscopic findings in anti-CTLA-4 enterocolitis (Figure 1)

All 39 patients had endoscopic inflammation of the colon. All underwent at least sigmoidoscopy, 33 had total colonoscopy and 25 also underwent ileocolonoscopy. The most severe endoscopic lesions were erythema in 3 patients (8%), erosion in 5 (13%) and ulceration in 31 (79%). Ulcerations were observed in 17/18 patients (94%) treated with 3 mg/kg anti-CTLA-4 infusions and in 3/5 patients (60%) treated with 10 mg/kg. In 38/39 patients (97%) there was involvement of the rectum and/or sigmoid. Extensive colitis was observed in 23/35 patients (66%) and a patchy distribution in 18/33 patients (55%). Five patients had ileitis, of whom 3 had ileal ulcerations and 2 had ileal erythema. The site of ileal and colonic inflammation is shown in Table 2.

Among the 22 patients who underwent upper gastrointestinal endoscopy, one had a 2-cm ulceration of the mid-oesophagus, 9 had gastritis and 2 had erosive duodenitis.

3.4. Histological findings in anti-CTLA-4 enterocolitis (Figure 2)

The colonic biopsies of the 27 patients referred from Gustave Roussy to Bicêtre Hospital were reviewed by a single pathologist (C. Mussini). Among these, 26 had histological features of acute colitis, including either focal active colitis with patchy crypt abscesses or diffuse mucosal acute inflammation. There was no basal plasmacytosis, no atrophy, no distortion, and no branching or budding of crypts. Mild eosinophilic infiltrates and mild apoptosis were found in 19/27 and 11/27 patients respectively. Only one patient had mild chronic colitis, characterized by focal crypt distortion and branching. Two patients had superficial granulomas. There were no CMV inclusions in colonic biopsies.

The four colectomy specimens analysed showed extensive acute severe colitis with abrupt transition between ulcerations and normal

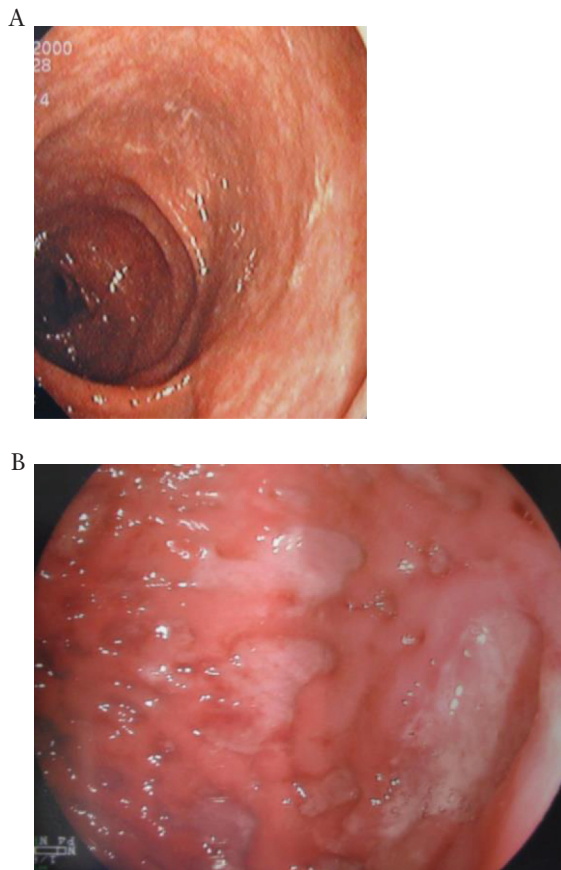


Figure 1. Endoscopic findings in patients with anti-CTLA-4 enterocolitis. (A) erythematous colitis; (B) ulcerated colitis.

Table 2. Site of inflammation on colonoscopies of patients with anti-CTLA-4 enterocolitis. Variation in the denominator is due to incomplete colonoscopy.

Site of inflammation (n/N, %)		
Ileum	5/25	20
Ascending colon	27/33	82
Transverse	28/35	80
Descending colon	35/38	92
Sigmoid colon	36/38	95
Rectum	32/39	82
Extensive colitis	23/35	66
Patchy distribution	18/33	55

mucosae. Only one patient had an association of extensive acute colitis with focal chronic colitis. None of the patients had granuloma.

Duodenal biopsies were available for review in 18 patients. The duodenal mucosa was normal in 8 patients. Ten patients had chronic duodenitis (crypt distortion, focal and heterogeneous villus shortening, increased eosinophils and mononuclear inflammatory cells in the lamina propria, and hyperplasia of Brunner's glands), often with a patchy distribution and mild activity. Granulomatous duodenitis was found in 2 patients. Gastric biopsies were available in 13 patients. Gastric mucosa was normal in 2 patients. Seven patients had chronic gastritis without *Helicobacter pylori*, often with scanty inflammatory cells and mildly active or inactive lesions, and 1 had focal active gastritis without *H. pylori*. Two patients had chronic gastritis with *H. pylori* infestation. One patient had granulomatous gastritis.

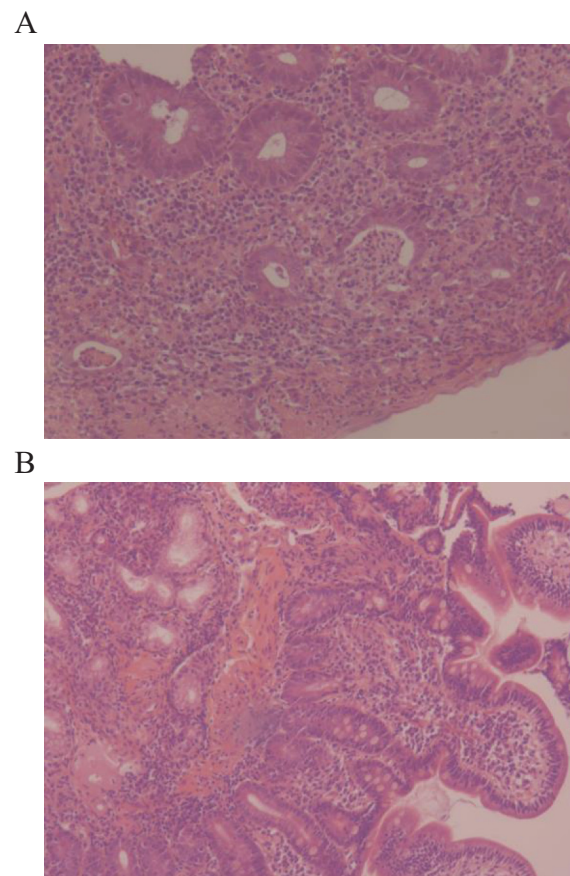


Figure 2. Histological findings of anti-CTLA-4 enterocolitis and duodenitis. (A) Acute colitis. Numerous neutrophils are present in the lamina propria with crypt abscesses (haematoxylin–eosin–safran [HES] $\times 200$). (B) Chronic duodenitis. Shortened villi and increased amount of mononuclear inflammatory cells can be seen in the lamina propria (HES, $\times 160$).

3.5. Outcomes (Figure 3)

Three patients had a spontaneous favourable evolution. One patient underwent emergency partial colectomy 7 days after diagnosis of anti-CTLA-4 enterocolitis, without having received any medical treatment. The other 35 patients received steroids (median dose 60 mg of prednisolone per day [40–120]). Overall, 13 patients out of 35 (37%) reached complete clinical remission with steroids only, including 2 patients who relapsed and subsequently responded to a new course of steroids. Twelve patients required infliximab, including one patient who received it postoperatively; 6 of them were treated with a dose of 3 mg/kg of anti-CTLA-4 and 6 with a blinded dose. All responded except for 2 patients who required emergency colectomy because of severe relapse. Six patients (15%) underwent colectomy, because of perforation ($n = 5$) or toxic megacolon ($n = 1$). Three patients had a subtotal colectomy (total colectomy with ileostomy and sigmoidostomy for 2 patients and rectal stump for 1 patient). Three patients had partial colectomy. Among them, 2 patients had a left colectomy (1 had a transverse colostomy and a sigmoidostomy and 1 had a transverse colostomy and a rectal stump), and one patient had a right colectomy with ileostomy and transverse colostomy. Patients with partial colectomy had severe inflammation of the remaining colon. Among patients with partial colectomy, 1 had a subsequent subtotal colectomy; another had postoperative infliximab infusion, and the third patient had percutaneous drainage of an intra-abdominal abscess, postoperatively. The postoperative course was complicated

in these 6 patients, including 1 postoperative death. This patient was an 83-year-old man with metastatic melanoma. He had received high-dose intravenous steroids for 8 days for ipilimumab-induced enterocolitis, and improved clinically. Subsequently, his clinical status deteriorated. Spontaneous colonic perforation and an abscess were found. The patient underwent subtotal colectomy with Hartmann's procedure, but died postoperatively. The other 5 patients had postoperative intra-abdominal abscesses, fistulae, evisceration, sepsis, pneumonia, anasarca, pulmonary embolism, cerebral thrombophlebitis and atrial fibrillation. One patient, who had undergone a subtotal colectomy, had an ileorectal anastomosis after sigmoidoscopy and had shown mucosal healing. In the days following restoration of continuity, he had severe diarrhoea and deep and extensive ulcerations of the rectum with diffuse acute colitis on biopsies. Treatment with adalimumab induced and maintained remission.

Nine patients in the cohort underwent follow-up colonoscopy at a median time of 4 months (2–7) after onset of symptoms. Five patients had normal follow-up colonoscopy; biopsies were taken in 4 of them and showed acute colitis ($n = 1$), chronic colitis ($n = 1$), lymphocytic colitis ($n = 1$) and normal mucosa ($n = 1$). Four patients had active endoscopic colitis; 2 were observed in patients in clinical remission, while 2 patients had persistent clinical and endoscopic activity 3.5 and 6 months after onset of symptoms, without having received another course of anti CTLA-4 or any other cancer treatment. Colonic biopsies of these four patients with active endoscopic colitis showed either acute colitis ($n = 2$) or chronic colitis ($n = 2$).

Finally, six patients of the cohort had an additional infusion of ipilimumab after going into enterocolitis remission. Four relapsed. One had a spontaneous favourable evolution and achieved remission 1 month after ipilimumab withdrawal. Three patients required a new steroid course, 2 of them achieved complete remission and 1 patient responded within 24 hours, but had a severe steroid-refractory relapse requiring infliximab infusion.

3.6. Clinical factors associated with ipilimumab-induced enterocolitis

Thirty-five patients with melanoma had an ipilimumab-induced enterocolitis. They were compared with 38 patients with melanoma who were treated with ipilimumab at Gustave Roussy and who had no enterocolitis (Table 3). The use of NSAIDs was more frequent among patients who had enterocolitis (31 vs 5%, $p = 0.003$). This result was confirmed by a sensitivity analysis restricted to the 24 patients with enterocolitis, who were followed at Gustave Roussy (29 vs 5%, $p = 0.009$).

4. Discussion

This study confirms that both ipilimumab and tremelimumab are associated with a risk of severe enterocolitis and highlights the similarities between anti-CTLA-4-induced enterocolitis and IBD. It shares some features with Crohn's disease. Approximately half of the patients have patchy endoscopic inflammation of the colon. Chronic inflammation of the duodenum is frequently observed, while some patients have ileitis and perianal involvement, suggesting that anti-CTLA-4 antibodies provoke diffuse inflammation of the gastrointestinal tract, predominantly in the colon. Some patients have granulomas on duodenal and colonic biopsies. Noticeably, one patient had a severe relapse of colitis of the rectal remnant after restoration of continuity and subtotal colectomy. This is similar to the role of the faecal stream in the recurrence of Crohn's disease after surgical resection.³⁰ Although unique, this observation suggests that altered crosstalk between the gut immune system and faecal microbiota has a role in anti-CTLA-4-induced enterocolitis. However, anti-CTLA-4-induced enterocolitis is also similar to ulcerative colitis. It may be associated with a diffuse and continuous inflammation of the colon without small intestinal involvement. Yet, in this study as well as in the study by Berman et al.,³¹ endoscopic biopsies

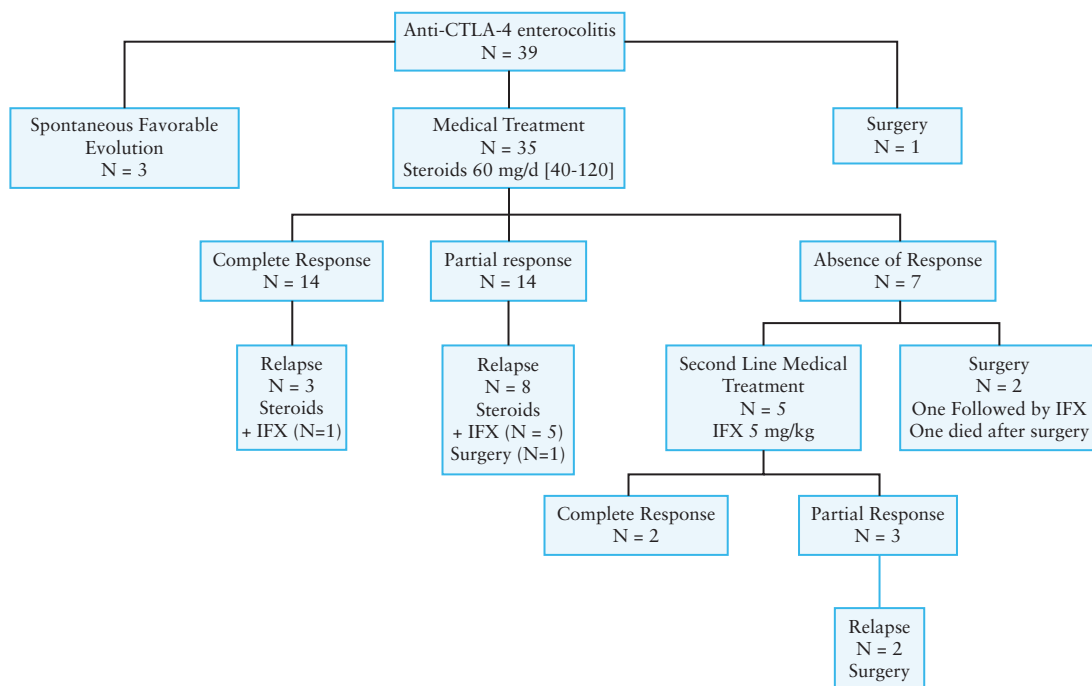


Figure 3. Outcome of patients with anti-CTLA-4 enterocolitis.

Table 3. Clinical factors associated with ipilimumab-induced enterocolitis in patients with melanoma.

Factor	Control group (N = 38)	Enterocolitis group (N = 35)	p value*
Median age, years (range)	64 (36–80)	64 (23–85)	0.940
Male sex	21 (55%)	18 (51%)	0.743
Personal history of immune disorder	4 (11%)	8 (23%)	0.155
NSAIDs prior to ipilimumab	2 (5%)	11 (31%)	0.003
Antibiotics prior to ipilimumab	7 (18%)	7 (20%)	0.864

*From χ^2 test except for age (Student's test) comparing enterocolitis group with control group.

showed acute and not chronic inflammation, as would be expected in both ulcerative colitis and Crohn's disease. These findings suggest that ipilimumab-induced enterocolitis is a peculiar entity that shares features with both Crohn's disease and ulcerative colitis. This is supported by a longitudinal study by Berman et al.,³¹ which has shown that ipilimumab induces antibodies to enteric flora, such as pANCA and anti *OmpC*. These antibodies are markers of a dysregulated mucosal immune environment in IBD and are not found in diverticulitis and infection. However, in this longitudinal study the pattern of ipilimumab-induced antibodies to microbial flora was distinct from that in classical IBD. Taken together, these findings support the concept that ipilimumab-induced enterocolitis is a peculiar form of IBD. Patients with anti-CTLA-4-induced enterocolitis may respond to steroids and infliximab therapy. Considering the short delay between anti-CTLA-4 infusion and onset of enterocolitis (34 days), as well as the high rate of colonic ulcerations, extensive colitis, steroid failure, complications and colectomy, anti-CTLA4-induced enterocolitis appears to be an accelerated and severe form of IBD.

This study provides new information about the clinical management of anti CTLA-4-induced enterocolitis. Firstly, most patients had endoscopic inflammation accessible to flexible sigmoidoscopy and could therefore avoid complete colonoscopy for diagnostic purposes. Secondly, 37% of patients were successfully treated with steroids. By comparison, 10 out of 12 patients (83%) responded to infliximab after they had failed to improve with steroids. Therefore, due to its severe course, patients with anti-CTLA-4-induced enterocolitis should be carefully monitored and a rapid escalation to infliximab should be advocated in patients who do not respond to steroids. Thirdly, when required, colectomy should be subtotal and not segmental since, in most cases, anti CTLA-4-induced enterocolitis involves the whole colon. Fourthly, patients with anti CTLA-4-induced enterocolitis are likely to relapse when they receive another course of the same drug. Whether steroid or infliximab maintenance treatment may prevent relapse of colitis in this setting remains unknown. Fifthly, endoscopic ulcerations and infliximab requirement were no more frequent among patients receiving a high dose of anti-CTLA-4, suggesting that the severity of anti-CTLA-4 enterocolitis is not dose-dependent. Sixthly, patients with ipilimumab-induced enterocolitis were more frequently prescribed NSAIDs compared with those without enterocolitis. This is in line with the predisposing role of NSAIDs in IBD.³² Patients treated with anti-CTLA4 should be advised to avoid these drugs. Lastly, and importantly, some patients had endoscopic inflammation, with or without symptoms, several months after the onset of enterocolitis, suggesting that, in some patients, anti-CTLA-4-induced enterocolitis may progress to chronic IBD.

Anti-CTLA-4 enterocolitis represents a model of T-cell-induced colitis in humans. Recently, germline heterozygous mutations of CTLA-4 have been reported in humans.^{33,34} These patients had early-onset Crohn's disease and systemic autoimmunity (lung infiltrates, cytopenia). Dysregulation of FoxP3+ Tregs, hyperactivation

of effector T cells, increased circulating memory T cells and lymphocytic infiltration of target organs were observed. Enterocolitis is almost constant in patients with CTLA-4 haplo-insufficiency and is one of the most frequent immune disorders associated with anti-CTLA-4 treatment of cancer. This might be due to the crucial role played by CTLA-4 in gut-residing Tregs. Indeed, induction and differentiation of peripheral Tregs in the intestine requires CTLA-4/CD86 and to a lesser extent CTLA-4/CD80 interactions.³⁵ Thus, anti-CTLA-4 enterocolitis could be due to a decrease in differentiation of peripheral Tregs in the intestine. Further studies are needed to elucidate the precise mechanisms of anti-CTLA-4-induced enterocolitis. Due to the similarities between IBD and CTLA-4-induced enterocolitis, these studies could shed some light on IBD mechanisms.

This study has strengths. All patients had lower gastrointestinal endoscopy, and most of them had colonoscopy. Most pathological specimens of gastrointestinal tissue were reviewed by a single pathologist. In addition, the patients included were managed by physicians specializing in IBD care. However, this strength is also a limitation. The patients described in this study were referred to IBD specialists and were therefore probably selected for their severity. Therefore, this study probably overestimates the severity of ipilimumab-induced enterocolitis.

In summary, this study describes the enterocolitis occurring as a complication of treatment with ipilimumab and tremelimumab for cancer. Anti-CTLA-4-induced enterocolitis represents a unique model of T-cell-induced colitis in humans and shares several features with IBD. These colitis forms may be severe and may progress to chronic IBD. Early recognition of the disease, and close collaboration between prescribers of anti-CTLA-4, gastroenterologists and surgeons is mandatory for optimal management of these patients.

Funding

None.

Conflict of Interest

M. Nachury reports personal fees and non-financial support from Abbvie, non-financial support from Takeda, personal fees and non-financial support from MSD and personal fees from Ferring. L. Peyrin Biroulet reports personal fees from Merck, Abbvie, Janssen, Genentech, Mitsubishi, Ferring, Norgine, Tillots, Vifor, Therakos, Pharmacosmos, Pilege, BMS, UCB Pharma, Hospira, Celltrion, Takeda, Biogaran, Boehringer-Ingelheim, Lilly, Pfizer, HAC Pharma and Index Pharmaceuticals. J. F. Rahier reports grants from MSD, grants and personal fees from Abbvie and personal fees from Hospira. N. Chaput reports grants from Cytune Pharma. C. Robert has participated in advisory boards for Roche, GSK, Merck, Novartis, Amgen, BMS and Novartis. F. Carbonnel has participated in advisory boards for Genentech, Otsuka, Vifor, MSD (oncology) and Enterome and has been a speaker for Hospira and Mayoly Splindler. Other authors do not declare any conflict of interest.

Acknowledgments

The authors wish to thank Mrs Fiona Ecartot (EA3920, University Hospital Besancon France), for editorial assistance and SIRIC SOCRATE and the MMO programme for its support to Gustave Roussy Laboratoire d'Immunomonitoring en Oncologie.

References

- Freeman GJ, Gribben JG, Boussiotis VA, *et al.* Cloning of B7-2: a CTLA-4 counter-receptor that costimulates human T cell proliferation. *Science* 1993;262:909–11.
- Azuma M, Ito D, Yagita H, *et al.* B70 antigen is a second ligand for CTLA-4 and CD28. *Nature* 1993;366:76–9.
- Krummel MF, Allison JP. CD28 and CTLA-4 have opposing effects on the response of T cells to stimulation. *J Exp Med* 1995;182:459–65.
- McCoy KD, Le Gros G. The role of CTLA-4 in the regulation of T cell immune responses. *Immunol Cell Biol* 1999;77:1–10.
- Sansom DM, Walker LS. The role of CD28 and cytotoxic T-lymphocyte antigen-4 (CTLA-4) in regulatory T-cell biology. *Immunol Rev* 2006;212:131–48.
- Bulliard Y, Jolicœur R, Windman M, *et al.* Activating Fc γ receptors contribute to the antitumor activities of immunoregulatory receptor-targeting antibodies. *J Exp Med* 2013;210:1685–93.
- Wang CJ, Kenefeck R, Wardzinski L, *et al.* Cutting edge: cell-extrinsic immune regulation by CTLA-4 expressed on conventional T cells. *J Immunol* 2012;189:1118–22.
- Romano E, Kusio-Kobialka M, Foukas PG, *et al.* Ipilimumab-dependent cell-mediated cytotoxicity of regulatory T cells ex vivo by non-classical monocytes in melanoma patients. *Proc Natl Acad Sci USA* 2015;112:6140–5.
- Selby MJ, Engelhardt JJ, Quigley M, *et al.* Anti-CTLA-4 antibodies of IgG2a isotype enhance antitumor activity through reduction of intratumoral regulatory T cells. *Cancer Immunol Res* 2013;1:32–42.
- Hodi FS, O'Day SJ, Sosman JA, *et al.* Improved survival with ipilimumab in patients with metastatic melanoma. *N Engl J Med* 2010;363:711–23.
- Robert C, Thomas L, Bondarenko I, *et al.* Ipilimumab plus dacarbazine for previously untreated metastatic melanoma. *N Engl J Med* 2011;364:2517–26.
- Maiorano M, Grob JJ, Aamdal S, *et al.* Five-year survival rates for treatment-naïve patients with advanced melanoma who received ipilimumab plus dacarbazine in a phase III trial. *J Clin Oncol* 2015;33:1191–6.
- Lynch TJ, Bondarenko I, Luft A, *et al.* Ipilimumab in combination with paclitaxel and carboplatin as first-line treatment in stage IIIB/IV non-small-cell lung cancer: results from a randomized, double-blind, multicenter phase II study. *J Clin Oncol* 2012;30:2046–54.
- Hodi FS, Mihm MC, Soiffer RJ, *et al.* Biologic activity of cytotoxic T lymphocyte-associated antigen 4 antibody blockade in previously vaccinated metastatic melanoma and ovarian carcinoma patients. *Proc Natl Acad Sci USA* 2003;100:4712–7.
- Hodi FS, Butler M, Oble DA, *et al.* Immunologic and clinical effects of antibody blockade of cytotoxic T lymphocyte-associated antigen 4 in previously vaccinated cancer patients. *Proc Natl Acad Sci USA* 2008;105:3005–10.
- Yang JC, Hughes M, Kammula U, *et al.* Ipilimumab (anti-CTLA4 antibody) causes regression of metastatic renal cell cancer associated with enteritis and hypophysitis. *J Immunother* 2007;30:825–30.
- Fong L, Kwek SS, O'Brien S, *et al.* Potentiating endogenous antitumor immunity to prostate cancer through combination immunotherapy with CTLA4 blockade and GM-CSF. *Cancer Res* 2009;69:609–15.
- Kwon ED, Drake CG, Scher HI, *et al.* Ipilimumab versus placebo after radiotherapy in patients with metastatic castration-resistant prostate cancer that had progressed after docetaxel chemotherapy (CA184-043): a multicentre, randomised, double-blind, phase 3 trial. *Lancet Oncol* 2014;15:700–12.
- Tarhini AA, Cherian J, Moschos SJ, *et al.* Safety and efficacy of combination immunotherapy with interferon alfa-2b and tremelimumab in patients with stage IV melanoma. *J Clin Oncol* 2012;30:322–8.
- Kirkwood JM, Lorigan P, Hersey P, *et al.* Phase II trial of tremelimumab (CP-675,206) in patients with advanced refractory or relapsed melanoma. *Clin Cancer Res* 2010;16:1042–8.
- Ribas A, Kefford R, Marshall MA, *et al.* Phase III randomized clinical trial comparing tremelimumab with standard-of-care chemotherapy in patients with advanced melanoma. *J Clin Oncol* 2013;31:616–22.
- Calabrò L, Morra A, Fonsatti E, *et al.* Tremelimumab for patients with chemotherapy-resistant advanced malignant mesothelioma: an open-label, single-arm, phase 2 trial. *Lancet Oncol* 2013;14:1104–11.
- McNeel DG, Smith HA, Eickhoff JC, *et al.* Phase I trial of tremelimumab in combination with short-term androgen deprivation in patients with PSA-recurrent prostate cancer. *Cancer Immunol Immunother* 2012;61:1137–47.
- Aglietta M, Barone C, Sawyer MB, *et al.* A phase I dose escalation trial of tremelimumab (CP-675,206) in combination with gemcitabine in chemotherapy-naïve patients with metastatic pancreatic cancer. *Ann Oncol* 2014;25:1750–5.
- Sangro B, Gomez-Martin C, De la Mata M, *et al.* A clinical trial of CTLA-4 blockade with tremelimumab in patients with hepatocellular carcinoma and chronic hepatitis C. *J Hepatol* 2013;59:81–8.
- Di Giacomo AM, Biagioli M, Maio M. The emerging toxicity profiles of anti-CTLA-4 antibodies across clinical indications. *Semin Oncol* 2010;37:499–507.
- Weber JS, Kähler KC, Hauschild A. Management of immune-related adverse events and kinetics of response with ipilimumab. *J Clin Oncol* 2012;30:2691–7.
- Beck KE, Blansfield JA, Tran KQ, *et al.* Enterocolitis in patients with cancer after antibody blockade of cytotoxic T-lymphocyte-associated antigen 4. *J Clin Oncol* 2006;24:2283–9.
- Gupta A, De Felice KM, Loftus EV, Khanna S. Systematic review: colitis associated with anti-CTLA-4 therapy. *Aliment Pharmacol Ther* 2015;42:406–17.
- Rutgeerts P, Goboos K, Peeters M, *et al.* Effect of faecal stream diversion on recurrence of Crohn's disease in the neoterminal ileum. *Lancet* 1991;338:771–4.
- Berman D, Parker SM, Siegel J, *et al.* Blockade of cytotoxic T-lymphocyte antigen-4 by ipilimumab results in dysregulation of gastrointestinal immunity in patients with advanced melanoma. *Cancer Immunol* 2010;10:11.
- Ananthakrishnan AN, Higuruchi LM, Huang ES, *et al.* Aspirin, nonsteroidal anti-inflammatory drug use, and risk for Crohn disease and ulcerative colitis: a cohort study. *Ann Intern Med* 2012;156:350–9.
- Zeissig S, Petersen BS, Tomczak M, *et al.* Early-onset Crohn's disease and autoimmunity associated with a variant in CTLA-4. *Gut* 2014;0:1–9.
- Kuehn HS, Ouyang W, Lo B, *et al.* Immune dysregulation in human subjects with heterozygous germline mutations in CTLA4. *Science* 2014;345:1623–7.
- Barnes MJ, Griseri T, Johnson AM, *et al.* CTLA-4 promotes Foxp3 induction and regulatory T cell accumulation in the intestinal lamina propria. *Mucosal Immunol* 2013;6:324–34.