



HAL
open science

Acquisition of accurate temporomandibular joint disc external shape and internal microstructure

L K Tappert, A. Baldit, C. Laurent, Maude Ferrari, P Lipinski

► **To cite this version:**

L K Tappert, A. Baldit, C. Laurent, Maude Ferrari, P Lipinski. Acquisition of accurate temporomandibular joint disc external shape and internal microstructure. 8th World Congress of Biomechanics, Jul 2018, Dublin, Ireland. hal-01860193

HAL Id: hal-01860193

<https://hal.univ-lorraine.fr/hal-01860193>

Submitted on 23 Aug 2018

HAL is a multi-disciplinary open access archive for the deposit and dissemination of scientific research documents, whether they are published or not. The documents may come from teaching and research institutions in France or abroad, or from public or private research centers.

L'archive ouverte pluridisciplinaire **HAL**, est destinée au dépôt et à la diffusion de documents scientifiques de niveau recherche, publiés ou non, émanant des établissements d'enseignement et de recherche français ou étrangers, des laboratoires publics ou privés.

Acquisition of accurate temporomandibular joint disc external shape and internal microstructure

L.K. Tappert¹, A. Baldit¹, C. Laurent², M. Ferrari³, P. Lipinski¹

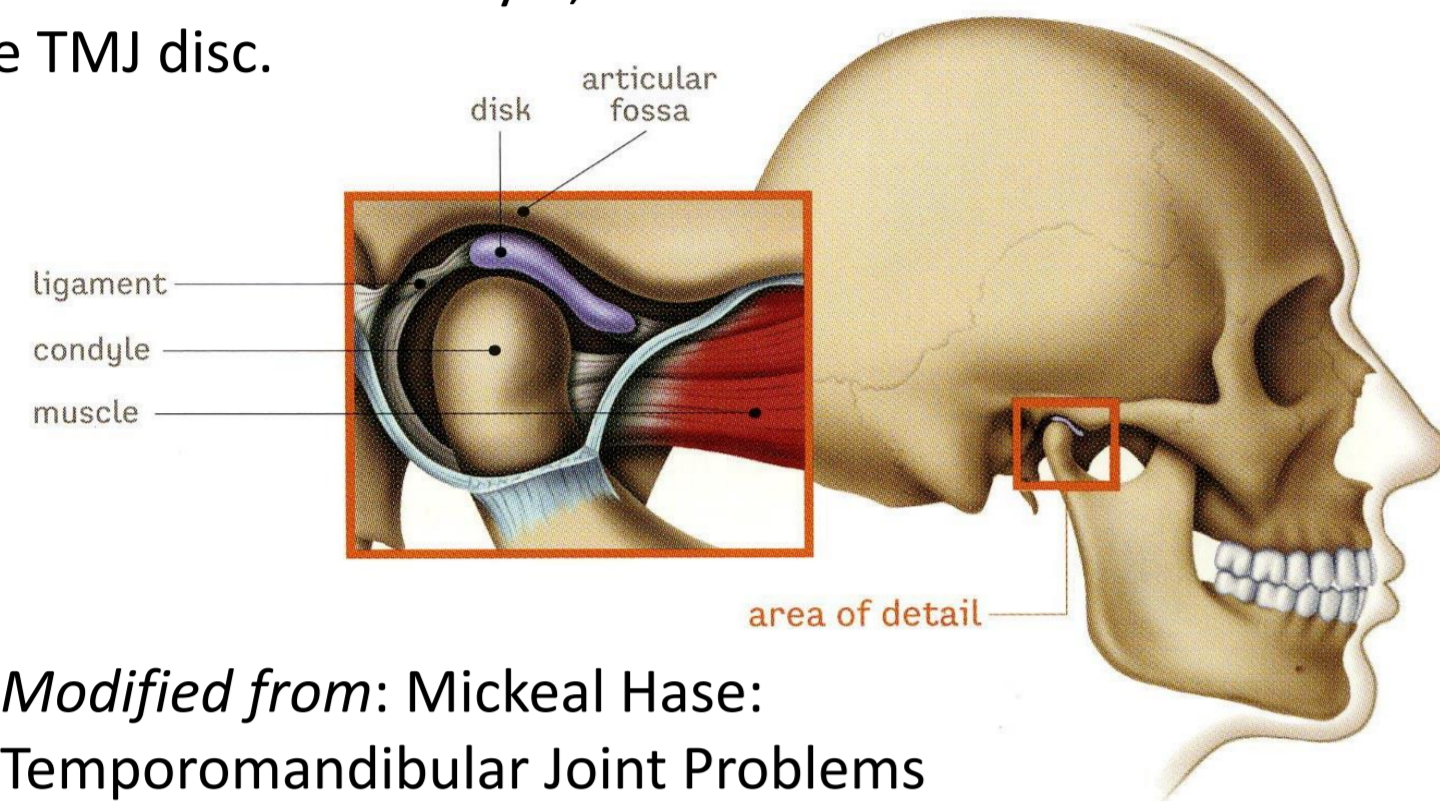
¹ Université de Lorraine, CNRS, Arts et Métiers ParisTech, LEM3, F-57000 Metz, France; ² Université de Lorraine, CNRS, Arts et Métiers ParisTech, LEM3, F-54000 Nancy, France; ³ LEMTA ENSEM - 54505 Vandoeuvre, France;

lara-kristin.tappert@univ-lorraine.fr

State of the art

The temporomandibular joint (TMJ) is composed of:

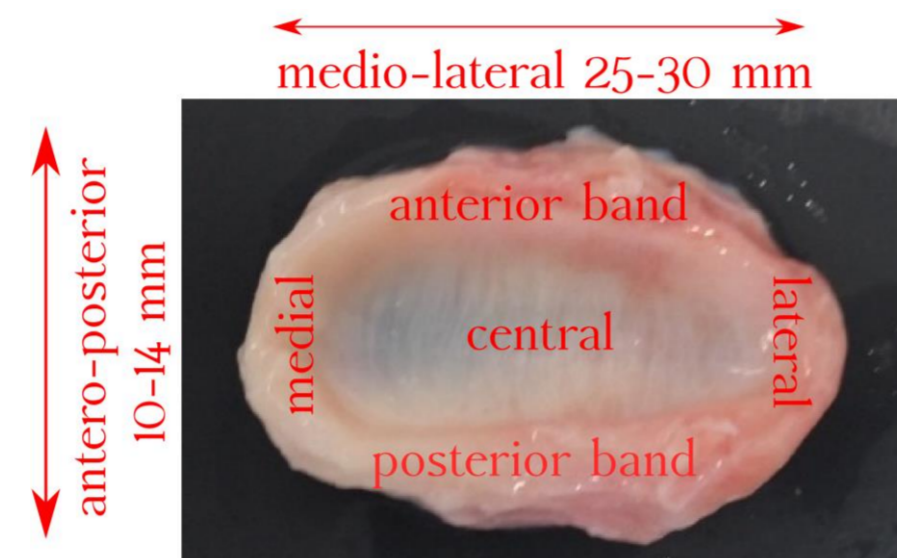
- the temporal bone,
- the mandible's condyle,
- the TMJ disc.



Modified from: Mickeal Hase: Temporomandibular Joint Problems

The TMJ disc is:

- a fibrocartilage,
- composed mainly of water, collagen type I and proteoglycans,
- associated with TMJ disorders.



Example of porcine TMJ disc; different anatomical disc zones are indicated.

Objectives of this study:

- Understanding the mechanical behaviour of the TMJ disc.
- Building up experimental database.
- Numerical investigation to determine mechanical properties.

→ Identification of disc's geometry, thickness and internal microstructure to implement them in numerical joint models.


Material and Methods

Data concerning the disc's thickness (t) are crucial to process experimental measurements but are not straightforward to obtain.

Complete TMJ discs and condyles are extracted from pig's head.

Optical 3D scan

- Atos Compact scan system (GOM, Germany)
- Two measuring techniques
 - Disc placed on condyle
 - Disc maintained in holding system (4 hooks)
- Postprocessing with CloudCompare and GOMInspect to evaluate thickness



MRI imaging

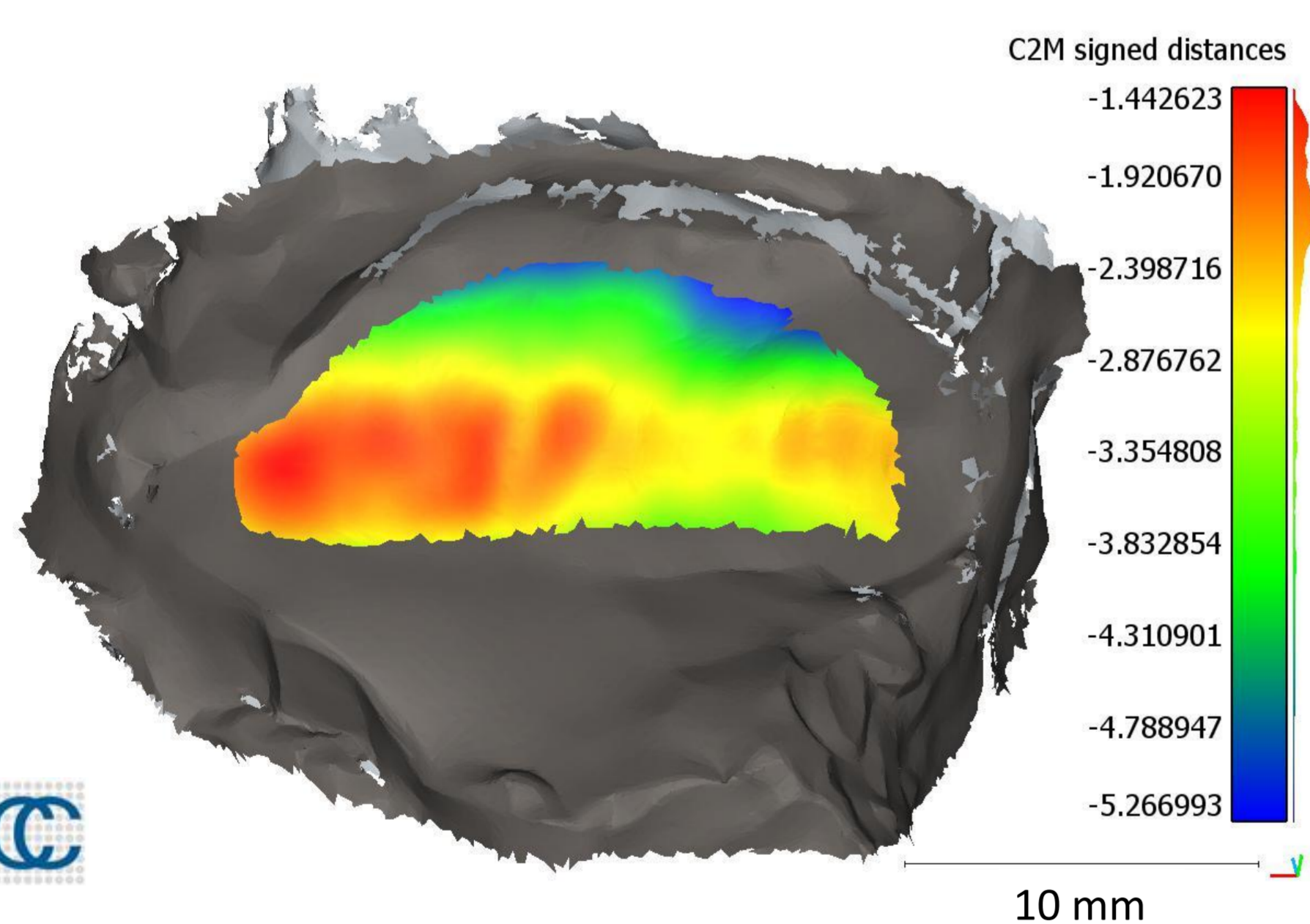
- Image acquisition with disc placed on a 3D printed condyle within physiological solution (NaCl 9g/L)
- 14.1 T vertical superconducting magnet; Avance III 600 Wide Bore (Bruker, Germany)

Parameters	Sagittal	Transversal
Type of sequence	Multi-slide multi-echo	Multi-slide multi-echo
Echo time TE [ms]	6	8.5
Repetition time TR [ms]	2000	2000
Slice thickness [mm]	0.5	0.5
Field of view [mm ²]	1.75mm x 3.51 mm	3.51mm x 3.51 mm
Matrix size	256 x 256	512 x 256
Space resolution [cm/pixel]	0.0068 x 0.0137	0.0137 x 0.0137
Acquisition time [min]	8	8

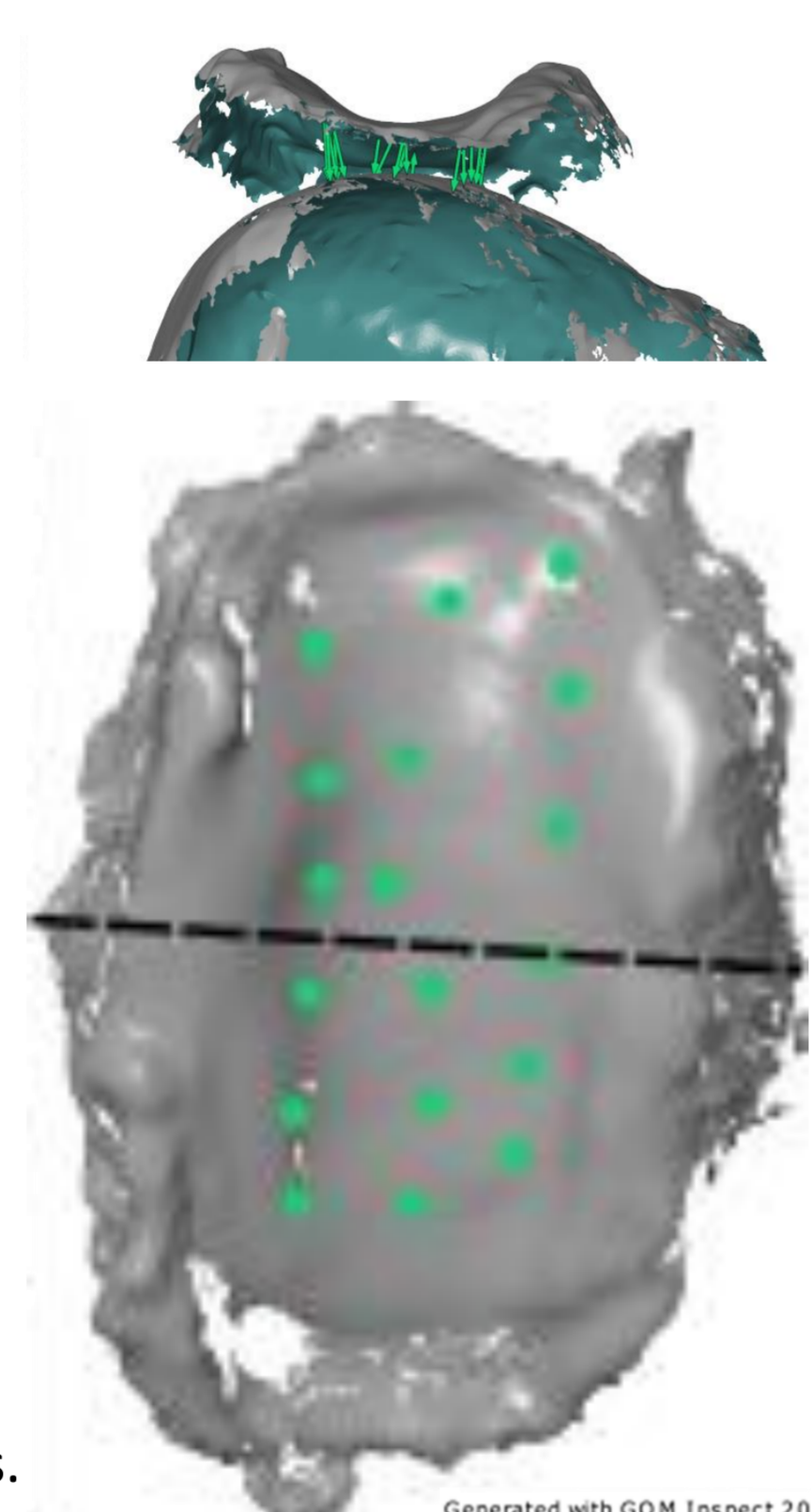


Results and Discussion

Optical scan allows reconstruction of the disc's surfaces and measurements of its thickness on areas (method II: mean $2.32 \pm \text{std } 0.56 \text{ mm}$) and on selected couples of points between the superior and inferior disc surface (method I: mean $3.24 \pm \text{std } 0.63 \text{ mm}$, $n = 18$).




→ Different thickness measurement techniques lead to consistent results.




MRI acquisition allows insight into the disc's volume. In the sagittal cut, the biconcave shape of the disc can be observed. Thickness measurements for three sagittal cuts resulted in $t = 2.75 \pm 0.75 \text{ mm}$ (mean \pm STD, $n=9$).

Sagittal cut



The transversal cut depicts the antero-posterior orientated microstructure.

Transversal cut



Outlook

