



HAL
open science

Plasmablastic lymphoma: oral presentation in patient suffering from osteradionecrosis of the jaw

C. Kichenbrand, C. Egloff, J. Guillet, B. Delaître, C. Bastien, A. Leroux, G. Dolivet, B. Phulpin

► To cite this version:

C. Kichenbrand, C. Egloff, J. Guillet, B. Delaître, C. Bastien, et al.. Plasmablastic lymphoma: oral presentation in patient suffering from osteradionecrosis of the jaw. *International Journal of Surgery Case Reports*, 2016, 29, pp.94-97. 10.1016/j.ijscr.2016.10.075 . hal-01958605

HAL Id: hal-01958605

<https://hal.univ-lorraine.fr/hal-01958605v1>

Submitted on 12 Dec 2024

HAL is a multi-disciplinary open access archive for the deposit and dissemination of scientific research documents, whether they are published or not. The documents may come from teaching and research institutions in France or abroad, or from public or private research centers.

L'archive ouverte pluridisciplinaire **HAL**, est destinée au dépôt et à la diffusion de documents scientifiques de niveau recherche, publiés ou non, émanant des établissements d'enseignement et de recherche français ou étrangers, des laboratoires publics ou privés.



Distributed under a Creative Commons Attribution - NonCommercial - NoDerivatives 4.0 International License



ELSEVIER

Contents lists available at ScienceDirect

International Journal of Surgery Case Reports

journal homepage: www.casereports.com

Plasmablastic lymphoma: oral presentation in patient suffering from osteoradionecrosis of the jaw



C. Kichenbrand^a, C. Egloff^b, J. Guillet^{a,b}, B. Delaître^a, C. Bastien^c, A. Leroux^d, G. Dolivet^b, B. Phulpin^{a,b,*}

^a Oral Surgery Department, Faculty of Dentistry, Nancy University, 96 avenue Maréchal de Lattre de Tassigny, BP 50208, 54004 Nancy, France

^b Head and Neck Surgery and Dental Units, Oncologic Surgery department, Institut de Cancérologie de Lorraine, Avenue de Bourgogne, 54519 Vandoeuvre-lès-Nancy, France

^c Pathological anatomy and cytology Department, University Hospital, 5 rue du Morvan, 54500 Vandoeuvre-lès-Nancy, France

^d Pathology and Tumor Biology Department, Institut de Cancérologie de Lorraine, Avenue de Bourgogne, 54519 Vandoeuvre-lès-Nancy, France

ARTICLE INFO

Article history:

Received 5 September 2016

Accepted 30 October 2016

Available online 3 November 2016

Keywords:

Plasmablastic lymphoma

Osteoradionecrosis

Radiotherapy

Head and neck oncology

ABSTRACT

INTRODUCTION: We describe here an unusual presentation of a plasmablastic lymphoma in a patient suffering from an osteoradionecrosis of the jaw.

PRESENTATION OF CASE: We report the case of a 64-year-old patient who was followed up on oncology because of an oropharyngeal cancer treated by a combined procedure of both surgery and radio-chemotherapy procedure. This patient developed an osteoradionecrosis of the jaw. In the vicinity of this necrotic area appeared an ulceration which could evoke a new necrotic area. Given the persistence of this ulceration, a biopsy was performed which highlighted a plasmablastic lymphoma oral localization.

DISCUSSION: The plasmablastic lymphoma, belonging to the diffuse large B-cell lymphoma family, is a very aggressive and unusual form of cancer with poor prognosis. If it is found mainly in patients with positive HIV, in whom it was first described, it is also found in immunosuppressed patients such as transplanted patients or patients suffering from leukaemia.

CONCLUSION: Plasmablastic lymphoma is a rare and an aggressive pathology in immunocompetent patients.

© 2016 The Authors. Published by Elsevier Ltd on behalf of IJS Publishing Group Ltd. This is an open access article under the CC BY-NC-ND license (<http://creativecommons.org/licenses/by-nc-nd/4.0/>).

1. Introduction

We describe here an unusual presentation of a plasmablastic lymphoma in a patient suffering from an osteonecrosis of the jaw. We will also discuss the diagnostic pitfalls as well as present a short literature review.

2. Presentation of case

M. S., 64 years old, had a primitive right oropharyngeal tumour ranked T3N1M0, for which he was treated by a surgery associated with radio-chemotherapy. This patient had a smoking and alcoholism background, and a gastro oesophageal reflux disease.

In December 2008, he had an initial dental consultation before radiotherapy (Fig. 1). The field of irradiation included the whole maxillary and the bilateral posterior mandibular areas up to the

second premolars. Consequently teeth number 37/38/47/48 were extracted and the healing was acquired before the radiotherapy began. A prevention of radio-induced tooth decay was instated with a daily local fluoridation.

In May 2009, the patient came back for a routine check. He no longer wore his fluoridation mouthguard. Consequently we observed teeth decay. Furthermore, an area of bone exposition (3 mm large, 17 mm long) was found on the mandibular left molar area. Bone sequestra were removed. We insisted on the necessity of teeth brushing and daily fluoride gel application. The patient came in for regular check-ups and three months later we noted a slow but progressive epithelialization on the necrotic area. Due to the remoteness of his home he was sent back to his treating dentist for dental follow-up and prosthetic rehabilitation.

In December 2010, the patient developed a cancer recurrence on the soft palate and right tonsil, successfully treated by a single surgery.

In May 2011, the patient came back at the request of his radio-therapist. As he was not compliant with oral hygiene and fluoride gel application, all the remaining teeth presented important decays. Consequently the 21 remaining teeth were removed under general anesthesia and Amoxicillin/Clavulanic acid (3 g per day, during

* Corresponding author at: Head and Neck Surgery and Dental Units, Oncologic Surgery Department, Institut de Cancérologie de Lorraine, Avenue de Bourgogne, 54519 Vandoeuvre-lès-Nancy, France.

E-mail address: b.phulpin@nancy.unicancer.fr (B. Phulpin).

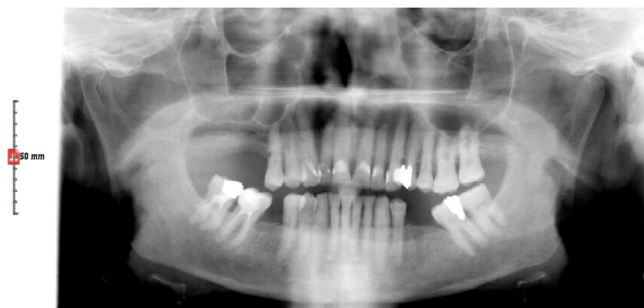

Fig. 1. First dental panoramic x-ray images (December 2008).

10 day) was prescribed. Postoperatively the healing was on the good way. Consequently the patient was sent to his treating dentist to perform regular control.

In October 2011, the patient presented an osteoradionecrosis with 3 bone exposure areas: one (2 mm) facing the lower premolar area, one (3 mm) on the right retromolar process and another one on the top right molar area. A bone milling until having a bone bleeding was performed, the patient was treated with antibiotics (Amoxicillin/Clavulanic acid 3 g per day, during three weeks) and local cleaning with chlorhexidine. The patient was followed every 2 months all along the year 2012.

At each time we noticed a very slow but favourable cicatrisation, despite the persistence of a small bone exposure on the right tuber maxillae (4 mm). During the same period the patient was examined by both his surgeon and radiotherapist, who found no clinical or biological abnormality.

On February 2013, an asymptomatic ulceration (diameter 1.5 cm) with an erythematous border was observed on the right maxillary tuberosity. The patient was seen with a dental panoramic x-ray images and a cone beam witch highlighted a bone necro-

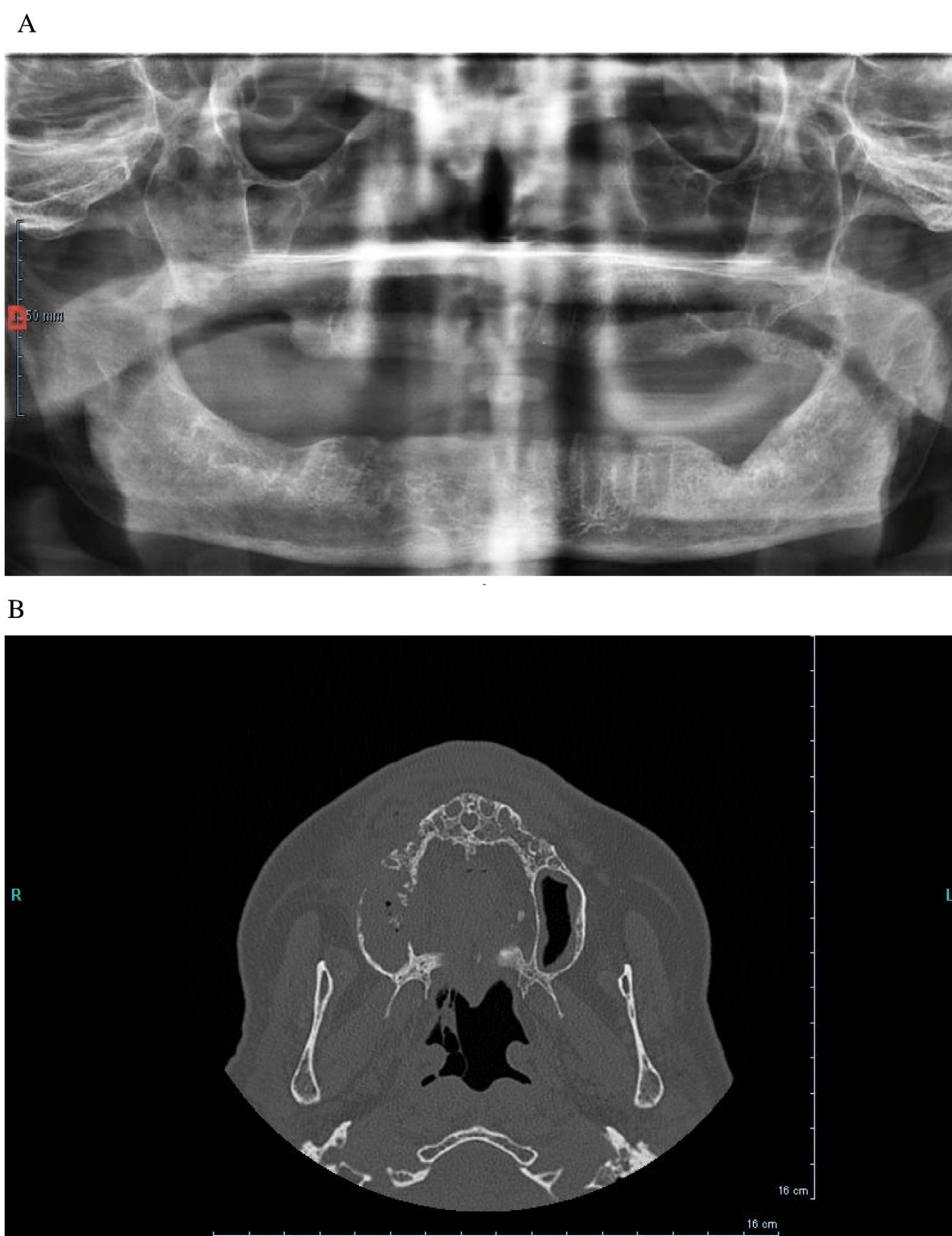


Fig. 2. Imaging highlighting a bone necrosis.

A: Second dental panoramic x-ray images (January 2013).

B: Cone beam slide.

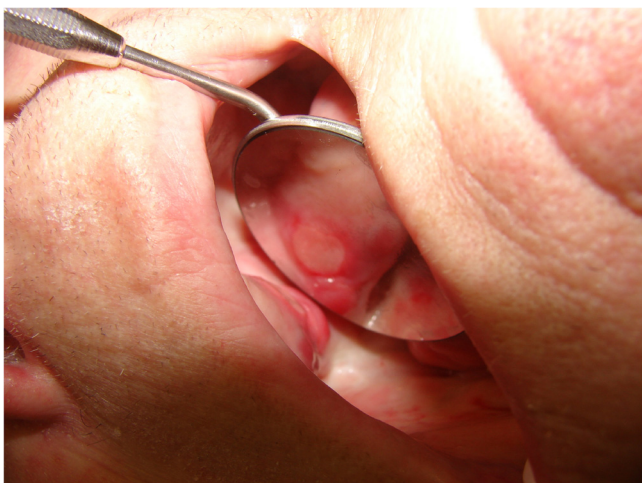

Fig. 3. Aspect of the buccal ulceration.

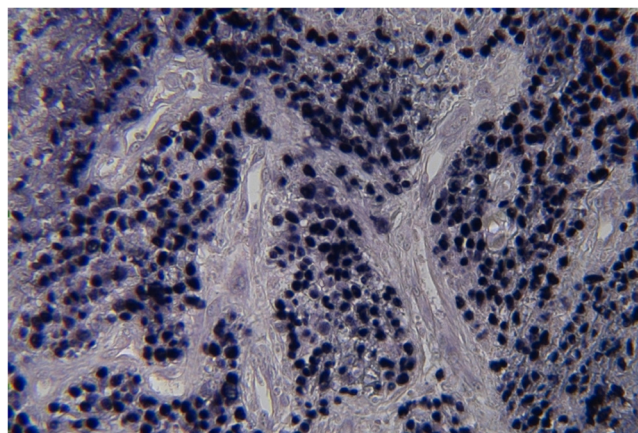


Fig. 5. In situ hybridization with EBER probes, presence of EBV transcript in every lymphomatic cells.

sis (Fig. 2). Due to the persistence of the ulceration, a biopsy was performed (Fig. 3).

The pathology results revealed a malpighian mucosa with a lymphomatic proliferation, made of large cells, some with a plasmocytoid aspect, an abundant cytoplasm, eccentrically placed nuclei, hypertrophic nucleoli, and hindwings chromatin (Fig. 4). The immunohistochemistry review was negative for the CD 20, CD 10, BCL 2 and CD 30 cells, but found positive CD 79 cells and many tumoral positive CD 38 cells. The histological type was in favour of a plasmablastic lymphoma. A second examination and a research of Eptsein Barr Virus were performed. In situ hybridization made with EBER probe points revealed the presence of EBV transcript in every lymphomatic cells (Fig. 5). Considering this diagnosis, the patient was sent to the haematologist. Unfortunately the patient died six months after diagnosis.

3. Discussion

Hematologic malignancies include a wide range of pathologies. Among them, the plasmablastic lymphoma, belonging to the diffuse large B-cell lymphoma family, is a very aggressive and unusual form of cancer with poor prognosis [1–5].

Its oral presentation has been first described in HIV positive patients [4–6], but can also be found on other immunosuppression cases (chemotherapy, leukaemia, transplantation...). The plasmablastic lymphoma preferential localization is the gum, the floor of the mouth and the palate [3].

It is histologically characterised by the proliferation of large plasmablastic-like monomorphic cells with eccentrically placed nuclei, an abundant cytoplasm and a high proliferation index [3,7].

In this case, the diagnosis of lymphoma was done lately because of the lack of specificity of plasmablastic presentation and because of the presence of other oral lesions related to osteoradionecrosis and radiotherapy adverse effects.

Indeed, the suspect lesion appeared after tooth extractions in irradiated fields and had a similar presentation to osteoradionecrosis lesions: gingival inflammation, bone exposure and persistence of the injury for more than few days [8].

Furthermore, normal biological and clinical check-ups did not suggest a recurrence or a new cancer.

The diagnosis of plasmablastic lymphoma was achieved here on biopsy and imaging and not thanks to the specificity of oral associated lesions.

There are no standardized treatments but the main option is chemotherapy, despite of its contested effectiveness [9].

4. Conclusion

The plasmablastic lymphoma is a rare and an aggressive pathology in immunocompetent patients. Behind a persistant buccal ulceration, even in a context of osteoradionecrosis in which the ulceration preceded the bone exposition, a biopsy must be performed.

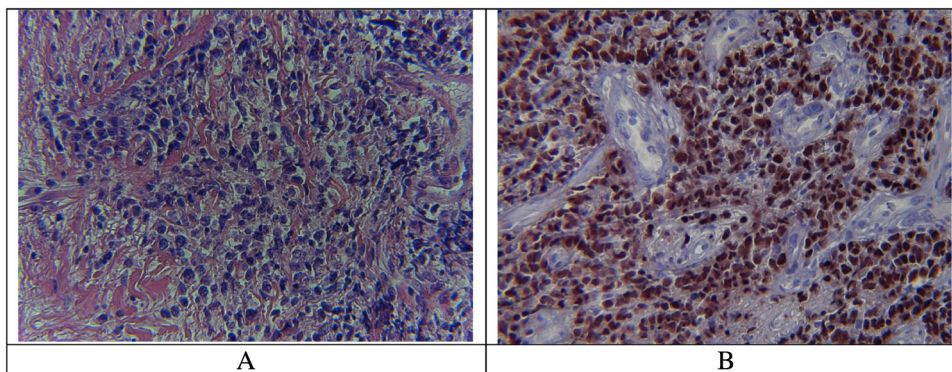


Fig. 4. Histological analysis.
A: Abnormal cells pointed by HES coloration (×400).
B: Histological coloration showing cellular abnormalities and plasmablastic cells (×20).

Conflict of interest

No conflict of interest declared.

Sources of funding

No source of funding.

Ethical approval

No research in this case report

Consent

Written informed consent was obtained from the patient for publication of this case report and accompanying images. A copy of the written consent is available for review by the Editor-in-Chief of this journal on request.

Author's contribution

Conception and design of the study, or acquisition of data, or analysis and interpretation of data: C. Kichenbrand, C. Bastien, A. Leroux, B. Phulpin

Drafting the article or revising it critically for important intellectual content: C. Kichenbrand, J. Guillet, B. Delaître, G. Dolivet, B. Phulpin

Final approval of the version to be submitted: C. Kichenbrand, C. Egloff, G. Dolivet, B. Phulpin

Registration of research studies

No research.

Guarantor

Dr Bérengère Phulpin.

References

- [1] G. Hauke, J.T. Epplen, A. Hinkkanen, N. Freudenberg, G. Kochling, H.H. Peter, Malignant plasmoblastic lymphoma with monoclonal IgG kappa immunoglobulin and detectable immunoglobulin C-delta genes, *Med. Klin. (Munich)* 83 (7) (1988) 246–250.
- [2] S.H. Swerdlow, E. Campo, S.A. Pileri, N.L. Harris, H. Stein, R. Siebert, et al., The 2016 revision of the World Health Organization classification of lymphoid neoplasms, *Blood* 127 (20) (2016) 2375–2390.
- [3] L. Colomo, F. Loong, S. Rives, S. Pittaluga, A. Martinez, A. Lopez-Guillermo, et al., Diffuse large B-cell lymphomas with plasmablastic differentiation represent a heterogeneous group of disease entities, *Am. J. Surg. Pathol.* 28 (6) (2004) 736–747.
- [4] H.J. Delecluse, I. Anagnostopoulos, F. Dallenbach, M. Hummel, T. Marafioti, U. Schneider, et al., Plasmablastic lymphomas of the oral cavity: a new entity associated with the human immunodeficiency virus infection, *Blood* 89 (4) (1997) 1413–1420.
- [5] H.Y. Dong, D.T. Scadden, L. de Leval, Z. Tang, P.G. Isaacson, N.L. Harris, Plasmablastic lymphoma in HIV-positive patients: an aggressive Epstein-Barr virus-associated extramedullary plasmacytic neoplasm, *Am. J. Surg. Pathol.* 29 (12) (2005) 1633–1641.
- [6] C.M. Flaitz, C.M. Nichols, D.M. Walling, M.J. Hicks, Plasmablastic lymphoma: an HIV-associated entity with primary oral manifestations, *Oral Oncol.* 38 (1) (2002) 96–102.
- [7] G.S. Folk, S.L. Abbondanzo, E.L. Childers, R.D. Foss, Plasmablastic lymphoma: a clinicopathologic correlation, *Ann. Diagn. Pathol.* 10 (1) (2006) 8–12.
- [8] A. Gevorgyan, K. Wong, I. Poon, N. Blanas, D.J. Enepekides, K.M. Higgins, Osteoradionecrosis of the mandible: a case series at a single institution, *J. Otolaryngol. Head Neck Surg.* 42 (2013) 46.
- [9] A. Valera, O. Balague, L. Colomo, A. Martinez, J. Delabie, L. Taddesse-Heath, et al., IG/MYC rearrangements are the main cytogenetic alteration in plasmablastic lymphomas, *Am. J. Surg. Pathol.* 34 (11) (2010) 1686–1694.

Open Access

This article is published Open Access at [sciencedirect.com](https://www.sciencedirect.com). It is distributed under the [IJSCR Supplemental terms and conditions](#), which permits unrestricted non commercial use, distribution, and reproduction in any medium, provided the original authors and source are credited.