

***Fusarium* infections: epidemiological aspects over 10 years in a university hospital in  
France**

Benoît Thomas <sup>1,3\*</sup>, Nelly Contet Audonneau <sup>1</sup>, Marie Machouart <sup>1,2</sup>, Anne Debourgogne <sup>1,2</sup>

<sup>1</sup> Université de Lorraine, CHRU-Nancy, laboratoire de Parasitologie Mycologie, F54000, France

<sup>2</sup> Université de Lorraine, SIMPA, F-54000 Nancy, France

<sup>3</sup> Laboratoire de Biologie Médicale, Hôpitaux Privés de Metz, 13 rue de la gendarmerie, 57000 Metz, France

\* Corresponding author :

Dr. Benoît Thomas

Laboratoire de Biologie Médicale, Hôpitaux Privés de Metz, 13 rue de la gendarmerie, 57000  
Metz, France

Phone: 0033 (0)3-83-15-43-96, fax: 0033 (0)3-83-15-43-86

Mail: [benoit.thomas@hp-metz.fr](mailto:benoit.thomas@hp-metz.fr)

## **ABSTRACT**

**Background:** *Fusarium* is an environmental mold that causes deep or superficial mycosis in immunocompromised or immunocompetent patients respectively.

**Methods:** This epidemiological study evaluated the frequency of *Fusarium* infections in our university hospital center in France over a decade from 2007 to 2016 and its representativeness in the main clinical infections.

**Results:** A total of 715 *Fusarium* sp. were isolated from various sampling sites.. *Fusarium* was detected in 0.47% of blood cultures, 31.1% of ophthalmic samples, and 8.48% of nail samples. The frequency of *Fusarium* infections was stable over this decade.

**Conclusions:** The main *Fusarium* species complexes recorded in this study were *Fusarium oxysporum species complex* and *Fusarium solani species complex*, indicating the importance of *Fusarium* as a fungal agent that should be considered in clinical practice. A focus on invasive fusarioses shows that they all occur in hematology patients.

### **Keywords:**

*Fusarium* – fusariosis – keratitis – onychomycosis - fungemia

## INTRODUCTION

*Fusarium* species are molds largely distributed in the environment, including water and soil, and are significant plant pathogens [1]. In immunocompetent patients, the genus *Fusarium* causes exclusively localized pathology; however, in immunocompromised hosts, principally burn and hematological patients, the infections are locally invasive or disseminated [2]. The most frequent fungal infections caused by *Fusarium* are onychomycosis and keratitis [3], although other clinical presentations are observed, such as fungemia, mycetoma, skin infection, lung disease (including allergic disease, hypersensitivity pneumonitis, colonization of a pre-existing cavity, pneumonia in severely immunocompromised patients), and other rare infections (endocarditis, urinary tract infection, osteomyelitis, etc.) [4,5,6,7]. The genus *Fusarium* is divided into phylogenetic species complexes. The most frequent involved in human infections are *Fusarium solani* species complex (FSSC), *Fusarium oxysporum* species complex (FOSC), *Fusarium dimerum* species complex (FDSC), *Gibberella fujikuroi* species complex (GFSC), and *Fusarium incarnatum - Fusarium equiseti* species complex (FIESC) [8]. All antifungals used in clinical practices have shown poor *in vitro* activity against these fungi [8,9]. No recommendation currently exists for the treatment of onychomycosis and keratitis caused by *Fusarium* species. Conversely, voriconazole is recommended for the treatment of invasive fusariosis [10,11].

The aim of this study was to evaluate the frequency of *Fusarium* infections in our university hospital center in France. This retrospective study over a decade from 2007 to 2016 focused on the evolution of the number of *Fusarium* isolates, their representativeness in the related clinical infections (septicemia, ophthalmic involvement, and onychomycosis), and the species complexes involved.

## **MATERIALS AND METHODS**

This study received an ethics committee approval. It focused on the local epidemiology of fusariosis in a 1600-bed university hospital over a decade from 2007 to 2016. This center has a hematology sector with 15,000 days of hospitalization per year and carries out 140 bone marrow transplants per year.

### **Data collection**

All analyses performed by the laboratory were registered in the laboratory computing system (GLIMS V8.11.6). The study focused on the *Fusarium* strains involved in human pathology and the isolates involved in a possible colonization were not considered. For nail samples, only pure cultures for *Fusarium* were counted. For other sample types, each strain is considered to be infectious and was counted. The data collected were as follows: the number of *Fusarium* cultures by species complex, by sample type, by clinical origin, and by year; the number of mycological samples by year; the number of positive mycological cultures by origin and by year; the number of mycological positive cultures by year with a description of the fungi isolated in blood cultures, ophthalmologic samples, and nail samples.

For invasive fusarioses the type of immunosuppression has been sought on the patient's clinical record.

Identification of fungal species was carried out using phenotypic methods, except for cases involved in invasive fusarioses diagnosed after 2009 for which a molecular identification by translation elongation factor (TEF) sequencing was performed [12].

### **Indicators**

Two indicators were defined: i) the annual cases numbers of superficial or deep fusarioses and the types of specimens concerned; ii) the proportion of *Fusarium* involved in the main clinical

forms (sepsis, keratitis, and onychomycosis) calculated by the ratio: number of *Fusarium* isolates / number of positive samples.

## Statistics

For every parameter, mean (m), standard deviation (SD), and variation coefficient (CV) were calculated. One point over 2 SD from the mean was considered as significantly different from the mean. The Mann-Kendall test was applied to show the evolution of the parameters. XLSTAT 2017.02 was used. The level of alpha risk was 5%.

## RESULTS

### Evolution of *Fusarium* sp. culture

During the study period, 715 *Fusarium* sp. involved in pathology were isolated from various sampling sites (Figure 1).

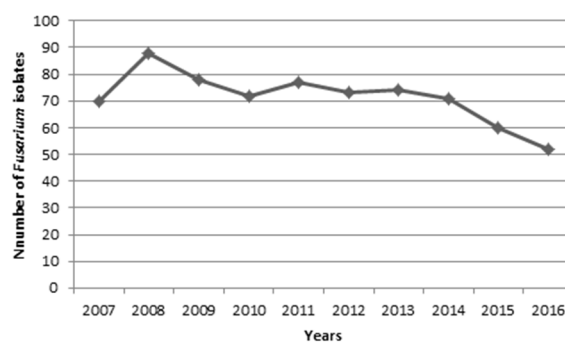


Figure 1: Evolution of the number of *Fusarium* isolates between 2007 and 2016.

The average number of *Fusarium* isolates per year is 71.5 and no year is moving away from 2 standard deviations despite a decrease in the number of clinical isolates in 2015 and 2016.

### Type of the positive specimens

Of the 715 strains of *Fusarium* isolated in the laboratory in the study period, a large majority were isolated from 597 toe nail samples (83.5%) followed by 58 finger nail samples (8.1%).

Ophthalmic samples represented 5.6% (40) and blood cultures only 1.1% (8) (Figure 2).

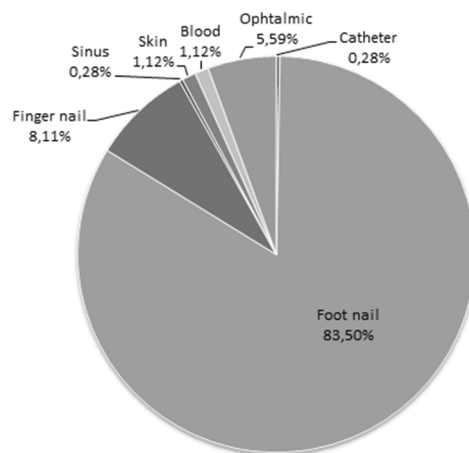
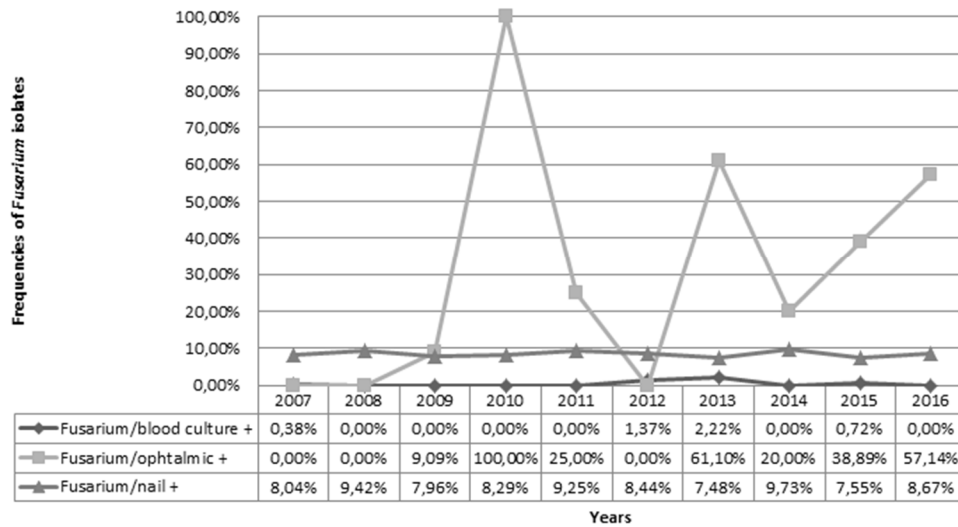


Figure 2: Nature of the *Fusarium* positive samples.

### Representativeness of *Fusarium* in the main clinical infections

Concerning fungemia, *Fusarium* was isolated in the study period on average in 0.47% (SD = 0.77) of fungi-positive blood cultures (Figure 3).



**Figure 3: Evolution of the frequencies of *Fusarium* isolates in the main clinical sites in the study period.**

Fusariosis represents a rare etiology of fungemia in our center, like scedosporiosis, with less than 1%, whereas *Candida albicans* (49.73%), *Candida glabrata* (19.10%), and *Candida parapsilosis* (15.60%) are the main fungal agents involved. No trend was noted over this period ( $p = 0.760$ ).

Concerning keratitis, *Fusarium* was isolated on average in 31.1% (SD = 0.332) of positive ophthalmic samples (Figure 3). No trend was highlighted ( $p = 0.123$ ) despite great interannual variability. *Fusarium* (26.56%) represented the most frequent fungus isolated from ophthalmic samples followed by *Candida parapsilosis* (17.97%), *Candida lipolytica* (16.41%), and *Candida albicans* (10.94%; Figure 3).

Concerning onychomycosis, *Fusarium* was isolated on average in 8.48% (SD = 0.78) of positive nail cultures (figure 3). No trend was recorded ( $p = 1.000$ ). *Fusarium* was the fourth-most filamentous fungus isolated in nail samples after *Trichophyton rubrum*, *Trichophyton mentagrophytes*, and *Aspergillus versicolor*.

## Description of cases of invasive fusarioses

During the study period, 10 cases of invasive fusarioses were described (Table 1).

Case	Year	Localisation	Clinical context	Bone marrow transplantation	Fungal identification
1	2007	Blood culture	Acute lymphoid leukemia	Yes	<i>Fusarium</i> sp.
2	2008	Skin	Acute myeloid leukemia secondary to Hodgkin's disease	Yes	<i>Fusarium</i> sp.
3	2009	Skin	Acute myeloid leukemia 0	Yes	<i>Fusarium solani</i>
4	2012	Blood culture Catheter	Hodgkin's disease	Yes	<i>Fusarium oxysporum</i>
5	2012	Sinus	Leukemia with large granular lymphocytes	No	<i>Fusarium</i> sp.
6	2013	Skin	Acute myeloid leukemia secondary	Yes	<i>Fusarium proliferatum</i>
7	2013	Blood culture	Acute myeloid leukemia 5	No	<i>Fusarium solani</i>
8	2013	Blood culture	Chronic myelomonocytic leukemia	Yes	<i>Fusarium solani</i>
9	2014	Sinus	Acute myeloid leukemia 5	Yes	<i>Fusarium</i> sp.
10	2015	Blood culture Skin	Acute myeloid leukemia 4	No	<i>Fusarium solani</i>

**Table 1: Description of the 10 cases of invasive fusariosis**

The diagnosis was made by means of blood cultures (5/10), skin biopsies (4/10) or sinus sampling (2/10). All patients had haematological malignancies, most commonly acute leukemia (7/10), and 70% had bone marrow transplants. *Fusarium solani* is found in 4 cases.

## Species identification among *Fusarium* isolates

279 *Fusarium* isolates were not identified at the species level (39.02%). Among those identified, *Fusarium* belonged to the *F. oxysporum* species complex (32.03%; 229/715) followed by the *F. solani* species complex (20.57%; 147/715). *Gibberella fujikuroi* species complex (GFSC) species complex (4.76%; 34/715), *F. dimerum* species complex (1.82%;



13/715) and *F. chlamyosporum* species complex (1.82%; 13/715) were also found in smaller proportions (Figure 4).

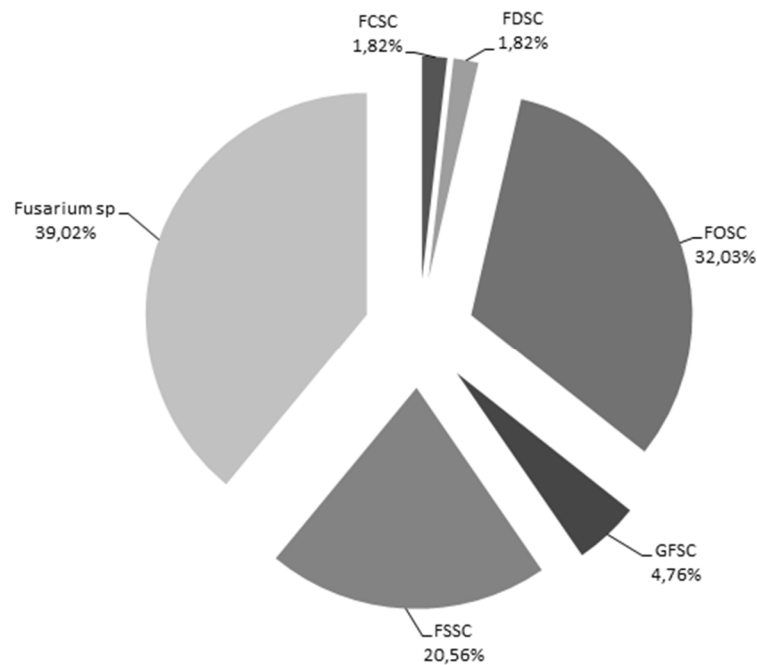


Figure 4: Distribution of species complexes among *Fusarium* isolates.

*Fusarium solani* species complex (FSSC), *Fusarium oxysporum* species complex (FOSC), *Fusarium dimerum* species complex (FDSC), *Gibberella fujikuroi* species complex (GFSC), *Fusarium chlamyosporum* species complex (FCSC)

## DISCUSSION

The evolution of the number of *Fusarium* isolates in the laboratory is stable over the study period but a slight decrease is observed over the most recent period 2015 - 2016. However, this trend appeared to be non-specific for *Fusarium* due to the decrease of the global laboratory activity. The frequency of *Fusarium* isolates was stable in our hospital over the

study period. However, in Brazil, an increased incidence of invasive and superficial fusarioses was recorded between 2000 and 2005 and between 2006 and 2010 [12]. This study was probably carried out after the emergence of fungal infections caused by filamentous fungi, excluding aspergillosis [13].

Concerning the nature of specimens involved in clinical pathology, finger nail and toe nail samples were largely predominant for nearly 90% of samples. As previously described, this is the major site from where *Fusarium* are isolated [5,15,17,18].

Concerning the representativeness of *Fusarium* in nail samples, these molds were found in 8.48% of positive samples without significant changes in this proportion over time. It is difficult to compare this percentage with publications on the subject, as the prevalence of *Fusarium* in onychomycosis is variable throughout the world (0% to over 50%) [16,18,21]. Nevertheless, this number is consistent with one study in 2016 that attributed 10% of onychomycosis to *Fusarium* [21]. In this study, *Fusarium* was the second-most mold involved in onychomycosis after *Aspergillus versicolor*. In a review of different epidemiological studies in several countries, the most common molds are *Scopulariopsis brevicaulis*, *Fusarium* sp., and *Aspergillus* sp. [22]. In our region, we generally isolate one *Fusarium* for two *Trichophyton mentagrophytes*, or four *T. rubrum* in nail samples.

The proportion of *Fusarium* in positive ophthalmic samples averaged at 31.1% during the study period. This number revealed large disparities between the years without being able to formulate hypotheses. The genus *Fusarium* was the most represented fungal etiology in ophthalmology. The level of *Fusarium* involvement in fungal keratitis varied significantly between scientific studies, depending on the geography and the terrain. A review in 2015 of fungal keratitis estimated that *Fusarium* was involved in 70% of traumatic infections, in 67%

of diabetic keratitis, and in 38% of keratitis in recurrent users of topical ophthalmic products [23]. This strong individual influence, coupled with the risk of contamination of lens retention fluids, may explain the inter-year variability of the *Fusarium* ophthalmic-isolation percentage.

The proportion of *Fusarium* in fungi-positive blood cultures was 0.48% and showed no evolution over time. This fungus is rarely responsible for fungemia. In our center, we can expect one *Fusarium* fungemia for 187 *Candida albicans* septicemia, 72 *Candida glabrata*, or three *Cryptococcus* sp. positive blood culture samples. However, fungemia is observed in half of the cases of systemic fusariosis [3]. Note that in our center, blood cultures are performed on Bactec flasks incubated for 5 to 10 days and not with Mycosis flasks.

Ten cases of invasive fusarioses were diagnosed in our center. The documentation was performed *via* blood cultures or skin biopsies. Clinically a disseminated fusariosis is characterized by persistent sepsis despite broad-spectrum antibiotic therapy. Although all localizations may be concerned, cutaneous involvement is predominant (approximately 80% of cases), followed by pulmonary involvement (30% of cases). When observed, the skin manifestations are multiple, sometimes painful and they easily reach the extremities of the limbs. These lesions appear early, which explains why it is frequently the source diagnosis[3,24]. The first description of disseminated fusarioses dates from 1973, in a child with acute leukemia [25]. The majority of these infections occur in patients with hematological disorders and mainly in those who have had hematopoietic stem cell transplantation [24]. More rarely, disseminated fusarioses affects burned patients or transplant ones. A retrospective international study showed that patients with hematological disorders accounted for 60% of cases with invasive fusarioses, 18% of stem cell transplant patients, 12% of patients with chronic immunodeficiency, and the remaining 10% with other situations [11]. In our study, all patients presented with hemopathies, mainly acute leukemias (70 %), and 70% of them had a marrow transplant. *Fusarium solani* is the main species involved

(22%), followed by *Fusarium proliferatum* and *Fusarium moniliforme* (11% each) and *Fusarium oxysporum* (10%) according to an international retrospective study [11]. The potential gateway for invasive mycosis is subject to debate. In our study, case 2 presented an intertrigo of the foot and case 4 a contamination of the catheter, in both case the same fungi is detected in blood culture.

In this study, the two main *Fusarium* complexes identified were FOFC and FSSC. In human pathology, in a study of a population of 717 isolates, the two main complexes found were FSSC and FOFC with 60 and 18% of cases, respectively [26]. In a cohort of 72 invasive fusariosis, FSSC and GFSC were the most represented in equal proportions [11]. Our identification data is fragmented with 39.02% of the isolates identified only at the genus level. In addition, this study was largely represented by nail infections.

In conclusion, the genus *Fusarium* is a fungal agent to consider in clinical practice, particularly due to its invasive nature, the poor prognosis of systemic fusarioses [11], and its significant representativeness in keratitis. Treatment of *Fusarium* in a context of onychomycosis is also important to consider along with treatment of dermatophytes, particularly in immunocompromised as it can be a gateway for invasive fusariosis.

## **Acknowledgments**

We are grateful to the staff members in the Parasitology and Mycology Laboratory Nancy for their participation.

## **Conflict of interest**

None of the authors have any conflict of interest.

## REFERENCES

- [1] Nelson PE, Dignani MC, Anaissie EJ. Taxonomy, biology, and clinical aspects of *Fusarium* species. *Clin Microbiol Rev.* 1994;7:479–504.
- [2] Nucci M, Anaissie E. Emerging fungi. *Infect Dis Clin North Am.* 2006;20:563–579.
- [3] Nucci M, Anaissie E. *Fusarium* infections in immunocompromised patients. *Clin Microbiol Rev.* 2007;20:695–704.
- [4] Sierra-Hoffman M, Paltiyevich-Gibson S, Carpenter JL, Hurley DL. *Fusarium* osteomyelitis: case report and review of the literature. *Scand J Infect Dis.* 2005;37:237–240.
- [5] Nucci F, Nouér SA, Capone D, Anaissie E, Nucci M. Fusariosis. *Semin Respir Crit Care Med.* 2015;36:706–714.
- [6] Kassab O, Charfi M, Trabelsi H, Hammami R, Elloumi M. *Fusarium solani* endocarditis in an acute leukemia patient. *Med Mal Infect.* 2016;46:57–59.
- [7] Su C-C, Hsu H-J, Wu J-J, Chou C-W. Diagnosis of fusariosis in urine cytology. *J Clin Pathol.* 2007;60:422–424.
- [8] Guarro J. Fusariosis, a complex infection caused by a high diversity of fungal species refractory to treatment. *Eur J Clin Microbiol Infect Dis Off Publ Eur Soc Clin Microbiol.* 2013;32:1491–1500.
- [9] Debourgogne A, de Hoog S, Lozniewski A, Machouart M. Amphotericin B and voriconazole susceptibility profiles for the *Fusarium solani* species complex: comparison between the E-test and CLSI M38-A2 microdilution methodology. *Eur J Clin Microbiol Infect Dis Off Publ Eur Soc Clin Microbiol.* 2012;31:615–618.
- [10] Tortorano AM, Richardson M, Roilides E, et al. ESCMID and ECMM joint guidelines on diagnosis and management of hyalohyphomycosis: *Fusarium* spp., *Scedosporium* spp. and others. *Clin Microbiol Infect Off Publ Eur Soc Clin Microbiol Infect Dis.* 2014;20 Suppl 3:27–46.
- [11] Lortholary O, Obenga G, Biswas P, et al. International Retrospective Analysis of 73 Cases of Invasive Fusariosis Treated with Voriconazole. *Antimicrob Agents Chemother.* 2010;54:4446–4450.
- [12] O'Donnell K, Sutton DA, Rinaldi MG, et al. Internet-Accessible DNA Sequence Database for Identifying Fusaria from Human and Animal Infections. *J Clin Microbiol.* 2010;48:3708–3718.
- [13] Nucci M, Varon AG, Garnica M, et al. Increased incidence of invasive fusariosis with cutaneous portal of entry, Brazil. *Emerg Infect Dis.* 2013;19:1567–1572.
- [14] Debourgogne A, Dorin J, Machouart M. Emerging infections due to filamentous fungi in humans and animals: only the tip of the iceberg? *Environ Microbiol Rep.* 2016 ;8:332–342.

- [15] Welsh O, Vera-Cabrera L, Welsh E. Onychomycosis. *Clin Dermatol.* 2010;28:151–159.
- [16] Tosti A, Piraccini BM, Lorenzi S. Onychomycosis caused by nondermatophytic molds: clinical features and response to treatment of 59 cases. *J Am Acad Dermatol.* 2000 ;42:217–24.
- [17] Hwang SM, Suh MK, Ha GY. Onychomycosis due to nondermatophytic molds. *Ann Dermatol.* 2012;24:175–180.
- [18] Moreno G, Arenas R. Other fungi causing onychomycosis. *Clin Dermatol.* 2010;28:160–163.
- [19] Gianni C, Cerri A, Crosti C. Non-dermatophytic onychomycosis. An underestimated entity? A study of 51 cases. *Mycoses.* 2000;43:29–33.
- [20] Gupta AK, Drummond-Main C, Cooper EA, Brintnell W, Piraccini BM, Tosti A. Systematic review of nondermatophyte mold onychomycosis: diagnosis, clinical types, epidemiology, and treatment. *J Am Acad Dermatol.* 2012;66:494–502.
- [21] Gupta C, Jongman M, Das S, et al. Genotyping and In Vitro Antifungal Susceptibility Testing of *Fusarium* Isolates from Onychomycosis in India. *Mycopathologia.* 2016;181:497–504.
- [22] Jossi M, Ambrosioni J, Macedo-Vinas M, Garbino J. Invasive fusariosis with prolonged fungemia in a patient with acute lymphoblastic leukemia: case report and review of the literature. *Int J Infect Dis IJID Off Publ Int Soc Infect Dis.* 2010;14:e354-356.
- [23] Słowik M, Biernat MM, Urbaniak-Kujda D, Kapelko-Słowik K, Misiuk-Hojło M. Mycotic Infections of the Eye. *Adv Clin Exp Med Off Organ Wroclaw Med Univ.* 2015 ;24:1113–1117.
- [24] Dignani MC, Anaissie E. Human fusariosis. *Clin Microbiol Infect.* 2004;10:67–75.
- [25] Cho CT, Vats TS, Lowman JT, Brandsberg JW, Tosh FE. *Fusarium solani* infection during treatment for acute leukemia. *J Pediatr.* 1973;83:1028–1031.
- [26] Short DPG, O'Donnell K, Zhang N, Juba JH, Geiser DM. Widespread occurrence of diverse human pathogenic types of the fungus *Fusarium* detected in plumbing drains. *J Clin Microbiol.* 2011;49:4264–4272.