



HAL
open science

Ultrasound imaging of congestion in heart failure – Examinations beyond the heart

Pierpaolo Pellicori, Elke Platz, Jeroen Dauw, Jozine M ter Maaten, Pieter Martens, Emanuele Pivetta, John Gf Cleland, John J.V. McMurray, Wilfried Mullens, Scott D Solomon, et al.

► **To cite this version:**

Pierpaolo Pellicori, Elke Platz, Jeroen Dauw, Jozine M ter Maaten, Pieter Martens, et al.. Ultrasound imaging of congestion in heart failure – Examinations beyond the heart. *European Journal of Heart Failure*, 2020, 10.1002/ejhf.2032 . hal-03007737

HAL Id: hal-03007737

<https://hal.univ-lorraine.fr/hal-03007737v1>

Submitted on 16 Nov 2020

HAL is a multi-disciplinary open access archive for the deposit and dissemination of scientific research documents, whether they are published or not. The documents may come from teaching and research institutions in France or abroad, or from public or private research centers.

L'archive ouverte pluridisciplinaire **HAL**, est destinée au dépôt et à la diffusion de documents scientifiques de niveau recherche, publiés ou non, émanant des établissements d'enseignement et de recherche français ou étrangers, des laboratoires publics ou privés.

Ultrasound imaging of congestion in heart failure – Examinations beyond the heart

*Pierpaolo Pellicori¹, *Elke Platz², *Jeroen Dauw^{3,4}, Jozine M Ter Maaten^{3,5}, Pieter Martens^{3,4}, Emanuele Pivetta⁶, John GF Cleland¹, John J.V. McMurray⁷, Wilfried Mullens^{3,8}, Scott D. Solomon², Faiez Zannad⁹, **Luna Gargani¹⁰, **Nicolas Girerd⁹

*Equally first author

**Equally last author

Short title: Imaging of congestion

¹ Robertson Institute of Biostatistics and Clinical Trials Unit, University of Glasgow.

² Cardiovascular Division, Brigham and Women's Hospital and Harvard Medical School, Boston, MA, USA.

³ Department of Cardiology, Ziekenhuis Oost-Limburg (ZOL), Genk, Belgium

⁴ Doctoral School for Medicine and Life Sciences, Hasselt University, Diepenbeek, Belgium.

⁵ Department of Cardiology, University Medical Center Groningen, Groningen, the Netherlands

⁶ Division of Emergency Medicine and High Dependency Unit, AOU Città della Salute e della Scienza di Torino, Cancer Epidemiology Unit and CPO Piemonte, Department of Medical Sciences, University of Turin, Turin, Italy.

⁷ BHF Cardiovascular Research Centre, Institute of Cardiovascular and Medical Sciences, University of Glasgow, Glasgow, UK.

⁸ Biomedical Research Institute, Faculty of Medicine and Life Sciences, LCRC, Hasselt University, Diepenbeek, Belgium.

⁹Université de Lorraine, INSERM, Centre d'Investigations Cliniques Plurithématique, INSERM 1433, CHRU de Nancy, Institut Lorrain du Coeur et des Vaisseaux, Nancy, France, and INI-CRCT (Cardiovascular and Renal Clinical Trialists) F-CRIN Network, Nancy, France

¹⁰Institute of Clinical Physiology, National Research Council, Pisa, Italy

Conflict of interest. PM: has received a research grant from Vifor pharma and Fonds Wetenschappelijk Onderzoek (grant number: 1127917N) and consultancy fees from AstraZeneca, Boehringer-Ingelheim, Novartis and Vifor pharma. EPI: has received research grants from NIH and the American Heart Association and her employer has received support from Novartis for consulting work. NG: is funded by a public grant overseen by the French National Research Agency (ANR) as part of the second “Investissements d’Avenir” program FIGHT-HF (reference: ANR-15-RHU-0004) and by the French PIA project “Lorraine Université d’Excellence”, reference ANR-15-IDEX-04-LUE, and received honoraria from Novartis and Boehringer. LG has received research grants from the Italian Ministry of Health and consultancy fees from GE Healthcare and Philips Healthcare. PP has received a research grant (Scotland Grant) from Heart Research UK.

Corresponding author:

Dr. Pierpaolo Pellicori

Robertson Institute of Biostatistics and Clinical Trials Unit

University of Glasgow

University Avenue, Glasgow, G12 8QQ, UK.

Tel: +44 0 141 330 4744; Fax: +44 0 141 330 5094

Email: pierpaolo.pellicori@glasgow.ac.uk

Abstract

Congestion, related to pressures and/or fluid overload, plays a central role in the pathophysiology, presentation and prognosis of heart failure and is an important therapeutic target. While symptoms and physical signs of fluid overload are required to make a clinical diagnosis of heart failure, they lack both sensitivity and specificity, which might lead to diagnostic delay and uncertainty. Over the last decades, new ultrasound methods for the detection of elevated intracardiac pressures and/or fluid overload have been developed that are more sensitive and specific, thereby enabling earlier and more accurate diagnosis and facilitating treatment strategies. Accordingly, we considered that a state-of-the-art review of ultrasound methods for the detection and quantification of congestion was timely, including imaging of the heart, lungs (B-lines), kidneys (intrarenal venous flow), and venous system (inferior vena cava and internal jugular vein diameter).

Key words: Ultrasound, heart failure, B-lines, inferior vena cava, intrarenal venous flow, jugular vein.

Background

Congestion, related to pressure and/or volume overload, is fundamental to the pathophysiology, presentation and prognosis of heart failure (HF) ^{1,2}. Early detection of elevated cardiac or venous pressures is important, as intensification of treatment before signs and symptoms worsen may reduce morbidity in patients with HF ³.

Despite their importance, the clinical identification and quantification of HF signs or symptoms remains challenging even for experienced physicians^{4,5}. Clinical symptoms and signs are late manifestations of congestion and are neither sensitive nor specific for HF. Moreover, no agreement exists on how to grade signs of fluid overload⁶. The measurement of natriuretic peptides, a measure of myocardial wall stretch, is recommended as a diagnostic tool in the assessment of patients with suspected HF and provides important prognostic information¹. However, natriuretic peptide levels are influenced by many factors, including age, body mass index and atrial fibrillation, and natriuretic peptide-guided treatment has not been convincingly shown to improve outcomes in patients with HF⁷. Other costly and invasive tools can monitor pulmonary artery pressure to help guide therapies. However, more evidence is needed on patients' selection and the cost-effectiveness of these devices ^{3,8}. Non-invasive technologies to assess fluid status such as weighing-scales, cardiac bio-impedance, and remote dielectric sensing (ReDS) are being investigated but, apart from weight, have not been widely adopted ^{9,10}.

Ultrasound continues to play a key role in the non-invasive assessment of cardiac structure and function in patients with HF. The aim of this review is to describe ultrasound measurements that move beyond the heart and are associated with either a) elevated venous pressures (inferior vena cava and internal jugular vein diameter and intrarenal venous flow) or

b) extravascular fluid in the lungs (B-lines) that may be useful in the assessment and monitoring of patients with known or suspected HF. In the next paragraphs we will describe how to perform and interpret these techniques (central figure) and briefly summarise the current state of evidence supporting their clinical use.

Cardiac ultrasound (echocardiography)

Transthoracic echocardiography (TTE) plays a central role in the diagnosis and management of patients with HF. TTE is the most available method to measure left ventricular ejection fraction (LVEF), which is used to categorise patients as HF with reduced (HFrEF) or preserved LVEF (HFpEF), a distinction relevant for their management. TTE can also rapidly exclude, or identify, the presence of significant valvular disease, previously undetected congenital problems, and pleural or pericardial effusions. However, many people with breathlessness do not have reduced LVEF or valve disease to account for their symptoms, but left ventricular hypertrophy and impaired long-axis systolic dysfunction by global longitudinal strain are common findings¹¹. The evaluation of mitral inflow, mitral annulus motion by tissue Doppler imaging and left atrial volumes and function provide additional estimates of left ventricular filling pressures¹², but no universal agreement exists on how to combine them to identify individuals at greater risk^{1,13,14}. Pulmonary hypertension, right ventricular dysfunction and greater severity of tricuspid regurgitation all indicate a worse outcome and can be assessed on TTE, but their evaluation might be limited by poor acoustic window or inability to obtain a clear Doppler signal¹⁵. As the comprehensive evaluation of cardiac structure and function in HF goes beyond the scope of this review, the following sections focus on the extracardiac ultrasound methods for the assessment of raised venous pressures and extravascular lung fluid in HF¹⁶.

Inferior vena cava ultrasound

The inferior vena cava (IVC) is a compliant vessel, in anatomical continuation with the right atrium. Any change in right atrial pressure is transmitted backward, and modifies IVC size: a substantial and sustained increase in right atrial pressure, as seen in heart failure, would eventually cause IVC distention. However, studies conducted in patients undergoing cardiac catheterisation have only found modest correlations between right atrial pressure and IVC diameter measured by echocardiography¹⁷; these relations are even weaker in those who are mechanically ventilated (table 1)¹⁸.

How to perform IVC ultrasound

The diameter of the IVC should be measured with a phased array or curvilinear transducer with the patient in supine position in the subcostal view at 1.0 to 2.0 cm from the junction with the right atrium, using the long-axis view¹⁹. For accuracy, this measurement should be made perpendicular to the long axis of the IVC.

How to quantify and interpret IVC ultrasound

Measurement of the IVC diameter and its changes with respiration is possible in most adults. An IVC smaller than 21 mm that collapses >50% suggests normal right atrial pressures¹⁹. IVC diameter might detect increasing intravascular volume even prior to any change in symptoms or body weight in ambulatory HF patients¹⁰, or monitor response to diuretics in hospitalised patients with heart failure²⁰. Persistent IVC engorgement predicts a poor outcome²¹⁻²³. Whether diuretic therapy guided by serial IVC assessments, compared with usual care, might decrease rehospitalisation in patients admitted for HF is currently under evaluation (NCT03140566; NCT02892227). In ambulatory patients with HF who are already on treatment, guidelines do not recommend monitoring cardiac function or ventricular filling

pressures routinely by echocardiography, unless there is substantial clinical deterioration. However, up to half of HF patients with minimal symptoms, and without clinical signs of congestion, have a dilated IVC and other abnormal ultrasonic markers of elevated intracardiac pressures or extravascular lung fluid, which are also associated with elevated NPs and an increase in mortality²⁴.

Internal jugular vein ultrasound

An elevated jugular venous pressure (JVP) is a marker of volume or pressure overload and right ventricular failure, and associated with an increase in mortality in patients with HF²⁵. Clinical evaluation of the JVP is subjective, requires clinical expertise and can be challenging in obese patients. Therefore, identifying and quantifying JV distention is difficult and an elevated JVP may be missed clinically^{26,27}.

How to assess internal jugular vein by ultrasound

The internal jugular vein (IJV) is a superficial and distensible vessel, which lies close to the carotid artery, under the sternocleidomastoid muscle and can be easily visualised with ultrasound. Assessment of IJV should be performed with the patient reclining and head and neck elevated at 45° (semi-recumbent position). Care should be taken to avoid IJV compression during examination. When the patient is supine, the IJV is likely to be distended, but in a sitting position JVP drops and the IJV often collapses. When central venous pressure is low, it may be difficult to visualise the IJV; asking the patient to cough, or to perform a Valsalva manoeuvre, will lead to engorgement, allowing it to be identified on ultrasound.

The IJV can be imaged by placing a high frequency linear transducer (~10 MHz) just below the angle of the jaw, in the area of the sternocleidomastoid muscle, and then moving it inferiorly toward the angle of Louis (or manubriosternal junction). In most cases, the IJV is identified less than 5 cm below the angle of the jaw. Subsequently, the IJV diameter and its changes are measured continuously by M-mode, or in a 2-dimensional frame, at rest and during a Valsalva manoeuvre. The ratio between the maximal diameter during the Valsalva manoeuvre to that at rest (at the end of the expiratory phase) is called the JVD ratio (Figure 1). Measuring the JVD ratio can be done in almost all patients and inter-observer variability is low²⁸. Other authors have proposed measuring the cross-sectional area of the IJV, and how it changes during the Valsalva manoeuvre, to identify patients with elevated right atrial pressure^{29,30}.

How to interpret images of the internal jugular vein

In people without HF, or in patients in whom congestion is adequately controlled, the diameter of the IJV is small at rest (~ 0.10-0.15 cm), but increases several-fold during a Valsalva manoeuvre (usually up to ~ 1 cm)^{28,31}. Because of limited vessel compliance, the maximal IJV diameter that can be achieved during a Valsalva maneuver is similar in people with or without HF. When intra-vascular congestion worsens, it increases the IJV diameter at rest, leading to a reduced JVD ratio. A JVD ratio below 4 is abnormal and, when congestion is severe, the ratio may decrease to <2^{24,28,31}.

In ambulatory HF patients, a low JVD ratio is poorly related to measures of left ventricular size or systolic function, but strongly associated with severe symptoms, elevated NPs, right ventricular dysfunction and tricuspid regurgitation²⁸. A low JVD ratio predicts a worse outcome in terms of HF hospitalisations or deaths, independently of NT-proBNP^{24,27,31}.

When IJV cross-sectional area, rather than its diameter, is used, a large variation during a Valsalva manoeuvre identifies patients more likely to have normal right atrial pressure and better outcomes^{29,30}. Obviously, a Valsalva maneuver depends on the patient's effort and ability to follow instructions. For those who are acutely unwell, or cannot perform a Valsalva maneuver, other techniques, such as passive leg raising, may increase central venous pressure (CVP) but their effects on IJV diameter have not been assessed yet.

Renal venous ultrasound

Worsening renal function in acute HF is common and has been linked to elevated CVP, leading to raised renal interstitial pressures, partial collapse of nephrons, ischemia and neurohormonal activation³². Recently, ultrasound techniques to assess renal blood flow in HF have been described³³⁻³⁶. Although renal arterial flow can be assessed with Doppler ultrasound and predicts HF progression³⁷, an elevated CVP primarily affects renal venous flow (RVF).

How to perform renal venous Doppler ultrasound

Doppler assessment of RVF is performed in the left lateral decubitus position, using a convex or sector transducer (2.5-5 MHz) aligned with the lowest intercostal space rendering a longitudinal view of the right kidney. Using color Doppler imaging with the flow scale adjusted to low-flow velocities (preferably not more than 20 cm/s), the interlobar veins are identified. The best aligned vein is then sampled with pulsed wave Doppler during an end-expiratory breath-hold. The scale should again be adjusted, maximizing the amplitude of the signal (usually around – 20 cm/s) and the ECG signal should be displayed to synchronize the RVF signal with the cardiac cycle.

How to interpret renal venous Doppler

In normal conditions, the interlobar RVF is continuous with a small varying amplitude during the cardiac cycle³⁸. When CVP increases, the variation of amplitude increases with the minimal velocity gradually approaching zero and eventually leading to an early discontinuous flow or ‘pulsatile’ flow³⁹ (Figure 2). If CVP increases further, a biphasic pattern can be recognized with two separate flow phases during a cardiac cycle. In very severe cases, the RVF can become monophasic with a single flow phase in diastole. Analyzing the RVF pattern thus allows a semi-quantitative assessment of the effects of CVP on renal hemodynamics. Other more quantitative measures are the venous impedance index (VII) and the venous discontinuity index (VDI). The VII is the ratio of the difference between maximum and minimum velocity to the maximum velocity during a cardiac cycle with a number varying from 0 (no variation in velocity) to 1 (minimum velocity is zero)³⁸. As CVP increases the variation in RVF amplitude, the VII also increases until flow becomes discontinuous and VII becomes 1. Higher VDI, expressed as the percentage of no-flow time during a cardiac cycle, is another measure of congestion. Of note, other conditions that increase CVP (i.e. obstruction), intra-abdominal pressure (i.e. ascites) or intraparenchymal renal pressure (i.e. obstructive uropathy) can also impair RVF⁴⁰.

Despite its potential, to date, only a few studies have evaluated the role of RVF assessment in HF management. For inpatients with HF (n=217), a monophasic pattern suggests very high right atrial pressures (RAP) and a poor prognosis³³. Another study evaluated the effect of volume loading and diuretics on RVF in 50 patients with stable HFrEF or HFpEF³⁴. After volume loading, the VII increased substantially and the number of patients with discontinuous RVF increased from 32% to 80% without any change in IVC estimated CVP, perhaps

suggesting that RVF is an earlier marker of the development of congestion. Interestingly, patients with a lower VII (indicating less renal congestion) had a better diuretic response.

Lung ultrasound

Lung ultrasound (LUS) can be used for the identification and quantification of extravascular lung fluid in patients with known or suspected HF, at rest or even with exercise^{41,42}. So called ‘B-lines’ are vertical lines that arise from the pleural line and extend to the far-field of the ultrasound screen (Figure 3)⁴³. B-lines are often observed in patients with HF, but can also occur in other conditions, such as non-cardiogenic pulmonary oedema and interstitial lung disease^{44,45}.

How to perform lung ultrasound

Several LUS image acquisition protocols have been described, ranging from 4 to 28 chest regions or “zones”, but the simplified 8-zone protocol is increasingly used both in the clinical setting and for research. During LUS examination, patients are positioned either sitting upright, semi-recumbent or supine. Patients should preferably be imaged in the same position if serial examinations are being performed, as B-line number may be influenced by patient position, with higher B-line counts in supine position⁴⁶. A phased array or curvilinear transducer is placed in an intercostal space in a chest zone either perpendicular (longitudinal, sagittal) or in parallel orientation (transverse) to the ribs at an imaging depth of ~15-18 cm. Once the gain settings are optimised for visualization of the pleural line and any B-lines, a 6 second clip is recorded with the patient breathing normally^{47,48}. Large pleural effusions may interfere with B-lines identification and should be reported, if seen on ultrasound.

How to quantify and interpret B-lines

LUS is more sensitive for the diagnosis of interstitial pulmonary oedema and heart failure than the clinical examination or chest x-ray in patients with acute dyspnea (Figure 3) ^{49,50}. There are several different approaches to quantifying B-lines. Broadly, these can be grouped into two categories: score or count based methods. Score based methods consider a minimum number of B-lines in one intercostal space as a “positive” zone (typically at least 3 B-lines) and then adding up the number of positive zones ^{48,51}. B-lines can be counted either one by one in one chest zone^{52,53} or, when confluent, their number can be estimated from the percentage of space they occupy on the screen below the pleural line, divided by 10 (i.e. if about 70% of the screen below the pleural line is occupied by B-lines, it would conventionally count as 7 B-lines, up to a maximum of 10 per zone)⁵⁴⁻⁵⁷. All these methods have demonstrated good intra- and inter-reader agreement ^{58,59}. In patients with dyspnea presenting to the emergency department, a cut off value of ≥ 3 B-lines in at least two zones per hemithorax (of 6-8 evaluated zones in total) identifies patients with acute HF with higher sensitivity (94-97%) and specificity (96-97%) than the physical examination and chest x-ray (and NT-proBNP) (sensitivity 85%, specificity 89-90%) compared to chart review by two physicians ^{49,51}. A high number of B-lines at the time of discharge from a hospitalisation for acute HF or in ambulatory patients with chronic HF identifies those at high risk of subsequent HF (re-) admissions or death in observational studies ^{24,53-56,60-64}. However, further information on the optimal cut-off values for risk stratification in a variety of clinical settings requires larger prospective studies. Other important methodological aspects of LUS image acquisition and B-line quantification are detailed in a recent consensus document ⁶⁵. A brief overview of a sample of the current evidence on LUS and other described techniques is provided in Table 1.

Future directions

Comprehensive, semi-quantitative, assessment of venous pressures (inferior vena cava and internal jugular vein diameter; intrarenal venous flow) and extravascular lung fluid (B-lines) with ultrasound has several advantages and potential applications in patients with HF. It requires relatively little training and can be rapidly done in about 15 minutes. It uses existing, largely available, technology (ranging from high-end ultrasound systems to pocket size devices), is non-invasive, does not involve radiation and allows for serial, quantifiable, examinations at the point-of-care in a variety of clinical settings. However, many echocardiographic laboratories currently lack the additional transducers needed for JVD ultrasound (linear) and renal ultrasound (curvilinear; Table 1), and sonographers are currently not trained in these new ultrasound techniques.

Currently, the European Society of Cardiology (ESC)-HF guidelines suggest that the IVC diameter can be used to assess volume status in patients with HF, whilst LUS can assist with the detection of extravascular lung fluid (class IIb, level of evidence: C, for both) ¹. In contrast, U.S. HF guidelines do not mention ultrasound as a tool for the evaluation of intra- or extravascular volume status ⁶⁶. While the current level of evidence of the described ultrasound methods varies, the inclusion of LUS for the detection of extravascular lung fluid in patients with undifferentiated dyspnea could be considered in future HF guidelines ^{49,51}.

Further research is needed to gain a better understanding of the clinical utility of these novel ultrasound methods. For instance, more accurate assessment of congestion might optimize timing of discharge for patients hospitalized with HF or help tailor diuretic therapy for ambulatory patients. In addition to physicians, HF nurses and other health care providers can be trained to perform ultrasound examinations such as IVC ultrasound or LUS ⁶⁷. The role of non-physicians in performing point-of-care ultrasound examinations to guide HF management

warrants further investigation. Ultimately, randomized trials are required to demonstrate that treatment guided by sonographic assessment in HF is safe, improves symptoms and quality of life and long-term outcomes. Trials are currently ongoing for LUS in patients during an admission for acute HF (NCT03136198 and NCT03259165), after hospital discharge and in the outpatient clinic; preliminary results are encouraging⁶⁸⁻⁷⁰.

Finally, with the advent of COVID-19 the sonographic assessment of patients with suspected HF who require hospitalization has become more complex. For instance, right ventricular and IVC dilation could be due to right ventricular failure in the setting of acute respiratory distress syndrome or pulmonary embolism associated with a COVID-19 infection⁷¹. As LUS findings in COVID-19 include B-lines, their presence is not specific to pulmonary congestion in undifferentiated patients⁷². However, other LUS findings, such as subpleural consolidations, are not usually seen in HF but can be found in COVID-19 or other pulmonary infections⁷³. Importantly, the absence of B-lines on LUS might rule out substantial pulmonary congestion or involvement in patients in whom HF or COVID-19 are suspected. We will likely gain a better understanding of ultrasound findings in patients with COVID-19 with and without HF over the coming months as data emerge.

Conclusions

Sonographic assessment of the inferior vena cava, internal jugular vein diameter and intrarenal venous flow can facilitate detection of elevated venous pressures, while LUS enables detection and quantification of extravascular lung fluid in patients with HF. These non-invasive techniques could complement clinical skills, traditional diagnostic and monitoring tools and potentially allow for improved diagnosis and management of patients with known or suspected HF.

Acknowledgment:

The authors would like to thank Tristan Gigante (INICRCT, Nancy) for his assistance with the illustrations for this manuscript.

References

1. Ponikowski P, Voors AA, Anker SD, et al. 2016 ESC Guidelines for the diagnosis and treatment of acute and chronic heart failure: The Task Force for the diagnosis and treatment of acute and chronic heart failure of the European Society of Cardiology (ESC). Developed with the special contribution of the Heart Failure Association (HFA) of the ESC. *Eur J Heart Fail.* 2016;18:891-975.
2. Harjola VP, Mullens W, Banaszewski M, et al. Organ dysfunction, injury and failure in acute heart failure: from pathophysiology to diagnosis and management. A review on behalf of the Acute Heart Failure Committee of the Heart Failure Association (HFA) of the European Society of Cardiology (ESC). *Eur J Heart Fail.* 2017;19:821-836.
3. Abraham WT, Adamson PB, Bourge RC, et al. Wireless pulmonary artery haemodynamic monitoring in chronic heart failure: a randomised controlled trial. *Lancet.* 2011;377:658-666.
4. Lok CE, Morgan CD, Ranganathan N. The accuracy and interobserver agreement in detecting the 'gallop sounds' by cardiac auscultation. *Chest.* 1998;114(5):1283-8.
5. Breidhardt T, Moreno-Weidmann Z, Uthoff H, et al. How accurate is clinical assessment of neck veins in the estimation of central venous pressure in acute heart failure? Insights from a prospective study. *Eur J Heart Fail.* 2018;20(7):1160-1162. d
6. Gheorghiade M, Follath F, Ponikowski P, et al. Assessing and grading congestion in acute heart failure: a scientific statement from the acute heart failure committee of the heart failure association of the European Society of Cardiology and endorsed by the European Society of Intensive Care Medicine. *Eur J Heart Fail* 2010;12:423-433.
7. Felker GM, Anstrom KJ, Adams KF, et al. Effect of Natriuretic Peptide-Guided Therapy on Hospitalization or Cardiovascular Mortality in High-Risk Patients With Heart Failure and Reduced Ejection Fraction: A Randomized Clinical Trial. *JAMA.* 2017;318:713-720.
8. Mullens W, Sharif F, Dupont M, Rothman AMK, Wijns W. Digital health care solution for proactive heart failure management with the Cordella Heart Failure System: results of the SIRONA first-in-human study. *Eur J Heart Fail.* 2020 May 31. doi: 10.1002/ejhf.1870. Epub ahead of print. PMID: 32476191.
9. Amir O, Ben-Gal T, Weinstein JM, et al. Evaluation of remote dielectric sensing (ReDS) technology-guided therapy for decreasing heart failure re-hospitalizations. *Int J Cardiol.* 2017 Aug 1;240:279-284.
10. Dovancescu S, Pellicori P, Mabote T, Torabi A, Clark AL, Cleland JGF. The effects of short-term omission of daily medication on the pathophysiology of heart failure. *Eur J Heart Fail.* 2017;19:643-649
11. Pellicori P, Kallvikbacka-Bennett A, Khaleva O, et al. Global longitudinal strain in patients with suspected heart failure and a normal ejection fraction: does it improve diagnosis and risk stratification? *Int J Cardiovasc Imaging.* 2014 Jan;30(1):69-79.
12. Pieske B, Tschope C, de Boer RA, et al. How to diagnose heart failure with preserved ejection fraction: the HFA-PEFF diagnostic algorithm: a consensus recommendation from the Heart Failure Association (HFA) of the European Society of Cardiology (ESC). *Eur Heart J.* 2019;40:3297-3317.
13. Nagueh SF, Smiseth OA, Appleton CP, et al. Recommendations for the Evaluation of Left Ventricular Diastolic Function by Echocardiography: An Update from the American Society of Echocardiography and the European Association of Cardiovascular Imaging. *Eur Heart J Cardiovasc Imaging.* 2016;17:1321-1360.

14. Huttin O, Fraser AG, Coiro S, et al. Impact of Changes in Consensus Diagnostic Recommendations on the Echocardiographic Prevalence of Diastolic Dysfunction. *J Am Coll Cardiol*. 2017 Jun 27;69(25):3119-3121.
15. Damy T, Goode KM, Kallvikbacka-Bennett A, et al. Determinants and prognostic value of pulmonary arterial pressure in patients with chronic heart failure. *Eur Heart J*. 2010;31:2280- 2290. doi:10.1093/eurheartj/ehq245
16. Mitchell C, Rahko PS, Blauwet LA, et al. Guidelines for Performing a Comprehensive Transthoracic Echocardiographic Examination in Adults: Recommendations from the American Society of Echocardiography. *J Am Soc Echocardiogr*. 2019;32:1-64.
17. Kircher BJ, Himelman RB, Schiller NB. Noninvasive estimation of right atrial pressure from the inspiratory collapse of the inferior vena cava. *Am J Cardiol*. 1990;66(4):493-496.
18. Nagueh SF, Kopelen HA, Zoghbi WA. Relation of mean right atrial pressure to echocardiographic and Doppler parameters of right atrial and right ventricular function. *Circulation*. 1996;93:1160-1169.
19. Lang RM, Badano LP, Mor-Avi V, et al. Recommendations for cardiac chamber quantification by echocardiography in adults: an update from the american society of echocardiography and the European association of cardiovascular imaging. *J Am Soc Echocardiogr*. 2015;28:1-39 e14.
20. Laffin LJ, Patel AV, Saha N, et al. Focused cardiac ultrasound as a predictor of readmission in acute decompensated heart failure. *Int J Cardiovasc Imaging*. 2018;34:1075-1079.
21. Goonewardena SN, Gemignani A, Ronan A, et al. Comparison of hand-carried ultrasound assessment of the inferior vena cava and N-terminal pro-brain natriuretic peptide for predicting readmission after hospitalization for acute decompensated heart failure. *JACC Cardiovasc Imaging*. 2008;1:595-601.
22. Cubo-Romano P, Torres-Macho J, Soni NJ, et al. Admission inferior vena cava measurements are associated with mortality after hospitalization for acute decompensated heart failure. *J Hosp Med*. 2016;11:778-784.
23. Pellicori P, Carubelli V, Zhang J, et al. IVC diameter in patients with chronic heart failure: relationships and prognostic significance. *JACC Cardiovascular imaging*. 2013;6:16-28.
24. Pellicori P, Shah P, Cuthbert J, et al. Prevalence, pattern and clinical relevance of ultrasound indices of congestion in outpatients with heart failure. *Eur J Heart Fail*. 2019;21:904-916.
25. Drazner MH, Rame JE, Stevenson LW, Dries DL. Prognostic importance of elevated jugular venous pressure and a third heart sound in patients with heart failure. *N Engl J Med*. 2001;345:574-581.
26. McGee SR. Physical examination of venous pressure: a critical review. *Am Heart J*. 1998;136:10-18.
27. Pellicori P, Clark AL, Kallvikbacka-Bennett A, et al. Non-invasive measurement of right atrial pressure by near-infrared spectroscopy: preliminary experience. A report from the SICA-HF study. *Eur J Heart Fail*. 2017;19:883-892.
28. Pellicori P, Kallvikbacka-Bennett A, Zhang J, et al. Revisiting a classical clinical sign: jugular venous ultrasound. *Int J Cardiol*. 2014;170:364-370.
29. Simon MA, Klinier DE, Girod JP, Moguillansky D, Villanueva FS, Pacella JJ. Detection of elevated right atrial pressure using a simple bedside ultrasound measure. *Am Heart J*. 2010;159:421-427.

30. Simon MA, Schnatz RG, Romeo JD, Pacella JJ. Bedside Ultrasound Assessment of Jugular Venous Compliance as a Potential Point-of-Care Method to Predict Acute Decompensated Heart Failure 30-Day Readmission. *J Am Heart Assoc.* 2018;7:e008184.
31. Pellicori P, Kallvikbacka-Bennett A, Dierckx R, et al. Prognostic significance of ultrasound-assessed jugular vein distensibility in heart failure. *Heart.* 2015;101:1149-1158.
32. Tang WH, Mullens W. Cardiorenal syndrome in decompensated heart failure. *Heart.* 2010;96:255-260.
33. Iida N, Seo Y, Sai S, et al. Clinical Implications of Intrarenal Hemodynamic Evaluation by Doppler Ultrasonography in Heart Failure. *JACC Heart fail.* 2016;4:674-682.
34. Nijst P, Martens P, Dupont M, Tang WHW, Mullens W. Intrarenal Flow Alterations During Transition From Euvolemia to Intravascular Volume Expansion in Heart Failure Patients. *JACC Heart fail.* 2017;5:672-681.
35. Puzzovivo A, Monitillo F, Guida P, et al. Renal Venous Pattern: A New Parameter for Predicting Prognosis in Heart Failure Outpatients. *Cardiovasc Dev Dis.* 2018;5(4).
36. de la Espriella-Juan R, Nunez E, Minana G, et al. Intrarenal venous flow in cardiorenal syndrome: a shining light into the darkness. *ESC heart failure.* 2018;5:1173-1175.
37. Ciccone MM, Iacoviello M, Gesualdo L, et al. The renal arterial resistance index: a marker of renal function with an independent and incremental role in predicting heart failure progression. *Eur J Heart Fail.* 2014;16:210-216.
38. Jeong SH, Jung DC, Kim SH, Kim SH. Renal venous doppler ultrasonography in normal subjects and patients with diabetic nephropathy: value of venous impedance index measurements. *J Clin Ultrasound.* 2011;39:512-518.
39. Tang WH, Kitai T. Intrarenal Venous Flow: A Window Into the Congestive Kidney Failure Phenotype of Heart Failure? *JACC Heart fail.* 2016;4:683-686.
40. Bateman GA, Cuganesan R. Renal vein Doppler sonography of obstructive uropathy. *AJR Am J Roentgenol.* 2002;178:921-925.
41. Scali MC, Cortigiani L, Simionuc A, Gregori D, Marzilli M, Picano E. Exercise-induced B-lines identify worse functional and prognostic stage in heart failure patients with depressed left ventricular ejection fraction. *Eur J Heart Fail.* 2017 Nov;19(11):1468-1478.
42. Simonovic D, Coiro S, Carluccio E, et al. Exercise elicits dynamic changes in extravascular lung water and haemodynamic congestion in heart failure patients with preserved ejection fraction. *Eur J Heart Fail.* 2018 Sep;20(9):1366-1369.
43. Volpicelli G, Elbarbary M, Blaivas M, et al. International evidence-based recommendations for point-of-care lung ultrasound. *Intensive Care Med.* 2012;38:577-591.
44. Copetti R, Soldati G, Copetti P. Chest sonography: a useful tool to differentiate acute cardiogenic pulmonary edema from acute respiratory distress syndrome. *Cardiovasc ultrasound.* 2008;6:16.
45. Wang Y, Gargani L, Barskova T, Furst DE, Cerinic MM. Usefulness of lung ultrasound B-lines in connective tissue disease-associated interstitial lung disease: a literature review. *Arthritis Res Ther.* 2017;19:206.
46. Frasure SE, Matilsky DK, Siadecki SD, Platz E, Saul T, Lewiss RE. Impact of patient positioning on lung ultrasound findings in acute heart failure. *Eur Heart J Acute Cardiovasc Care.* 2015;4:326-332.
47. Platz E, Pivetta E, Merz AA, Peck J, Rivero J, Cheng S. Impact of device selection and clip duration on lung ultrasound assessment in patients with heart failure. *Am J Emerg Med.* 2015;33:1552-1556.
48. Pivetta E, Baldassa F, Masellis S, Bovaro F, Lupia E, Maule MM. Sources of Variability in the Detection of B-Lines, Using Lung Ultrasound. *Ultrasound Med Biol.* 2018;44:1212-1216.

49. Pivetta E, Goffi A, Nazerian P, et al. Lung ultrasound integrated with clinical assessment for the diagnosis of acute decompensated heart failure in the emergency department: a randomized controlled trial. *Eur J Heart Fail.* 2019;21:754-766.
50. Buessler A, Chouihed T, Duarte K, et al. Accuracy of Several Lung Ultrasound Methods for the Diagnosis of Acute Heart Failure in the ED: A Multicenter Prospective Study. *Chest.* 2020;157:99-110.
51. Pivetta E, Goffi A, Lupia E, et al. Lung Ultrasound-Implemented Diagnosis of Acute Decompensated Heart Failure in the ED: A SIMEU Multicenter Study. *Chest.* 2015;148:202-210.
52. Platz E, Campbell RT, Claggett B, et al. Lung Ultrasound in Acute Heart Failure: Prevalence of Pulmonary Congestion and Short- and Long-Term Outcomes. *JACC Heart fail.* 2019;7:849-858.
53. Platz E, Lewis EF, Uno H, et al. Detection and prognostic value of pulmonary congestion by lung ultrasound in ambulatory heart failure patients. *Eur Heart J.* 2016;37:1244-1251.
54. Coiro S, Porot G, Rossignol P, et al. Prognostic value of pulmonary congestion assessed by lung ultrasound imaging during heart failure hospitalisation: A two-centre cohort study. *Sci rep.* 2016;6:39426.
55. Coiro S, Rossignol P, Ambrosio G, et al. Prognostic value of residual pulmonary congestion at discharge assessed by lung ultrasound imaging in heart failure. *Eur J Heart Fail.* 2015;17:1172-1181.
56. Gargani L, Pang PS, Frassi F, et al. Persistent pulmonary congestion before discharge predicts rehospitalization in heart failure: a lung ultrasound study. *Cardiovasc Ultrasound.* 2015;13:40.
57. Gargani L. Ultrasound of the Lungs: More than a Room with a View. *Heart fail clin.* 2019;15:297-303.
58. Jambrik Z, Monti S, Coppola V, et al. Usefulness of ultrasound lung comets as a nonradiologic sign of extravascular lung water. *Am J Cardiol.* 2004;93:1265-1270.
59. Gargani L, Sicari R, Raciti M, et al. Efficacy of a remote web-based lung ultrasound training for nephrologists and cardiologists: a LUST trial sub-project. *Nephrol Dial Transplant.* 2016;31:1982-1988.
60. Dwyer KH, Merz AA, Lewis EF, et al. Pulmonary Congestion by Lung Ultrasound in Ambulatory Patients With Heart Failure With Reduced or Preserved Ejection Fraction and Hypertension. *J Card Fail.* 2018;24:219-226.
61. Palazzuoli A, Ruocco G, Beltrami M, Nuti R, Cleland JG. Combined use of lung ultrasound, B-type natriuretic peptide, and echocardiography for outcome prediction in patients with acute HFrEF and HFpEF. *Clin Res Cardiol.* 2018;107:586-596.
62. Platz E, Merz AA, Jhund PS, Vazir A, Campbell R, McMurray JJ. Dynamic changes and prognostic value of pulmonary congestion by lung ultrasound in acute and chronic heart failure: a systematic review. *Eur J Heart Fail.* 2017;19:1154-1163.
63. Miglioranza MH, Picano E, Badano LP, et al. Pulmonary congestion evaluated by lung ultrasound predicts decompensation in heart failure outpatients. *Int J Cardiol.* 2017;240:271-278.
64. Cogliati C, Casazza G, Ceriani E, et al. Lung ultrasound and short-term prognosis in heart failure patients. *Int J Cardiol.* 2016;218:104-108.
65. Platz E, Jhund PS, Girerd N, et al. Expert consensus document: Reporting checklist for quantification of pulmonary congestion by lung ultrasound in heart failure. *Eur J Heart Fail.* 2019;21:844-851.
66. Yancy CW, Jessup M, Bozkurt B, et al. 2017 ACC/AHA/HFSA Focused Update of the 2013 ACCF/AHA Guideline for the Management of Heart Failure: A Report of the

- American College of Cardiology/American Heart Association Task Force on Clinical Practice Guidelines and the Heart Failure Society of America. *Circulation*. 2017;136:e137-e161.
67. Gundersen GH, Norekval TM, Haug HH, et al. Adding point of care ultrasound to assess volume status in heart failure patients in a nurse-led outpatient clinic. A randomised study. *Heart*. 2016;102:29-34.
68. Rivas-Lasarte M, Alvarez-Garcia J, Fernandez-Martinez J, et al. Lung ultrasound-guided treatment in ambulatory patients with heart failure: a randomized controlled clinical trial (LUS-HF study). *Eur J Heart Fail*. 2019;21:1605-1613.
69. Marini C, Fragasso G, Italia L, et al. Lung ultrasound-guided therapy reduces acute decompensation events in chronic heart failure. *Heart*. 2020 Jun 22;heartjnl-2019-316429. doi: 10.1136/heartjnl-2019-316429. Epub ahead of print. PMID: 32571960.
70. Araiza-Garaygordobil D, Gopar-Nieto R, Martinez-Amezcuca P, et al. A randomized controlled trial of lung ultrasound-guided therapy in heart failure (CLUSTER-HF study). *Am Heart J*. 2020 Sep;227:31-39.
71. Bikdeli B, Madhavan MV, Jimenez D, et al. COVID-19 and Thrombotic or Thromboembolic Disease: Implications for Prevention, Antithrombotic Therapy, and Follow-up. *J Am Coll Cardiol*. 2020;S0735-1097(20)35008-7.
72. Lomoro P, Verde F, Zerboni F, et al. COVID-19 pneumonia manifestations at the admission on chest ultrasound, radiographs, and CT: single-center study and comprehensive radiologic literature review. *Eur J Radiol Open*. 2020;7:100231.
73. Gargani L, Aboumarie HS, Volpicelli G, Corradi F, Pastore MC, Cameli M. Why when and how to use lung ultrasound during the COVID-19 pandemic: enthusiasm and caution. *Eur Heart J Cardiovasc Imaging* 2020. In press
74. Magnino C, Omedè P, Avenatti E, et al.; RIGHT1 Investigators. Inaccuracy of Right Atrial Pressure Estimates Through Inferior Vena Cava Indices. *Am J Cardiol*. 2017;120:1667-1673.
75. Lee SL, Daimon M, Kawata T, et al. Estimation of right atrial pressure on inferior vena cava ultrasound in Asian patients. *Circ J*. 2014;78:962-6.
76. Agricola E, Bove T, Oppizzi M, et al. "Ultrasound comet-tail images": a marker of pulmonary edema: a comparative study with wedge pressure and extravascular lung water. *Chest*. 2005;127:1690-5
77. Hubert A, Girerd N, Le Breton H, et al. Diagnostic accuracy of lung ultrasound for identification of elevated left ventricular filling pressure. *Int J Cardiol*. 2019;281:62-68.
78. Miglioranza MH, Gargani L, Sant'Anna RT, et al. Lung ultrasound for the evaluation of pulmonary congestion in outpatients: a comparison with clinical assessment, natriuretic peptides, and echocardiography. *JACC Cardiovasc Imaging*. 2013;6:1141-51.
79. Anderson KL, Jenq KY, Fields JM, Panebianco NL, Dean AJ. Diagnosing heart failure among acutely dyspneic patients with cardiac, inferior vena cava, and lung ultrasonography. *Am J Emerg Med*. 2013;31:1208-14.
80. Gargani L, Frassi F, Soldati G, Tesorio P, Gheorghide M, Picano E. Ultrasound lung comets for the differential diagnosis of acute cardiogenic dyspnoea: a comparison with natriuretic peptides. *Eur J Heart Fail*. 2008;10:70-7.
81. Öhman J, Harjola VP, Karjalainen P, Lassus J. Focused echocardiography and lung ultrasound protocol for guiding treatment in acute heart failure. *ESC Heart Fail*. 2018;5:120-128.
82. Pellicori P, Cleland JG, Zhang J, et al. Cardiac Dysfunction, Congestion and Loop Diuretics: their Relationship to Prognosis in Heart Failure. *Cardiovasc Drugs Ther*. 2016;30:599-609.
83. Lee HF, Hsu LA, Chang CJ, et al. Prognostic significance of dilated inferior vena cava in advanced decompensated heart failure. *Int J Cardiovasc Imaging*. 2014;30:1289-95.

84. Curbelo J, Aguilera M, Rodriguez-Cortes P, Gil-Martinez P, Suarez Fernandez C. Usefulness of inferior vena cava ultrasonography in outpatients with chronic heart failure. *Clin Cardiol.* 2018;41:510-517.
85. Palazzuoli A, Ruocco G, Franci B, Evangelista I, Lucani B, Nuti R, Pellicori P. Ultrasound indices of congestion in patients with acute heart failure according to body mass index. *Clin Res Cardiol.* 2020 Apr 15. doi: 10.1007/s00392-020-01642-9. Online ahead of print.

	Inferior vena cava	JVD ratio	Venous Renal Doppler	Lung ultrasound (B-lines)
Ultrasound transducer	Phased array or curvilinear	Linear	Curvilinear	Phased array or curvilinear
Correlation with invasive cardiac hemodynamics	Moderate ^(17,18, 74-76)	No data	Moderate ⁽³³⁾	Moderate ^(77,78)
Correlation with natriuretic peptides	Low to moderate ^(23,24)	Low to moderate ^(24,28,31)	Moderate ⁽³³⁾	Moderate to good ^(24, 54,78)
Diagnostic value*	Little evidence ⁽⁷⁹⁾	Not enough evidence	Not enough evidence	Yes ^(49,51,79,80)
Monitoring	Yes ^(10,20-22)	No data	Yes ⁽³⁴⁾	Yes ^(56,81)
Prognostic value	Yes ^{(20-24, 82-85).}	Yes ^(24,27,31)	Yes ^(33,35)	Yes ^(24, 53-56, 60-64)
Intra-reader agreement [mean difference, 95% limits of agreement]	--	0.42 (-1.26, 2.11) ⁽²⁸⁾	Reproducibility ⁽³⁴⁾ Venous impedance index: 4±13%	Count method: 0.05 B-lines/8 zones (-1.3, 1.4) ⁽⁴⁵⁾
Inter-reader agreement [mean difference, 95% limits of agreement]	-0.04 mm (-2.48, 2.40) ⁽²³⁾	-0.22 (-1.24, 0.80) ⁽²⁸⁾	Reproducibility ⁽³⁴⁾ Venous impedance index: 5±12%	Count method: -0.3 B-lines/8 zones (-1.9,1.3) ⁽⁵³⁾ Count-percentage method: 0.03 B-lines/zone (-1.52,1.45) ⁽⁵⁹⁾ Score method: Cohen's Kappa 0.70-0.81/zone ⁽⁴⁸⁾
Limitations	Body habitus/obesity, Mechanical ventilation, Inability to perform a deep inspiration.	Inability to perform Valsalva, It varies with patient's position	Obesity, Severe breathlessness	Some diseases may increase B-lines (e.g. interstitial lung disease, <i>acute respiratory distress syndrome</i>), or limit their visualization (pneumothorax, large pleural effusion, morbid obesity).

Table 1. Novel sonographic methods that quantify congestion in patients with heart failure: evidences and limitations. *For acute heart failure

Figure Legends

Central illustration: Ultrasound framework for the comprehensive evaluation of cardiac and venous pressure, and extravascular lung fluid

Figure 1. Jugular Vein Diameter (JVD) Ultrasound. With the patient reclining and head and neck elevated at 45°, the internal jugular vein is identified and its diameter (JVD) is measured at rest (at the end of expiratory phase, figure on the left) and during a Valsalva manoeuvre (figure on right). The ratio between the maximum diameter during Valsalva to that at rest is the JVD ratio. In the panel on the right, different examples of JVD patterns at rest and during Valsalva are shown, in patients without congestion (normal JVD ratio: >4 ; on the top) and in those with increasing congestion (mid and bottom).

Figure 2. Renal Venous Doppler. Once one of the interlobar veins has been identified, its venous flow can be assessed with pulsed Doppler. Four distinct venous flow patterns can be recognised (normal continuous, discontinuous pulsatile, discontinuous biphasic and discontinuous monophasic), according to increasing renal congestion (top to bottom). The bottom panel illustrates two proposed methods for renal flow quantification (venous impedance index and venous discontinuity index).

Figure 3. Lung Ultrasound. In the top left panel, the 8 (left) and 28 (right) chest zones methods are shown. **Count method:** B-lines are counted in each zone and summed to obtain their total count. B-lines can be counted individually as seen (bottom left panel, figure on the left). Alternatively, when confluent, their number can be estimated from the percentage of space they occupy on the screen below the pleural line, divided by 10 (bottom left panel,

figure on the right, in which confluent B-lines occupy about 60% of the screen below the pleural line: conventionally, this equates to 6 B-lines). **Score method:** ≥ 3 B-lines in one intercostal space per zone is considered a “positive” zone (bottom left panel, figure on the right). Different B-lines patterns are shown in the panel on the right: a normal lung should appear “dark” on lung ultrasound below the pleural line (top), but as pulmonary congestion develops and increases, more B-lines are seen.

Central Figure

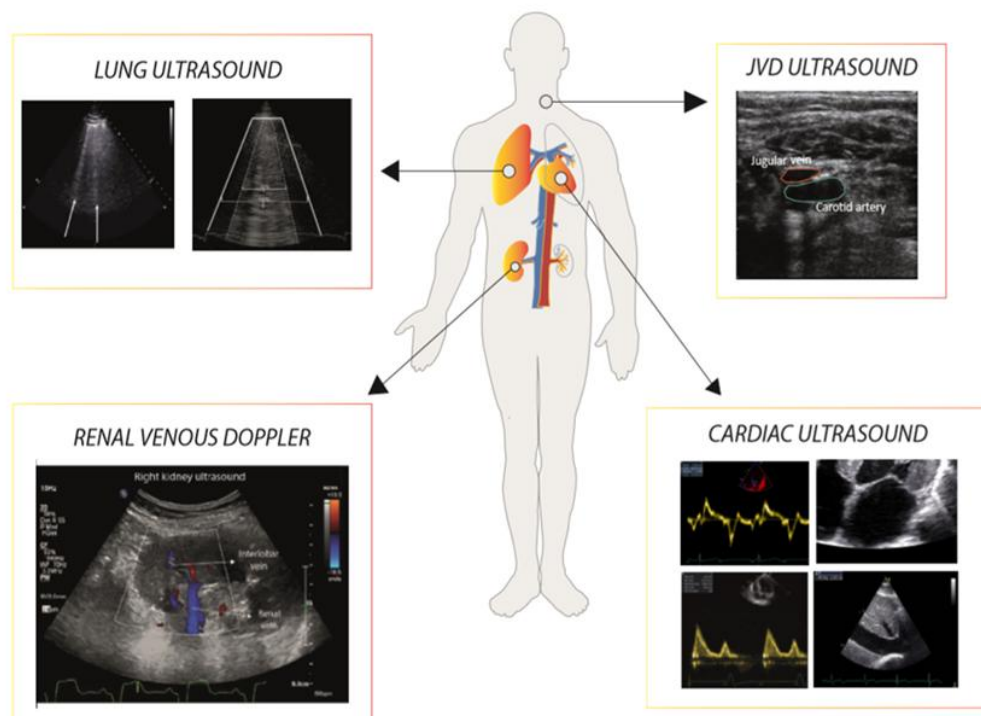


Figure 1

JVD ULTRASOUND

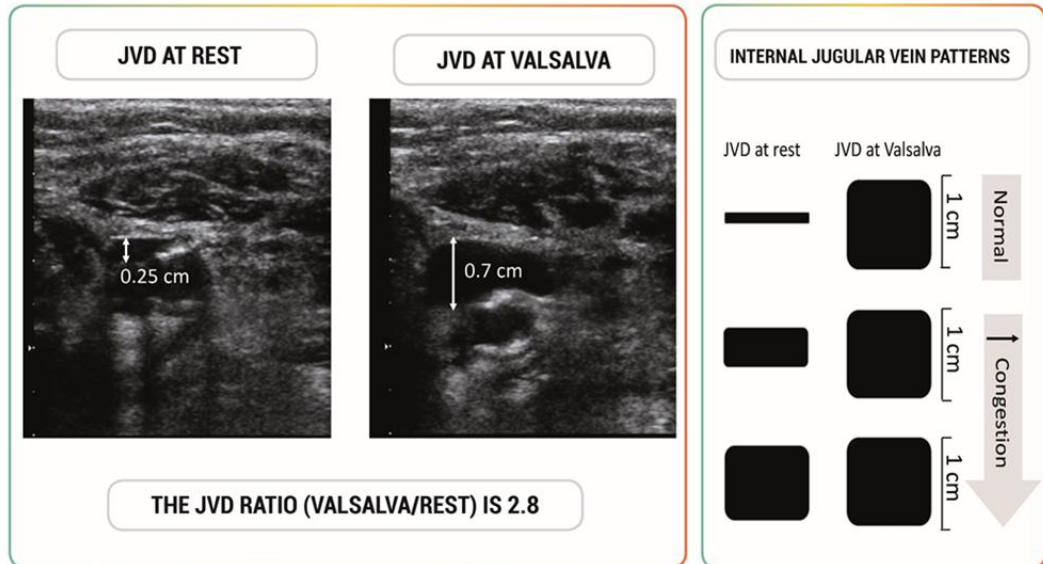
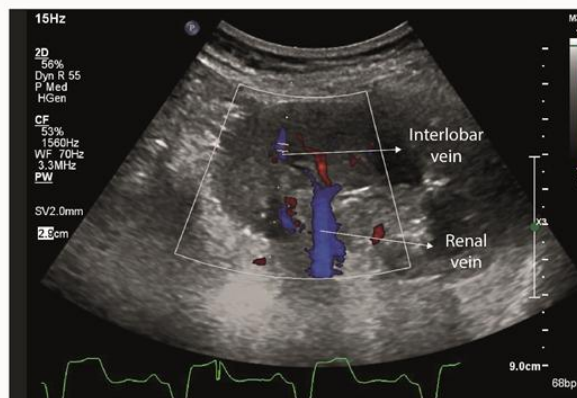
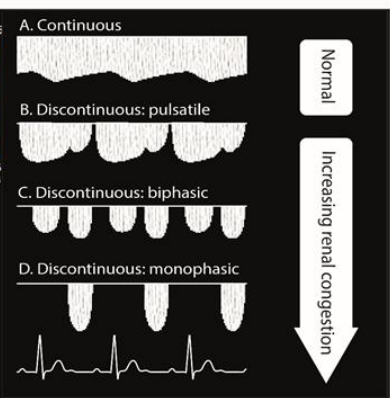


Figure 2

RENAL VENOUS DOPPLER



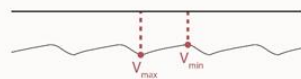
RENAL VENOUS FLOW PATTERNS



QUANTIFICATION

CONTINUOUS FLOW

$$\text{Venous impedance index (VII)} = \frac{V_{\max} - V_{\min}}{V_{\max}}$$



DISCONTINUOUS FLOW

$$\text{Venous discontinuity index (VDI)} = \frac{\text{Time}_{\text{cycle}} - \text{Time}_{\text{flow}}}{\text{Time}_{\text{cycle}}}$$

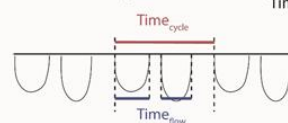
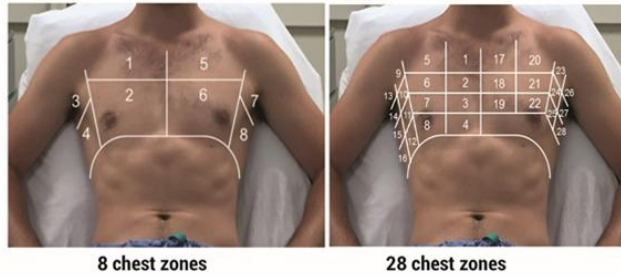


Figure 3

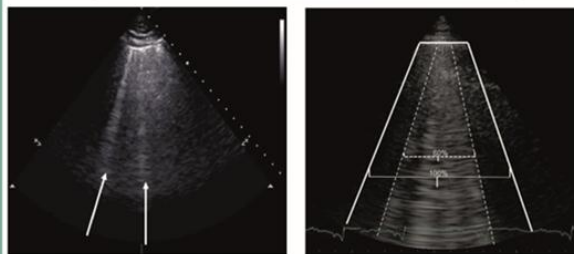
LUNG ULTRASOUND



8 chest zones

28 chest zones

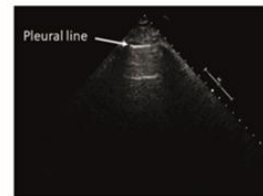
Quantification



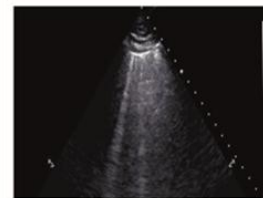
Individual Count

Percentage

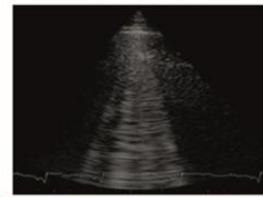
B-LINES PATTERNS



Normal



↑ Congestion



↓