

Evolution of the activity of the masticatory muscles before and after temporomandibular joint replacement: a clinical and functional study

Emilie Sapin - de Brosse, A.-S Bonnet, N. Zwetyenga

► **To cite this version:**

Emilie Sapin - de Brosse, A.-S Bonnet, N. Zwetyenga. Evolution of the activity of the masticatory muscles before and after temporomandibular joint replacement: a clinical and functional study. *Computer Methods in Biomechanics and Biomedical Engineering*, Taylor & Francis, 2019, 22 (sup1), pp.S87-S89. 10.1080/10255842.2020.1713491 . hal-03181936

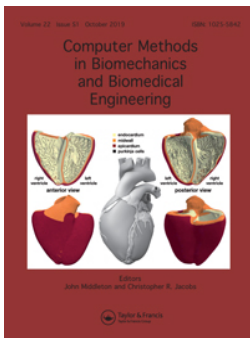HAL Id: hal-03181936

<https://hal.univ-lorraine.fr/hal-03181936>

Submitted on 26 Mar 2021

HAL is a multi-disciplinary open access archive for the deposit and dissemination of scientific research documents, whether they are published or not. The documents may come from teaching and research institutions in France or abroad, or from public or private research centers.

L'archive ouverte pluridisciplinaire **HAL**, est destinée au dépôt et à la diffusion de documents scientifiques de niveau recherche, publiés ou non, émanant des établissements d'enseignement et de recherche français ou étrangers, des laboratoires publics ou privés.



Computer Methods in Biomechanics and Biomedical Engineering

ISSN: (Print) (Online) Journal homepage: <https://www.tandfonline.com/loi/gcmb20>

Evolution of the activity of the masticatory muscles before and after temporomandibular joint replacement: a clinical and functional study

E. Sapin-de Brosses , A.-S Bonnet & N. Zwetyenga

To cite this article: E. Sapin-de Brosses , A.-S Bonnet & N. Zwetyenga (2019) Evolution of the activity of the masticatory muscles before and after temporomandibular joint replacement: a clinical and functional study, Computer Methods in Biomechanics and Biomedical Engineering, 22:sup1, S87-S89, DOI: [10.1080/10255842.2020.1713491](https://doi.org/10.1080/10255842.2020.1713491)

To link to this article: <https://doi.org/10.1080/10255842.2020.1713491>



© 2020 The Author(s). Published by Informa UK Limited, trading as Taylor & Francis Group



Published online: 22 May 2020.



Submit your article to this journal [↗](#)



Article views: 94



View related articles [↗](#)



View Crossmark data [↗](#)



Citing articles: 1 View citing articles [↗](#)

Evolution of the activity of the masticatory muscles before and after temporomandibular joint replacement: a clinical and functional study

E. Sapin-de Brosse^a, A.-S. Bonnet^a and N. Zwetyenga^b

^aUniversité de Lorraine, CNRS, Metz, France; ^bService de Chirurgie maxillofaciale, plastique reconstructrice et esthétique, CHU de Dijon-Bourgogne, Dijon, France

1. Introduction

Temporomandibular joint replacement (TMJR) is the last resort in the management of end-stage TMJ disorders or diseases. There is a clear consensus about the indications for TMJR and a recent increase of the studies concerning the clinical outcomes (Johnson et al. 2017). The functional recovering, after the surgery, is usually assessed by the maximal incisal opening, but few studies have investigated other functional aspects (Wojczynska et al. 2019). Our goal is to analyse the 3D kinematic analysis of the mandible combined with electromyography (EMG) of the masticatory muscles to study the functional abilities before and after total TMJR. This paper focuses on the evolution of the muscular activities before and after the surgery, for two patients followed during one year and compared with an asymptomatic group.

2. Methods

The protocol was validated by an ethical committee and all the subjects gave their consent to participate.

2.1. Patients

Two 62-years-old women (patient P1 and P2) underwent a TMJR on the right side. They participated in five kinematic and EMG measurements, one before and four after the surgery up to 12 months of follow-up. They filled at each step a quality-of-life (QoL) questionnaire rating eight items: pain, diet, conversation, activities of daily life, mood, anxiety, QoL linked to the health, and the general QoL.

2.2. Reference asymptomatic group

The reference group encompassed nine asymptomatic women (44 ± 9 years old). Inclusion criteria were a type I dental occlusion, and the absence of previous TMJ disorders, clicking joint, cephalalgia and tinnitus.

2.3. Electromyographic study

After warming exercises, the subjects were asked to rest, then to bite on dental cotton at their maximum, and finally to turn their head at the maximal axial rotation. The EMG activity of the left and right anterior temporalis (T), masseters (M) and sternocleidomastoid muscles (SCM) was recorded during each exercise and post-treated following the protocol described by Owashi Vallejo et al. (2017). Briefly, raw signals were high-pass filtered (with an additional filter for the SCM muscles to reduce ECG artefacts), rectified and smoothed. The rest-activity and the maximal voluntary contraction (MVC) were computed as the RMS values on a 10 s interval and 3 s interval respectively. To assess the fatigue appearing during a long-time hold maximal contraction, the mean power frequencies (MPF) were estimated using Welch's method. Each exercise was repeated three times and averaged values were then computed. Specific attention was paid to ensure the repeated positioning of the electrodes.

3. Results and discussion

3.1. Asymptomatic behaviour

During the rest, the EMG activity was low ($< 4.5 \mu\text{V}$) and reproducible (standard deviation $< 1 \mu\text{V}$) for all the muscles. During the maximal bite, the MVC ranged between $128 \mu\text{V}$ and $450 \mu\text{V}$ for the T muscles and between $65 \mu\text{V}$ and $395 \mu\text{V}$ for the M muscles. On average, the MVC of the T muscles was higher than for the M (MVC Right T = $277 \pm 38 \mu\text{V}$, MVC Left T = $285 \pm 113 \mu\text{V}$, MVC Right M = $212 \pm 97 \mu\text{V}$, MVC Left M = $231 \pm 86 \mu\text{V}$). Seven subjects underwent a fatigue process, assessed as the decrease of the MPF higher than 3 Hz for at least two T and M muscles. The SCM muscles were systematically activated during maximal bite to sustain the mandible.

For the maximal axial rotation of the head, the MVC of the SCM muscles ranged between 25 and $243 \mu\text{V}$ (averaged values: MVC Right SCM = $89 \pm 50 \mu\text{V}$, MVC

Left SCM = $112 \pm 79 \mu\text{V}$), showing a large dispersion between the subjects. The ipsilateral muscle was systematically activated while turning the head in a side to control the movement. Then, its activity decreased when the head achieved the axial maximal rotation (period of MVC of the contralateral SCM).

3.2. Clinical outcomes and QoL for the patients

Before the surgery, the pain was extreme for the two patients, rated as a “not controlled pain”. The QoL score was rated as “poor” and the score combining the entire item was moderate (Table 1). After the surgery, the two patients did not suffer at the joints. Patient P2 suffered from cephalalgia and neck pain during the whole period. The QoL regularly increased during the follow-up for both patients, showed by a decrease in the scores. The 6-months follow-up is missing for P2.

3.3. Evolution of the EMG activities for the patients

Before the surgery, the EMG activities during the rest were higher than the asymptomatic values for all the

Table 1. Patients' rating of pain and Quality of Life (QoL) before and after the surgery.

| | TMJ pain* | Head & neck pain* | QoL score ◆ | Global score ● |
|-----------------------|-----------|-------------------|-------------|----------------|
| Before P1 / P2 | 4 / 4 | 4 / 4 | 3 / 3 | 15 / 20 |
| 1 month after P1/P2 | 0 / 0 | 0 / 4 | 2 / 3 | 10 / 14 |
| 3 months after P1/P2 | 0 / 0 | 0 / 4 | 2 / 2 | 7 / 12 |
| 6 months after P1/P2 | 0 / - | 0 / - | 0 / - | 0 / - |
| 12 months after P1/P2 | 0 / 0 | 0 / 4 | 0 / 2 | 0 / 9 |

*: pain rated from 0: “no pain” to 4: “not controlled pain”.

◆ QoL rated from 0: “extremely good” to 4: “very poor”.

●: Global score rated from 0 to 30. The smallest the score, the highest the QoL linked to the entire items.

muscles. This is probably due to the stress generated by extreme pain. By considering the suffering (right) side, the rest-activities were higher, and the MVC activities smaller, than for the contralateral side. The MVC values during biting were significantly smaller than for the asymptomatic women, and fatigue was not observed. This may be due to a voluntary limitation by fear to suffer. Contrary to the asymptomatic pattern, the SCM muscles did not activate during the bite.

One month after the surgery, the rest-activities tended to decrease. The MVC activities of the Right T increased (Figure 1). The Right M and the Right SCM were not active, which could be explained by edema, present from the ear to the neck. The MVC activities tended to increase for the other muscles. The SCM muscles contracted during the bite.

Three months after the surgery, the MVC activities increased for all the muscles but the dispersion was high. The variability of the muscular activities started to decrease for all the muscles from six months of follow-up.

One year after the surgery, for patient P1, the muscular activities during rest were similar to the asymptomatic ones. The MVC activities increased or stabilized. The values were in the asymptomatic range for the SCM muscles but much smaller than the asymptomatic values for the T and M muscles. Patient P2 decreased significantly the MVC activities for the T and M muscles between three months and twelve months of follow-up. It was clearly observed that the patient did not want to hardly bite on the cotton. Discussions revealed difficulties linked to a lack of intraoral feeling as well as the stress of suffering. All the MVC activities were smaller than the asymptomatic values.

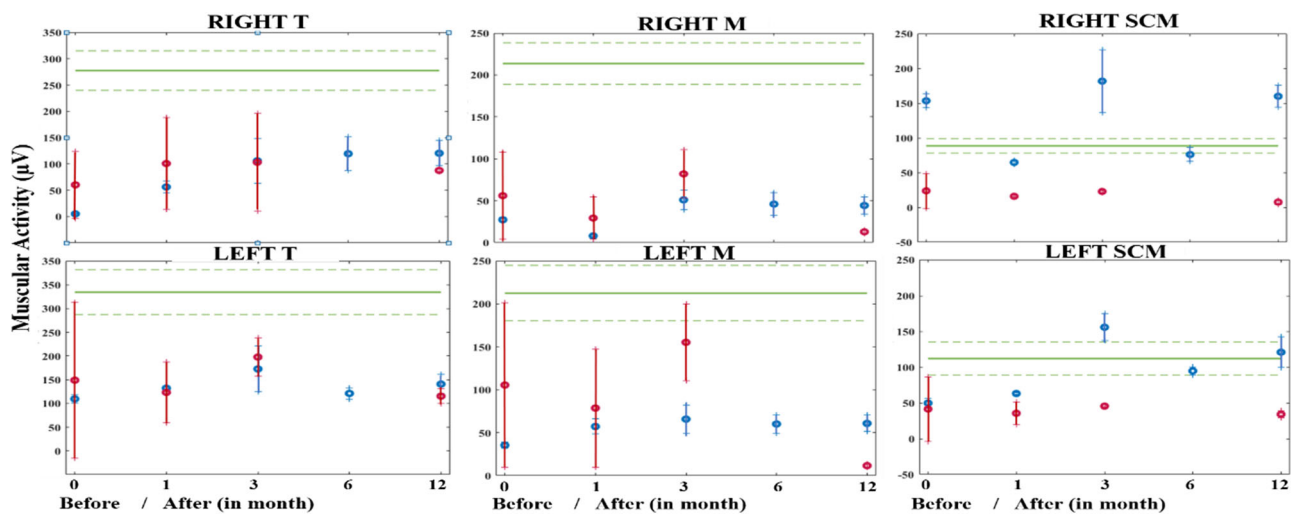


Figure 1. Maximal voluntary contractions before and after total TMJ replacement. In green: asymptomatic range (mean \pm 1 standard deviation), in blue: patient P1, in red: patient P2.

4. Conclusions

Our study showed the functional recovering after total alloplastic TMJR through the analysis of the EMG activity of the masticatory muscles. The observed increase of the MVC with the time of follow-up was consistent with the subjective rating of the daily life abilities. One year after the surgery, the muscular activities remained however much smaller than the asymptomatic values for the T and M muscles.

References

Johnson NR, Roberts MJ, Doi SA, Batstone MD. 2017. Total temporomandibular joint replacement prostheses: a

systematic review and bias-adjusted meta-analysis. *Int J Oral Maxillofac Surg.* 46(1):86–92.

Owashi Vallejo KP, Sapin – de Brosse E, Bonnet A-S. 2017. Electromyography of the masticatory muscles during biting. *Comput Methods Biomech Biomed Eng.* 20(sup1):155–156.

Wojczynska A, Gallo LM, Bredell M, Leiggner CS. 2019. Alterations of mandibular movement patterns after total joint replacement: a case series of long-term outcomes in patient with total alloplastic temporomandibular joint reconstructions. *Int J Oral Maxillofac Surg.* 48(2): 225–232.

KEYWORDS Biomechanics; electromyography; temporomandibular joint; masticatory muscles

 emilie.de-brosse@univ-lorraine.fr