



**HAL**  
open science

## Susceptibility Vessel Sign and Cardioembolic Etiology in the THRACE Trial

Romain Bourcier, Imad Derraz, Béatrice Delasalle, Marine Beaumont, Sebastien Soize, Laurence Legrand, Hubert Desal, Serge Bracard, Olivier Naggara, Catherine Oppenheim

► **To cite this version:**

Romain Bourcier, Imad Derraz, Béatrice Delasalle, Marine Beaumont, Sebastien Soize, et al.. Susceptibility Vessel Sign and Cardioembolic Etiology in the THRACE Trial. *Clinical Neuroradiology*, 2019, 29 (4), pp.685-692. 10.1007/s00062-018-0699-8. hal-03227923

**HAL Id: hal-03227923**

**<https://hal.univ-lorraine.fr/hal-03227923v1>**

Submitted on 17 Nov 2024

**HAL** is a multi-disciplinary open access archive for the deposit and dissemination of scientific research documents, whether they are published or not. The documents may come from teaching and research institutions in France or abroad, or from public or private research centers.

L'archive ouverte pluridisciplinaire **HAL**, est destinée au dépôt et à la diffusion de documents scientifiques de niveau recherche, publiés ou non, émanant des établissements d'enseignement et de recherche français ou étrangers, des laboratoires publics ou privés.



Distributed under a Creative Commons Attribution - NonCommercial 4.0 International License

# Susceptibility Vessel Sign and Cardioembolic Etiology in the THRACE Trial

Romain Bourcier<sup>1</sup> · Imad Derraz<sup>2</sup> · Béatrice Delasalle<sup>3,9</sup> · Marine Beaumont<sup>4,10,11</sup> · Sebastien Soize<sup>5,8</sup> · Laurence Legrand<sup>6,12</sup> · Hubert Desal<sup>1</sup> · Serge Bracard<sup>2</sup> · Olivier Naggara<sup>6,7,12</sup> · Catherine Oppenheim<sup>6,12</sup> ·

THRACE investigators

## Abstract

**Purpose** The susceptibility vessel sign (SVS) has been described on gradient echo (GRE) magnetic resonance imaging (MRI) in acute ischemic stroke patients by large vessel occlusion. The presence of SVS (SVS+) was associated with treatment outcome and stroke etiology with conflicting results. Based on multicenter data from the THRombectomie des Artères CÉrebrales (THRACE) study, we aimed to determine if the association between SVS and cardioembolic etiology (CE) was independent of GRE sequence parameters.

**Material and Methods** Patients with a pretreatment brain GRE sequence were identified. Logistic regression tested the association between SVS+, CE, time from onset to imaging and GRE sequence parameters (e.g. echo time, voxel size, field strength). We calculated the sensitivity, specificity, positive and negative predictive values (PPV and NPV) for the SVS to predict a stroke from a CE.

**Results** An SVS+ was observed in 237 out of 287 (83%) patients. In the univariate analysis, there was a significant association between SVS+ and a CE with an odds ratio (OR) and 95% confidence interval (95% CI) of 2.10 (1.02–4.29), respectively ( $p = 0.04$ ) but not with GRE sequence parameters. In multivariate analysis, there was an independent relationship between SVS+ and CE (OR [95% CI]: 2.14 [1.02–4.45],  $p = 0.04$ ). Sensitivity and specificity of SVS+ to predict CE were 0.89 and 0.21, respectively. The PPV and NPV of SVS+ were 0.44 and 0.78, respectively.

**Conclusion** The presence of SVS is associated to CE, independent of GRE sequence parameters. While the specificity and the PPV of the sign were low, CE seems less likely in the absence of an SVS.

**Keywords** Thrombus · Magnetic resonance imaging · Ischemia

---

Olivier Naggara and Catherine Oppenheim have equally contributed to this work.

---

**Contributorship Statement** Romain Bourcier had the original idea and co-wrote the manuscript. Catherine Oppenheim and Olivier Naggara co-wrote the manuscript. Marine Beaumont, Sebastien Soize, Laurence Legrand, Serge Bracard, Hubert Desal, Imad Derraz made a critical interpretation of the data and a critical review of the manuscript. Beatrice Delasalle made the statistical interpretation of the data and revised the article.

---

**Data Sharing** Data are available upon request from the corresponding author.

---

✉ Romain Bourcier  
Romain.bourcier2@gmail.com

Extended author information available on the last page of the article

## Background

Unravelling the etiology in acute ischemic stroke (AIS) is important because it could potentially affect secondary stroke prevention strategies. In many AIS patients, however, risk factors for both large artery atherosclerotic and cardioembolic etiologies (CE) are present. Furthermore, for up to 30% of strokes, the exact etiology remains uncertain [1]. Due to the technique of endovascular retrieval, thrombus composition could potentially provide an important clue regarding stroke etiology; however, no clear association between thrombus composition and the etiology was found in the literature [2–9]. Further understanding of the association between imaging characteristics of a thrombus and the etiology could be useful to help determine stroke etiology. The susceptibility vessel sign (SVS) on gradient echo (GRE) imaging is defined as a hypointense signal exceeding the diameter of the contralateral artery at the site of

the thrombus [10]. The SVS is seen in 50–85% of cases of AIS, particularly in cases of a red blood cell-dominant thrombus, whereas a lack of SVS is indicative for a fibrin-dominant thrombus [11–17]. The SVS has been related to the stroke etiology with variable degrees of reliability [2, 12–14, 17–19]. Only small retrospective monocentric studies have found an association between the presence of SVS and CE in AIS [15, 20, 21].

With more than 300 hundred patients included with magnetic resonance imaging (MRI) performed at the acute phase of stroke, the multicenter THRombectomie des Artères CErebrales (THRACE) study [22] offers a unique opportunity to determine if there is an association between SVS and CE independent of GRE sequence parameters.

## Material and Methods

### THRACE Study Design

The THRACE study was a randomized controlled trial carried out in 26 centers in France. The study design and protocol were previously detailed [22]. Patients with AIS were eligible for inclusion if they were aged 18–80 years, had a US National Institutes of Health Stroke Scale (NIHSS) score of 10–25, had an occlusion of the intracranial internal carotid artery (ICA) or the M1 segment of the middle cerebral artery (MCA) on MR angiography, could be administered intravenous thrombolysis within 4 h of symptom onset and if thrombectomy could be initiated within 5 h of symptom onset. Patients who had cervical ICA occlusion and subocclusive stenosis were excluded. Patients were randomized (1:1) as soon as possible to receive either intravenous thrombolysis and mechanical thrombectomy (IVTMT group) or intravenous thrombolysis alone (IVT group). Randomization was done at the coordination center by a computer analyst who was masked to the investigation centers and to the patients. Before randomization, written informed consent was obtained from all patients or their legal representatives. The study protocol was approved by the Comité de Protection des Personnes III Nord Est Ethics Committee and the research boards of the participating centers.

### Clinical and Biological Data

Clinical and biological data included age, gender, smoking rate, history of high blood pressure, diabetes mellitus, hypercholesterolemia, coronary artery disease, previous stroke, mean glycemia level at inclusion, topography of occlusion (M1 or ICA) and time from onset to imaging. At day seven or at discharge, a vascular neurologist recorded the suspected etiology of cerebral infarction with

the Trial of Org 10172 in Acute Stroke Treatment (TOAST) classification [23].

### Work-up for Cardioembolic Stroke

In the THRACE trial the recommended general work-up according to the European Stroke Organisation (ESO) guidelines [24], included physiological parameters and routine blood tests, a 12-lead electrocardiography (ECG) and continuous ECG. In addition, a 24-h Holter ECG monitoring was performed when arrhythmia was suspected and no other causes of stroke were found. The echocardiography was recommended when ECG abnormalities or evidence of cardiac disease from the patient history were reported or when no other identifiable causes of stroke were found.

### Imaging Data

This study included patients screened with MRI GRE sequence in the THRACE trial and analysis of the SVS available. Patients with severe motion artefacts on GRE sequences were excluded when the presence or absence of SVS could not be reliably determined and patients who were screened with susceptibility-weighted imaging instead of a GRE sequence were also excluded because susceptibility-weighted imaging was scarcely used in THRACE patients. The MRI acquisition parameters of the sequence were left to the discretion of the recruitment centers according to their routine practice without any standardization. Hence, MRI and GRE sequence parameters recorded included slice thickness, interslice gap, flip angle, echo time, field strength and voxel acquisition size. An imaging core laboratory centrally analyzed MRI images and SVS was defined as a hypointense signal on GRE within a vascular cistern exceeding the size of the homologous contralateral arterial diameter [10]. The core laboratory reading team consisted of 4 neuroradiologists with >5 years of experience in stroke imaging. For the purpose of this ancillary study, a fifth reader with <2 years of experience in stroke imaging, performed an independent reading session and, 1 month apart, a second reading session to test intrareader agreement.

### Statistical Analysis

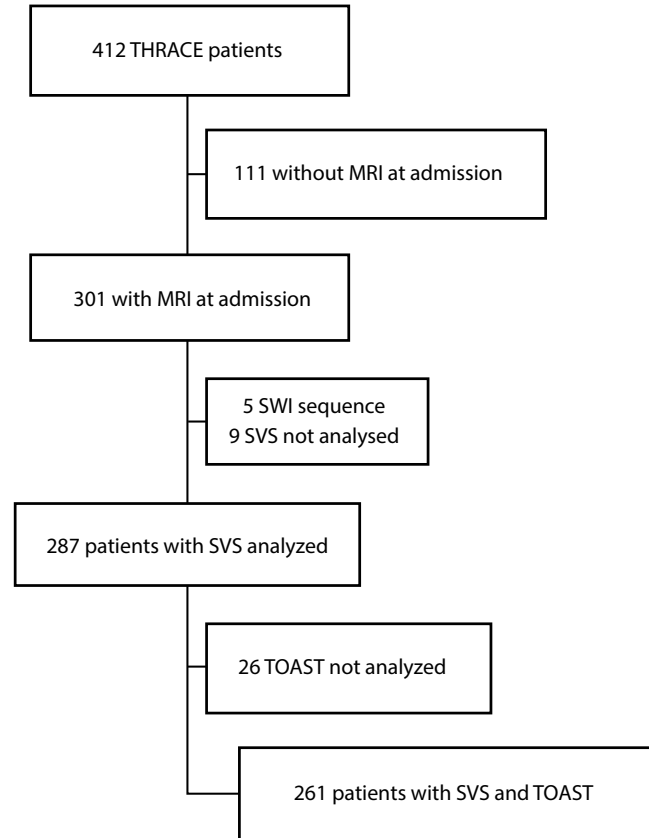
Continuous data are presented as mean ( $\pm$ standard deviation) or median (interquartile range, IQR) based on the distribution. Categorical variables are presented as counts (proportions). The Mann-Whitney U-test and the t-test were performed to test for statistical differences in continuous parameters between two groups. The  $\chi^2$ -test or Fisher's exact test (based on expected frequency) was used to com-

pare categorical variables between groups. Intrareader and interreader agreement for determination of SVS were assessed using kappa statistics. A multivariable mixed logistic regression model was used to examine the association between SVS and CE adjusted for potential confounders, selected a priori technical parameters (echo time, 3T and voxel size) and time from onset to imaging or those that differed with a  $p$  value  $< 0.20$  in the SVS subgroups univariate analysis ( $p < 0.20$ ). To account for a potential variability across centers, this was considered as a random effect in the mixed logistic regression model. Odds ratio (OR) and the 95% confidence intervals (CI) were derived from the logistic model as effect size. Finally, the diagnostic values and the 95% CI for the SVS, e.g. sensitivity, specificity, positive predictive value (PPV), negative predictive value (NPV) and accuracy rate were calculated to predict a stroke from a CE. A  $p$ -value  $< 0.05$  was considered statistically significant. All  $p$ -values are two-sided. Data were analyzed with the SAS packages (SAS Institute, version 9.4, Cary, NC, USA).

## Results

The flow chart for inclusion is presented in Fig. 1. Of the 412 patients included in the THRACE trial, 301 were included in THRACE based on pretreatment brain MRI, 14 patients were excluded from the analysis (poor imaging quality,  $n=9$ ; no GRE sequence,  $n=5$ ) and 287 patients were included with a 1.5T ( $n=176$ , 61.3%) or a 3T field strength MR unit ( $n=111$ , 38.7%). An SVS was observed in 237 out of 287 patients (83%). Data for the TOAST evaluation were lacking in 26 patients who were excluded from the regression analysis. Intrareader and interreader agreement for determination of SVS were 0.94 and 0.83, respectively.

Overall, the mean (SD) slice thickness (mm), interslice gap (mm), echo time (ms) and voxel size were 4.96 (0.42), 0.55 (0.51), 19.47 (6.50) and 4 (1.02), respectively. In the univariate analysis (Table 1), there was a significant association between the presence of SVS and a CE (OR [95% CI]: 2.10 [1.02–4.29],  $p=0.037$ ) but not with time from onset to imaging, echo time, 3T field strength and voxel size. In multivariate mixed logistic regression analysis including time from onset to imaging, echo time, 3T field strength and voxel size as fixed effects and center as a random effect, the relationship between SVS and CE was significant with a similar estimate as obtained in univariate analysis (OR [95% CI]: 2.14 [1.02–4.45],  $p=0.041$ ). In comparison to a no information rate of 58.8%, the sensitivity and the specificity of the SVS to predict a stroke from a CE origin was 0.89 (95% CI, 0.83–0.95) and 0.21 (95% CI, 0.14–0.27), respectively, while PPV and NPV were 0.44 (95% CI, 0.37–0.51) and 0.73 (0.59–0.86), re-



**Fig. 1** Flow chart for inclusion of subjects in the study. *MRI* magnetic resonance imaging, *SVS* susceptibility vessel sign, *SWI* susceptibility-weighted imaging, *THRACE* THRombectomie des Artères Cerebrales study, *TOAST* Trial of Org 10172 in Acute Stroke Treatment

spectively. Overall the diagnostic accuracy was 0.49 (95% CI, 0.42–0.55).

## Discussion

In this study SVS was associated with CE after adjustment for GRE sequence parameters and time from onset to imaging. Furthermore, in the absence of SVS cardioembolism was unlikely. Randomized control trials that have demonstrated superiority of bridging therapy over best medical care included patients based on the presence of a large vessel occlusion, without any information on thrombus characteristics [25]. Studies on human thrombi retrieved from AIS patients have revealed varying compositions [3, 6, 8, 9]. Published articles failed to find a reliable and reproducible association between the thrombus histology and stroke etiology [2]. There is an inherent bias in assessing the histological characteristics of retrieved thrombi in vivo in relation to the stroke etiology: IVT is administered before histological analysis and only the thrombi retrieved are available for analysis, which might bias the analysis [26, 27]. Hence,

**Table 1** Univariate and multivariate analysis for the presence of SVS

<i>Univariate analysis</i>	<i>OR</i>	<i>95% CI</i>	<i>p-value</i>
Time from onset to imaging in minutes	1.10	0.68–1.81	0.67
Cardioembolic stroke	2.10	1.02–4.29	<b>0.04</b>
Echo time	1.21	0.72–2.01	0.46
3T	0.94	0.50–1.74	0.83
Voxel size in micrometer	1.06	0.78–1.44	0.70
<i>Multivariate analysis<sup>a</sup></i>			
Time from onset to imaging in minutes	1.12	0.66–1.88	0.68
Cardioembolic stroke	2.14	1.02–4.45	<b>0.04</b>
Echo time in seconds	1.02	0.95–1.10	0.57
3T	1.04	0.44–2.41	0.93
Voxel size in micrometer	0.92	0.66–1.28	0.62

<sup>a</sup>Multivariate mixed logistic regression model including center as random effect

Figures given in bold type are statistically significant  
*OR* odds ratio, *CI* confidence interval,

the GRE imaging characteristics of thrombi could therefore provide a relevant short-cut towards the stroke etiology without histological examination. A previous, smaller and monocentric study has already found a positive association between the GRE SVS on a 1.5T MR unit and a CE [15]. This study provides the largest prospective study with a systematic evaluation of the SVS related to the stroke etiology and exhaustive GRE sequence parameters could also be precisely recorded in order to analyze the weighting in the relationship between SVS visibility and CE. Several GRE parameters theoretically modify the detection of SVS on GRE sequence. The SVS is due to the presence of a paramagnetic blood clot which induces local magnetic field heterogeneities, proportional to the static magnetic field ( $B_0$ ). The protons submitted to these field distortions precess at frequencies different from the Larmor frequency, resulting in signal shift and/or signal loss, especially with a GRE sequence which does not correct for spin dephasing. The so-called susceptibility artifact is proportional to the dephasing time of the spins (echo time) and to the frequency spectrum

**Table 2** Baseline characteristics and gradient echo sequence parameters of SVS+ and SVS– patients

		SVS– ( <i>n</i> = 50)	SVS+ ( <i>n</i> = 237)	<i>p</i> -value
Age (years)	(mean, SD)	62 (14)	63 (14)	0.40
Female sex	( <i>n</i> , %)	26 (52)	112 (47)	0.54
Smoking	( <i>n</i> , %)	19 (44)	89 (41)	0.74
Hypertension	( <i>n</i> , %)	30 (60)	119 (51)	0.24
Diabetes mellitus	( <i>n</i> , %)	6 (12)	23 (10)	0.65
Hypercholesterolemia	( <i>n</i> , %)	22 (55)	113 (53)	0.82
Coronary artery disease	( <i>n</i> , %)	8 (17)	34 (15)	0.67
History of stroke	( <i>n</i> , %)	3 (6)	15 (7)	0.61
Glycemia (gram/liter)	(mean, SD)	1.21 (0.35)	1.24 (0.43)	0.64
M1 versus ICA occlusion	( <i>n</i> , %)	42 (84)	197 (83)	0.90
Time from onset to MRI (minutes)	(median, IQR)	113 (61)	113 (48)	0.41
TOAST classification	Large artery atherosclerosis ( <i>n</i> , %)	9 (20)	31 (14)	0.14
	Cardioembolic stroke ( <i>n</i> , %)	12 (27)	96 (44)	–
	Other determined cause of stroke ( <i>n</i> , %)	5 (11)	11 (5)	–
	Undetermined cause of stroke ( <i>n</i> , %)	18 (41)	79 (36)	–
Cardioembolic stroke vs. others	( <i>n</i> , %)	12 (27)	96 (44)	0.04
Manufacturer	GE <sup>a</sup> medical system ( <i>n</i> , %)	25 (50)	102 (43)	0.62
	Philips Healthcare <sup>b</sup> ( <i>n</i> , %)	14 (32)	85 (36)	–
	Siemens <sup>c</sup> ( <i>n</i> , %)	9 (18)	50 (21)	–
Slice thickness (millimeter)	(mean, SD)	4.94 (0.47)	4.98 (0.44)	0.53
Inter slice gap (millimeter)	(mean, SD)	0.53 (0.47)	0.55 (0.52)	0.95
Flip angle (°)	(mean, SD)	21.1 (10)	20.05 (5)	0.83
Echo time (millisecond)	(mean, SD)	18.64 (8.56)	19.35 (5.92)	0.13
3T	( <i>n</i> , %)	30 (60)	146 (62)	0.83
Voxel size (micrometer)	(mean, SD)	3.99 (1.12)	4.05 (0.97)	0.24

*ICA* Intracranial carotid artery, *MRI* Magnetic Resonance Imaging, *TOAST* Trial of ORG 10172 in Acute Stroke Treatment, *SVS* Susceptibility Vessel Sign, *SD* Standard Deviation, *IQR* Inter Quartiles Range

<sup>a</sup> GE Medical Systems, Chicago, IL, USA

<sup>b</sup> Philips Medical Systems, Best, The Netherlands

<sup>c</sup> Siemens Healthineers, Erlangen, Germany

within a voxel. In theory, the main GRE sequence parameters prone to modify the SVS should be B0, TE and the voxel size [28, 29]; therefore, the multivariate analysis was adjusted based on these parameters. Besides the association between SVS and CE independent of GRE sequence parameters, the sensitivity of the SVS to identify a CE stroke was found to be 0.89 and the negative predictive value was 0.78. The small number of false negative patients (i.e. no SVS but CE) suggest that CE is unlikely in patients without SVS. The few false negative patients might be explained by the limited paramagnetic effect, i.e. blooming effect in smaller thrombi, which might be more difficult to identify [10]. Furthermore, interreader agreement was high (0.94) but not perfect and some false negative cases may have been the consequence of imperfect rating. In addition, small-sized red thrombi might have been missed because of the GRE interslice gap; however, the mean slice thickness and the interslice gaps of MRI acquisition were similar in the SVS- and the SVS+ patients (Table 2). These results contradict previous results [30–33], which suggested that CE was related to fibrin-rich thrombi. Indeed, the SVS reflects higher red blood cell content, which seems to be less prevalent in cardioembolic stroke.

On the other hand, the specificity (21%) and the positive predictive value (44%) of the SVS to identify CE were low in this study: 121 SVS+ patients were classified as having a stroke etiology other than cardioembolism and among them, 31 of the 40 large artery atherosclerosis had an SVS+. This may be attributable to the process of clot formation; however, SVS alone cannot differentiate the initial thrombus from the secondary components promoted by the blood stasis proximal and distal to the occlusion site, which may also increase the content of red blood cells in SVS [34].

The authors acknowledge limitations in the study. First, detailed information on the quality of work-up was lacking and therefore a bias in analysis regarding the difference in work-up quality across centers cannot be excluded; however, all THRACE centers followed the general work-up according to the ESO guidelines [24]. Second, in this study the no information rate has a better accuracy value as compared to considering the SVS+ vs. SVS- (58.8% estimated vs. 49.0% using SVS). Hence, the overall performance is worse than simple guessing and the overall weak performance of the SVS in predicting stroke etiology has to be mentioned. Third, the International Normalized Ratio (INR), platelet count and previous use of antiplatelets were not recorded and these factors may have an influence on SVS detectability [35, 36]. Fourth, the SVS was only analyzed as a binary variable (presence/absence; [10]), whereas others distinguished different subtypes of SVS (namely “two-layer SVS”) on 3T MRI, or quantitative estimation based on susceptibility-weighted imaging to assess the overestimation ratio. In line with these findings, the two latter stud-

ies demonstrated an association with CE [21, 37]. Fifth, because SWI was seldom performed in THRACE patients (5/301 in the THRACE trial), we chose to exclude them from the current study, despite its inherent better sensitivity than GRE in detecting the SVS, particularly for distal or fragmented thrombi [38–40]. Last, band width, which may also influence SVS visibility had not been recorded.

## Conclusion

After adjustment for GRE sequence parameters, an independent association was found between CE and SVS. In the absence of SVS, CE was unlikely. These results from the largest series to date could guide the stroke etiological work-up and interpretation of the visualization of this radio marker in the context of AIS.

**The THRACE trial investigators** are Alain Bonafé (Department of Neuroradiology, Gui de Chauliac Hospital, Montpellier, France), Xavier Leclerc (Department of Radiology, University Hospital of Lille, Lille, France), Nelly Agrinier (Department of Clinical Epidemiology INSERM CIC-EC 1433, University of Lorraine and University Hospital of Nancy, Nancy, France), Serge Bakchine (Department of Neurology, University Hospital of Reims, Reims, France), Flore Baronnet (Stroke Unit, Pitié-Salpêtrière Hospital Group and Paris 6 University—Pierre et Marie Curie, Paris, France), Marine Beaumont (Department of INSERM CIC-IT, University of Lorraine and University Hospital of Nancy, Nancy, France), Yannick Bejot (Department of Neurology, University Hospital of Dijon, Dijon, France), Jerome Berge (Department of Interventional and Diagnostic Neuroradiology, University Hospital of Bordeaux, Bordeaux, France), Marc Bintner (Department of Neuroradiology Sud-Reunion Hospital Group, Saint Pierre, France), Romain Bourcier (Department of Interventional and Diagnostic Neuroradiology, University Hospital of Nantes, Nantes, France), Tae Hee Cho (Department of Neurology, University Hospital of Lyon, Lyon, France), Frédéric Clarencon (Department of Interventional Neuroradiology Pitié-Salpêtrière Hospital Group and Paris 6 University—Pierre et Marie Curie, Paris, France), Julien Cogez (Department of Neurology, University Hospital of Caen, Caen, France), Charlotte Cordonnier (Department of Neurology, University Hospital of Lille, Lille, France), Christian Denier (Department of Neurology, University Hospital of Bicêtre, Le Kremlin-Bicêtre, France), Anne Laure Derelle (Department of Diagnostic and Interventional Neuroradiology, University Hospital of Nancy, Nancy, France), Olivier Detante (Department of Neurology, University Hospital of Grenoble, Grenoble, France), Anthony Faivre (Department of Neurology, Hôpital d’Instruction des Armées, Sainte Anne, Toulon, France), Anne Ferrier, (Department of Neurology, University Hospital Gabriel-Montpied, Clermont-Ferrand, France), Laetitia Gimenez (Department of Neurology, University Hospital of Limoges, Limoges, France), Sophie Godard (Department of Neurology, University Hospital of Angers, Angers, France), Benoit Guillon (Department of Neurology, University Hospital of Nantes, Nantes, France), Emmanuel Houdart (Department of Neuroradiology, University Hospital Lariboisière, Paris, France), Bertrand Lapergue (Department of Neurology, Foch Hospital, Suresnes, France), Mariano Musacchio (Department of Neuroradiology, Pasteur Hospital, Colmar, France), Olivier Naggara (Department of Neuroradiology, Sainte-Anne Hospital and Paris-Descartes University, INSERM U894, Paris, France), Jean Philippe Neau (Department of Neurology, University Hospital of Poitiers, Poitiers, France), Michael Obadia (Department of Neurology, Rothschild Ophthalmological Foundation, Paris, France),

Anne Pasco-Papon (Department of Radiology, University Hospital of Angers, Angers, France), Michel Piotin (Department of Interventional Neuroradiology [MP] Rothschild Ophthalmological Foundation, Paris, France), Laurent Pierot (Department of Neuroradiology, University Hospital of Reims, Reims, France), Helene Raoult (Department of Neuroradiology, University Hospital of Rennes, Rennes, France), Sébastien Richard (Department of Neurology University Hospital of Nancy, Nancy, France), Frederic Ricolfi (Department of Neuroradiology, University Hospital of Dijon, Dijon, France), Thomas Ronziere (Department of Neurology, University Hospital of Rennes, Rennes, France), Guillaume Saliou (Department of Neuroradiology, University Hospital of Bicêtre, Le Kremlin-Bicêtre, France), Igor Sibon (Department of Neurology, University Hospital of Bordeaux, Bordeaux, France), Sebastien Soize (Department of Neuroradiology, University Hospital of Reims, Reims, France), Jacques Sedat (Department of Radiology, University Hospital of Nice, Nice, France), Christian Stapf (Department of Neurology, University Hospital Lariboisière, Paris, France), Laurent Suissa (Department of Neurology, University Hospital of Nice, Nice, France), Marie Tisserand (Department of Neuroradiology, Sainte-Anne Hospital and Paris—Descartes University, INSERM U894, Paris, France), Francis Turjman (Department of Interventional Neuroradiology, University Hospital of Lyon, Lyon, France), and Stephane Velasco (Departments of Radiology, University Hospital of Poitiers, Poitiers, France).

**Funding** The French Ministry for Health funded this study as part of its 2009 STIC program for the support of costly innovations (grant number 2009 A00753-54).

### Compliance with ethical guidelines

**Conflict of interest** R. Bourcier, I. Derraz, B. Delasalle, M. Beaumont, S. Soize, L. Legrand, H. Desal, S. Bracard, O. Naggara and C. Oppenheim declare that they have no competing interests.

**Ethical standards** Written informed consent was obtained from all patients or their legal representatives. The study protocol was approved by the Comité de Protection des Personnes III Nord Est Ethics Committee and the research boards of the participating centers.


### References

- Goldstein LB, Jones MR, Matchar DB, Edwards LJ, Hoff J, Chaturvedi S, et al. Improving the reliability of stroke subgroup classification using the Trial of ORG 10172 in Acute Stroke Treatment (TOAST) criteria. *Stroke*. 2001;32:1091–8.
- Brinjikji W, Duffy S, Burrows A, Hacke W, Liebeskind D, Majoie CBLM, et al. Correlation of imaging and histopathology of thrombi in acute ischemic stroke with etiology and outcome: a systematic review. *J Neurointerv Surg*. 2016;9:529–34.
- Liebeskind DS, Sanossian N, Yong WH, Starkman S, Tsang MP, Moya AL, et al. CT and MRI early vessel signs reflect clot composition in acute stroke. *Stroke*. 2011;42:1237–43.
- Boeckh-Behrens T, Schubert M, Förschler A, Prothmann S, Kreiser K, Zimmer C, et al. The impact of histological clot composition in embolic stroke. *Clin Neuroradiol*. 2016;26:189–97.
- Kim SK, Yoon W, Heo TW, Park MS, Kang HK. Negative susceptibility vessel sign and underlying intracranial atherosclerotic stenosis in acute middle cerebral artery occlusion. *AJNR Am J Neuroradiol*. 2015;36:1266–71.
- Marder VJ, Chute DJ, Starkman S, Abolian AM, Kidwell C, Liebeskind D, et al. Analysis of thrombi retrieved from cerebral arteries of patients with acute ischemic stroke. *Stroke*. 2006;37:2086–93.
- Niessen JM, van der Schaaf IC, van Dam L, Vink A, Vos JA, Schonewille WJ, et al. Histopathologic composition of cerebral thrombi of acute stroke patients is correlated with stroke subtype and thrombus attenuation. *PLoS One*. 2014;9:e88882.
- Sallustio F, Koch G, Di Legge S, Rossi C, Rizzato B, Napolitano S, et al. Intra-arterial thrombectomy versus standard intravenous thrombolysis in patients with anterior circulation stroke caused by intracranial arterial occlusions: a single-center experience. *J Stroke Cerebrovasc Dis*. 2013;22:e323–31.
- Simons N, Mitchell P, Dowling R, Gonzales M, Yan B. Thrombus composition in acute ischemic stroke: a histopathological study of thrombus extracted by endovascular retrieval. *J Neuroradiol*. 2015;42:86–92.
- Rovira A, Orellana P, Alvarez-Sabín J, Arenillas JF, Aymerich X, Grivé E, et al. Hyperacute ischemic stroke: middle cerebral artery susceptibility sign at echo-planar gradient-echo MR imaging. *Radiology*. 2004;232:466–73.
- Bourcier R, Détraz L, Serfaty JM, Delasalle BG, Mirza M, Derraz I, et al. MRI interscanner agreement of the association between the susceptibility vessel sign and histologic composition of thrombi. *J Neuroimaging*. 2017;27:577–82.
- Naggara O, Raymond J, Domingo Ayllon M, Al-Shareef F, Touzé E, Chenoufi M, et al. T2\* “susceptibility vessel sign” demonstrates clot location and length in acute ischemic stroke. *PLoS One*. 2013;8:e76727.
- Aoki J, Kimura K, Shibasaki K, Sakamoto Y, Saji N, Uemura J. Location of the susceptibility vessel sign on T2\*-weighted MRI and early recanalization within 1 hour after tissue plasminogen activator administration. *Cerebrovasc Dis Extra*. 2013;3:111–20.
- Bourcier R, Volpi S, Guyomarch B, Daumas-Duport B, Lintia-Gaultier A, Papagiannaki C, et al. Susceptibility vessel sign on MRI predicts favorable clinical outcome in patients with anterior circulation acute stroke treated with mechanical thrombectomy. *AJNR Am J Neuroradiol*. 2015;36:2346–53.
- Cho KH, Kim JS, Kwon SU, Cho AH, Kang DW. Significance of susceptibility vessel sign on T2\*-weighted gradient echo imaging for identification of stroke subtypes. *Stroke*. 2005;36:2379–83.
- Schellinger PD, Chalela JA, Kang D-W, Latour LL, Warach S. Diagnostic and prognostic value of early MR Imaging vessel signs in hyperacute stroke patients imaged <3h and treated with recombinant tissue plasminogen activator. *AJNR Am J Neuroradiol*. 2005;26:618–24.
- Soize S, Batista AL, Rodriguez Regent C, Trystram D, Tisserand M, Turc G, et al. Susceptibility vessel sign on T2\* magnetic resonance imaging and recanalization results of mechanical thrombectomy with stent retrievers: a multicentre cohort study. *Eur J Neurol*. 2015;22:967–72.
- Legrand L, Naggara O, Turc G, Mellerio C, Roca P, Calvet D, et al. Clot burden score on admission T2\*-MRI predicts recanalization in acute stroke. *Stroke*. 2013;44:1878–84.

19. Kimura K, Sakamoto Y, Iguchi Y, Shibasaki K. Clinical and MRI scale to predict very poor outcome in tissue plasminogen activator patients. *Eur Neurol.* 2011;65:291–5.
20. Kang DW, Jeong HG, Kim DY, Yang W, Lee SH. Prediction of stroke subtype and recanalization using susceptibility vessel sign on susceptibility-weighted magnetic resonance imaging. *Stroke.* 2017;48:1554–9.
21. Zhang R, Zhou Y, Liu C, Zhang M, Yan S, Liebeskind DS, Lou M. Overestimation of susceptibility vessel sign: a predictive marker of stroke cause. *Stroke.* 2017;48:1993–6.
22. Bracad S, Ducrocq X, Mas JL, Soudant M, Oppenheim C, Moulin T, Guillemin F; THRACE investigators. Mechanical thrombectomy after intravenous alteplase versus alteplase alone after stroke (THRACE): a randomised controlled trial. *Lancet Neurol.* 2016;15:1138–47.
23. Adams HP Jr, Bendixen BH, Kappelle LJ, Biller J, Love BB, Gordon DL, Marsh EE 3rd. Classification of subtype of acute ischemic stroke. Definitions for use in a multicenter clinical trial. TOAST. Trial of Org 10172 in acute stroke treatment. *Stroke.* 1993;24:35–41.
24. European Stroke Organisation (ESO) Executive Committee, ESO Writing Committee. Guidelines for management of ischaemic stroke and transient ischaemic attack 2008. *Cerebrovasc Dis.* 2008;25:457–507.
25. Goyal M, Menon BK, van Zwam WH, Dippel DW, Mitchell PJ, Demchuk AM, Dávalos A, Majoie CB, van der Lugt A, de Miquel MA, Donnan GA, Roos YB, Bonafe A, Jahan R, Diener HC, van den Berg LA, Levy EI, Berkhemer OA, Pereira VM, Rempel J, Millán M, Davis SM, Roy D, Thornton J, Román LS, Ribó M, Beumer D, Stouch B, Brown S, Campbell BC, van Oostenbrugge RJ, Saver JL, Hill MD, Jovin TG; HERMES collaborators. Endovascular thrombectomy after large-vessel ischaemic stroke: a meta-analysis of individual patient data from five randomised trials. *Lancet.* 2016;387(10029):1723–31.
26. Cho KY, Miyoshi H, Kuroda S, Yasuda H, Kamiyama K, Nakagawa J, Takigami M, Kondo T, Atsumi T. The phenotype of infiltrating macrophages influences arteriosclerotic plaque vulnerability in the carotid artery. *J Stroke Cerebrovasc Dis.* 2013;22:910–8.
27. Shaikh S, Brittenden J, Lahiri R, Brown PA, Thies F, Wilson HM. Macrophage subtypes in symptomatic carotid artery and femoral artery plaques. *Eur J Vasc Endovasc Surg.* 2012;44:491–7.
28. Hodel J, Leclerc X, Khaled W, Tamazyan R, Rodallec M, Gerber S, Blanc R, Benadjaoud M, Lambert O, Rabrait C, Zuber M, Rahmouni A, Zins M. Comparison of 3D multi-echo gradient-echo and 2D T2\* MR sequences for the detection of arterial thrombus in patients with acute stroke. *Eur Radiol.* 2014;24:762–9.
29. Port JD, Pomper MG. Quantification and minimization of magnetic susceptibility artifacts on GRE images. *J Comput Assist Tomogr.* 2000;24:958–64.
30. Boeckh-Behrens T, Kleine JF, Zimmer C, Neff F, Scheipl F, Pelisek J, Schirmer L, Nguyen K, Karatas D, Poppert H. Thrombus histology suggests cardioembolic cause in cryptogenic stroke. *Stroke.* 2016;47:1864–71.
31. Sporns PB, Hanning U, Schwindt W, Velasco A, Minnerup J, Zoubi T, Heindel W, Jeibmann A, Niederstadt TU. Ischemic stroke: what does the histological composition tell us about the origin of the thrombus? *Stroke.* 2017;48:2206–10.
32. Hashimoto T, Hayakawa M, Funatsu N, Yamagami H, Satow T, Takahashi JC, Nagatsuka K, Ishibashi-Ueda H, Kira JI, Toyoda K. Histopathologic analysis of retrieved thrombi associated with successful reperfusion after acute stroke thrombectomy. *Stroke.* 2016;47:3035–7.
33. Ahn SH, Hong R, Choo IS, Heo JH, Nam HS, Kang HG, Kim HW, Kim JH. Histologic features of acute thrombi retrieved from stroke patients during mechanical reperfusion therapy. *Int J Stroke.* 2016;11:1036–44.
34. Qazi EM, Sohn SI, Mishra S, Almekhlafi MA, Eesa M, d’Esterre CD, Qazi AA, Puig J, Goyal M, Demchuk AM, Menon BK. Thrombus characteristics are related to collaterals and angioarchitecture in acute stroke. *Can J Neurol Sci.* 2015;42:381–8.
35. Yan S, Liu K, Tong L, Yu Y, Zhang S, Lou M. Different risk factors for poor outcome between patients with positive and negative susceptibility vessel sign. *J Neurointerv Surg.* 2016;8:1001–5.
36. Nielsen VG, Kirklin JK, Holman WL, Steenwyk BL. Clot lifespan model analysis of the effects of warfarin on thrombus growth and fibrinolysis: role of contact protein and tissue factor initiation. *ASAIO J.* 2009;55:33–40.
37. Yamamoto N, Satomi J, Tada Y, Harada M, Izumi Y, Nagahiro S, Kaji R. Two-layered susceptibility vessel sign on 3-tesla T2\*-weighted imaging is a predictive biomarker of stroke subtype. *Stroke.* 2015;46:269–71.
38. Boeckh-Behrens T, Lutz J, Lummel N, Burke M, Wesemann T, Schöpf V, Brückmann H, Linn J. Susceptibility-weighted angiography (SWAN) of cerebral veins and arteries compared to TOF-MRA. *Eur J Radiol.* 2012;81:1238–45.
39. Hodel J, Rodallec M, Gerber S, Blanc R, Maraval A, Caron S, Tyvaert L, Zuber M, Zins M. Susceptibility weighted magnetic resonance sequences “SWAN, SWI and VenobOLD”: technical aspects and clinical applications. *J Neuroradiol.* 2012;39:71–86.
40. Park MG, Oh SJ, Baik SK, Jung DS, Park KP. Susceptibility-weighted imaging for detection of thrombus in acute cardioembolic stroke. *J Stroke.* 2016;18:73–9.



## Affiliations

**Romain Bourcier<sup>1</sup>**  · **Imad Derraz<sup>2</sup>** · **Béatrice Delasalle<sup>3,9</sup>** · **Marine Beaumont<sup>4,10,11</sup>** · **Sebastien Soize<sup>5,8</sup>** · **Laurence Legrand<sup>6,12</sup>** · **Hubert Desal<sup>1</sup>** · **Serge Bracard<sup>2</sup>** · **Olivier Naggara<sup>6,7,12</sup>** · **Catherine Oppenheim<sup>6,12</sup>** · **THRACE investigators**

Imad Derraz  
imad.eddine.dr@gmail.com

Béatrice Delasalle  
Beatrice.Guyomarch@univ-nantes.fr

Marine Beaumont  
m.beaumont@chru-nancy.fr

Sebastien Soize  
sebastien.soize@gmail.com

Laurence Legrand  
L.LEGRAND@ch-sainte-anne.fr

Hubert Desal  
hubert.desal@chu-nantes.fr

Serge Bracard  
s.bracard@chru-nancy.fr

Olivier Naggara  
O.NAGGARA@ch-sainte-anne.fr

Catherine Oppenheim  
C.OPPENHEIM@ch-sainte-anne.fr

<sup>1</sup> Department of Diagnostic and Interventional Neuroradiology, Guillaume et René Laennec University Hospital, Nantes, France

<sup>2</sup> Department of Diagnostic and Interventional Neuroradiology, University Hospital of Montpellier, Montpellier, France

<sup>3</sup> L'institut du thorax, Centre Hospitalier Universitaire Nantes, Nantes, France

<sup>4</sup> CIC1433, INSERM, Université de Lorraine, Nancy, France

<sup>5</sup> Department of Diagnostic and Interventional Neuroradiology, University Hospital of Reims, Reims, France

<sup>6</sup> Department of Neuroradiology, Université Paris-Descartes, Paris, France

<sup>7</sup> Pediatric Radiology Department, Necker Enfants Malades, Paris, France

<sup>8</sup> INSERM UMR-S 1237 Physiopathology and imaging of neurological disorders, Université Caen Normandie, Caen, France

<sup>9</sup> UMR1087, Institut National de la Santé et de la Recherche Médicale, Nantes, France

<sup>10</sup> IADI, U1254, Université de Lorraine, Nancy, France

<sup>11</sup> CHRU de Nancy CIC-IT, INSERM, Nancy, France

<sup>12</sup> INSERM U894, Sainte-Anne Hospital, Paris, France