



HAL
open science

**Aneurysmal bone cyst of thoracic vertebrae in a young asymptomatic boy with spinal cord compression.
Successful treatment by percutaneous approach with PMMA-cement**

Romain Tonnelet, Benjamin Gory, Liang Liao, Anne-Laure Derelle, Laurence Mainard-Simard, Pierre Journeau, Sophie Planel, René Anxionnat, Serge Bracard, Marc Braun

► **To cite this version:**

Romain Tonnelet, Benjamin Gory, Liang Liao, Anne-Laure Derelle, Laurence Mainard-Simard, et al.. Aneurysmal bone cyst of thoracic vertebrae in a young asymptomatic boy with spinal cord compression. Successful treatment by percutaneous approach with PMMA-cement. *Interdisciplinary Neurosurgery - Advanced techniques and case management*, 2019, 16, pp.135-138. 10.1016/j.inat.2018.12.012 . hal-03280800


HAL Id: hal-03280800

<https://hal.univ-lorraine.fr/hal-03280800v1>

Submitted on 7 Jul 2021

HAL is a multi-disciplinary open access archive for the deposit and dissemination of scientific research documents, whether they are published or not. The documents may come from teaching and research institutions in France or abroad, or from public or private research centers.

L'archive ouverte pluridisciplinaire **HAL**, est destinée au dépôt et à la diffusion de documents scientifiques de niveau recherche, publiés ou non, émanant des établissements d'enseignement et de recherche français ou étrangers, des laboratoires publics ou privés.



Technical Notes & Surgical Techniques

Aneurysmal bone cyst of thoracic vertebrae in a young asymptomatic boy with spinal cord compression. Successful treatment by percutaneous approach with PMMA-cement

Romain Tonnelet^{a,*}, Benjamin Gory^a, Liang Liao^{a,b}, Anne-Laure Derelle^a, Laurence Mainard-Simard^c, Pierre Journeau^d, Sophie Planel^a, René Anxionnat^a, Serge Bracard^a, Marc Braun^{a,b}

^aNeuroradiology Dpt, CHU Nancy

^bAnatomy Lab, Université de Lorraine

^cRadiology Dpt, Children's Hospital, CHU Nancy

^dOrthopaedic Surgery Dpt, Children's Hospital, CHU Nancy



1. Introduction

Aneurysmal bone cysts (ABCs) represent 1.4% of primary bone tumours and 15% of primary spinal tumours [1,2]. The most common locations are the thoracic and lumbar spinal regions [1,2] (32% thoracic and 34% lumbar) less frequently the cervical region with an incidence of 2–22% depending on the series [3].

Peak incidence is during the first two decades of life. Back pain is by far the most likely clinical sign to reveal the disease and may cause night time waking [4].

Presentation of an ABC with neurological symptoms is rare given the slow growth rate of this tumor. Moreover, prognosis is poor when the tumor is discovered that way, especially when the patient is presenting with a sudden total paraplegia [2].

2. Case and technical report

A 10-year-old boy had been suffering with upper back pain for several weeks. A CT-scan found an expansile lesion in the posterior arch of T3 and T4 extending to the vertebral body of the latter vertebra (Fig. 1D/E/F).

In addition, an MRI was performed in the emergency department enabled firstly the diagnosis of ABCs affecting in particular the pedicles and laminae of vertebrae T3 and T4, and secondly, epidural extension causing spinal cord compression (Fig. 1A/B/C). Surprisingly, the patient did not show any neurological signs of motor deficiency.

After a multi-disciplinary meeting with the paediatric radiologist, interventional neuro-radiologist and paediatric surgeon, we agreed to carry out a percutaneous sclerosis procedure on the lesion.

This was performed with the material used for vertebral

cementoplasty, as described in the article by Fahed et al. [5].

We used a 17G trocar to access the laminae of the two affected vertebrae with the aim of injecting 2 cc of polymethylmethacrylate (PMMA) cement (Biomet - Bone Cement V). Very little amount of PMMA was injected intentionally according to method described by Fahed et al. [5] Pathological analysis of the biopsy carried out during the procedure confirmed the diagnosis of ABC.

Before the procedure, 2 cc of iodine (ONMIPAQUE 180) was injected to help predict the distribution pattern of the cement when injected, and also to make sure there was no intradural leakage which could aggravate the underlying spinal cord compression. The whole procedure was carried out under CT guidance (Fig. 2A–B).

Six months later, the patient had not shown any clinical signs of worsening, in particular regarding motor function (no paraparesis). A reduction in back pain was noted. The monitoring CT-scan carried out at the time showed ongoing consolidation of the lesions targeted by the treatment, signalling their gradual sclerosis (Fig. 2C–D). A very clear retraction of the epidural tumor component could already be seen with the calibre of the spinal canal almost returned to its original condition (Fig. 3).

A monitoring MRI was performed 1 year after the treatment. The patient no longer had back pain and was able to take part in all activities of daily life. The MRI confirmed the complete sclerosis of the lesions as well as the disappearance of the epidural extension initially responsible for the spinal compression (Fig. 4).

3. Discussion

This case study reports the successful treatment of an ABC in a young patient presenting with back pain without neurological deficit.

Multiple therapeutic approaches exist, as reported in the review of

Abbreviations: ABC, Aneurysmal Bone Cyst; CT, Computed-Tomography; MRI, Magnetic Resonance Imaging; PMMA, polymethylmethacrylate

* Corresponding author at: Neuroradiology Dpt, CHU Nancy, France

E-mail address: r.tonnelet@chru-nancy.fr (R. Tonnelet).

<https://doi.org/10.1016/j.inat.2018.12.012>

Received 1 September 2018; Received in revised form 4 November 2018; Accepted 30 December 2018

2214-7519/© 2019 Published by Elsevier B.V.

This is an open access article under CC BY-NC-ND license. (<http://creativecommons.org/licenses/by-nc-nd/4.0/>)

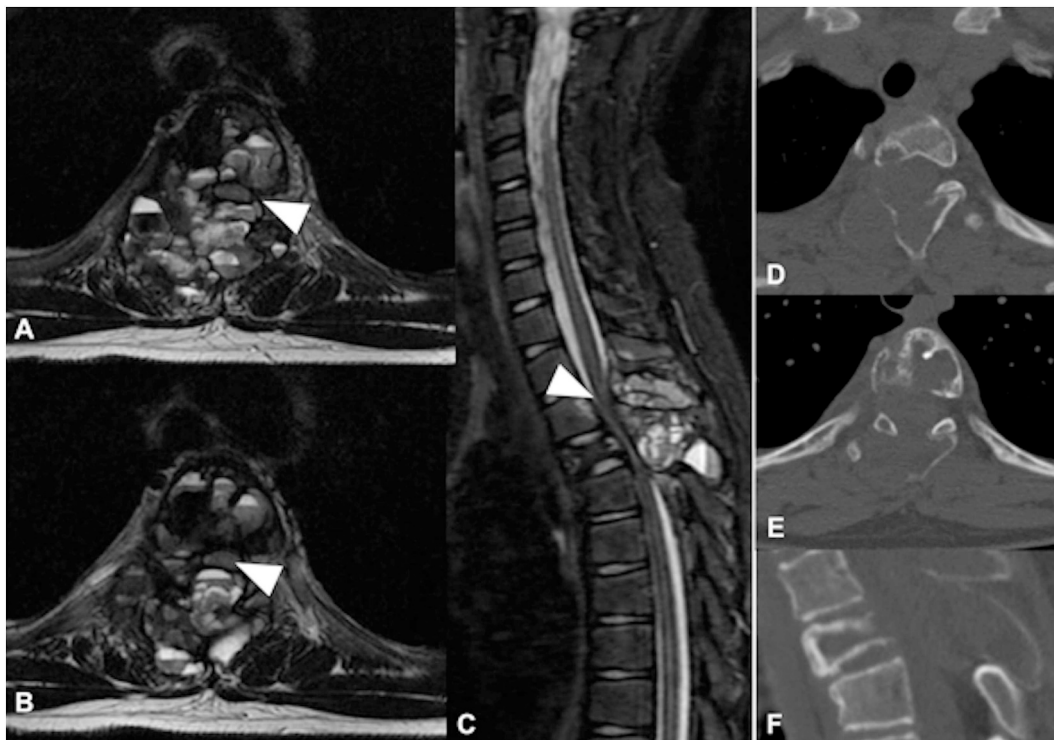

Fig. 1. Axial T2 spin-echo with Fat-Sat MRI at level T3 (A) and T4 (B) showing the typical pattern of aneurysmal bone cyst with multi-loculated cysts (soap-bubble appearance) and fluid-fluid level (haemorrhagic component of the cysts) involving both vertebral bodies with extension to the right pedicles, laminae and spinous processes. There is epidural extension of the lesions leading to spinal cord compression at T3 and mainly T4 level (white arrowhead), as shown on axial and sagittal T2 SE Fat-Sat MRI (C). The CT-scan without contrast shows cortical erosion and balloon-like appearance of the cortical bone at level T3 (D) and T4; there was also a compression fracture of vertebra T4 with erosion of the posterior vertebral wall. (E & F).

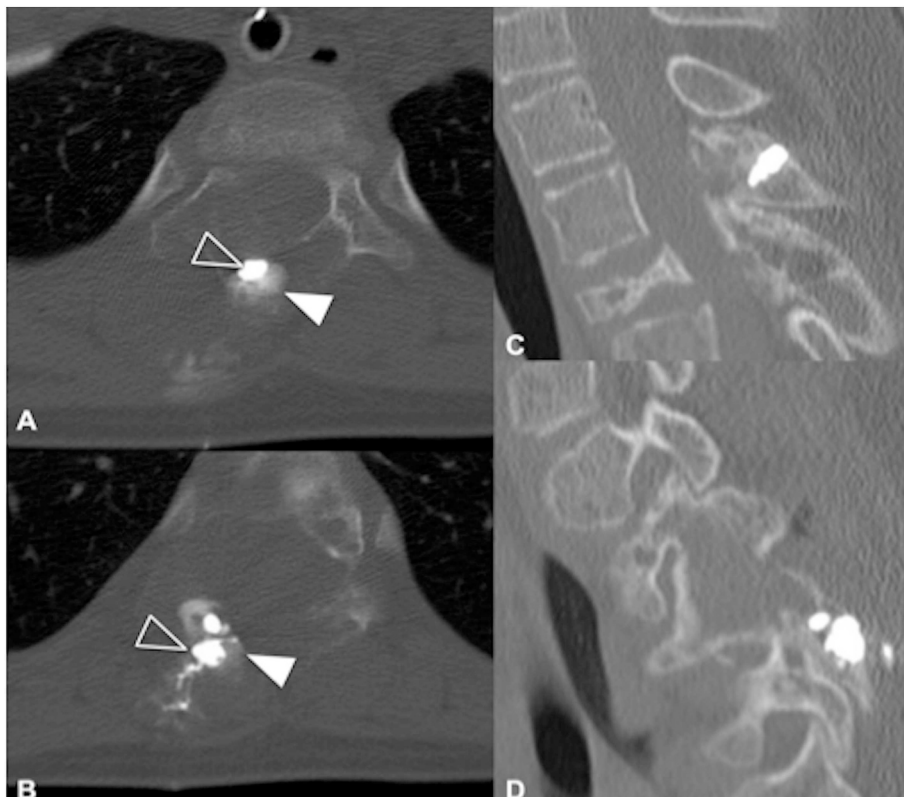


Fig. 2. Axial intra-operative CT-scan showing the site of injection of iodine contrast in the posterior arch of the T3 (A) and T4 (B) vertebrae (white arrowhead) followed by injection of a small amount of PMMA (empty arrowhead). Monitoring CT-scan at 6 months (C & D) showing placement of cement in the posterior arches of the treated vertebrae.

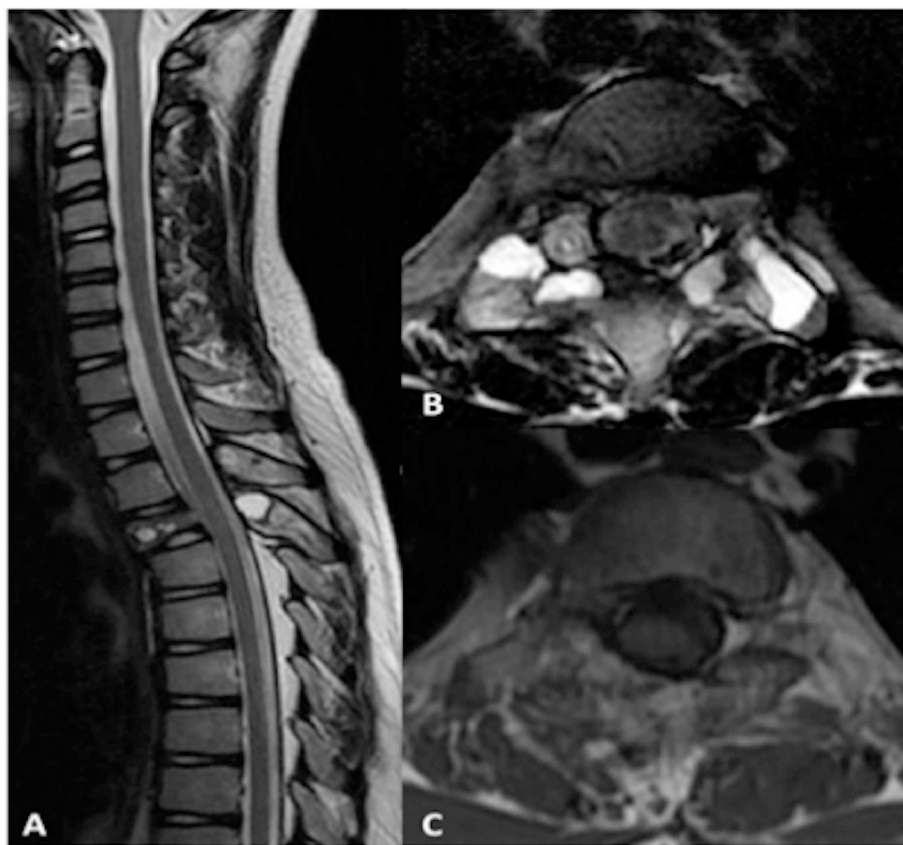


Fig. 3. Monitoring MRI-scan AT 1 year. A) Sagittal and Axial level-T4, T2 SE sequence showing a significant reduction in the aneurysmal cystic lesions of which some cyst-like spaces persist within the posterior arch of T4. Same level axial T1SE showing intra-cyst modification suggesting sclerosis processus with reossification and reconstitution of the cortical bone and in particular a clear reduction in the component responsible for the initial spinal compression. At the bottom row, Sagittal T2 STIR comparison at one year from treatment showed more than 7 mm of spinal canal widening at T4-level.

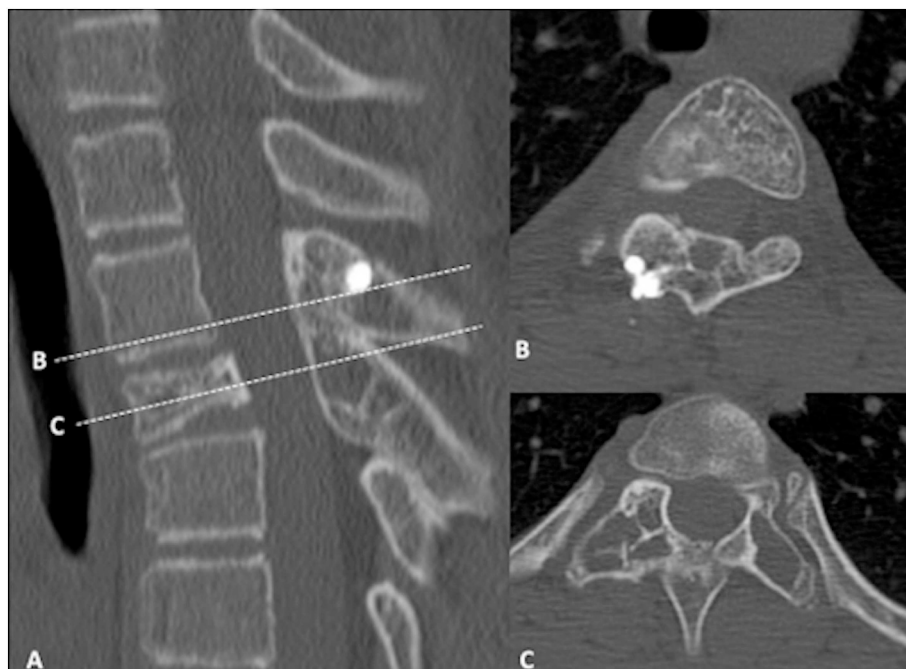


Fig. 4. Monitoring CT-scan AT 2,5 years showing sclerosis of the lesions with reossification of the cortical BONE (A) sagittal view B) & C) axial view through T3 and T4 level) leading to stabilisation of the compression fracture of vertebra T4: reconstruction of a bone matrix within the spongy bone of the vertebral body. Reossification of the posterior vertebral wall of this vertebra is also seen.

literature by Jaiswal et al. [1]: surgery (curettage/complete excision), radiotherapy, arterial embolisation and percutaneous injection with a sclerosing agent.

Previous study from Zileli et al. [4] advocates the use of PMMA to stabilise bony defects after curettage. However, Fahed et al. [5] have reported a favourable clinical course of one patient with an ABC of the cervical spine

that was treated in this way. Guarnieri et al. [6] have also used an osteoconductive cement (CERAMET) to treat a sacral lesion with excellent results.

PMMA cement, in addition to its bio-mechanical consolidation properties, seems to trigger and accelerate the stabilisation of the lesion in the same way as other sclerosing agents, and with a small quantity, as reported by Fahed al [5]. Even with a small quantity of cement, sclerosing

process can be triggered in remote cysts of the lesion not targeted by initial low volume cement injection. This differs from the approach followed by Zileli and Guarnieri consisting in fulfillment of the bony defect.

The main limitation of surgery is the increased risk of recurrence of around 25% in the absence of complete excision of the lesion and 19% for curettage with or without bone graft material [1]. Varshney et al. [7] reported similar rates of around 29% for curettage and bone graft and 15% for «high-speed burring» (extended curettage).

Increasingly, arterial embolisation is becoming established as another therapeutic option. Indeed, the hypervascular nature of ABCs has led some authors to advocate carrying out pre-operative embolisation in the case of surgery [4], or even as the first therapeutic recourse [8,9].

Sclerotherapy, although its use is controversial, gives very good results with a reduction in the recurrence rate of 7 to 13% depending on the series [7,10].

Complications associated with the use of Ethibloc® have been reported (one case of pulmonary embolism, five cases of transient inflammatory response syndrome and four cases of aseptic fistulisation) [11]. However, according to Mascard and Adamsbaum [12], these can be avoided by taking certain precautions. They state that the general inflammatory reaction is part of the efficacy criteria following treatment, and therefore should not be considered as a complication.

Injections of other sclerosing agents (calcitonin + methylprednisolone [7]/polidocanol [13]) have also shown excellent results with a low rate of recurrence during monitoring, and no major complications. PMMA cement has no biological and histological side effects reported upon vertebral bone and surrounding tissue [14].

In view of this encouraging result, the treatment of spinal ABCs by small amount of bone cement could be a possible, less-invasive alternative to surgery, which in this type of spinal location is onerous and often requires instrumentation of the spinal column.

Disclosure

None.

Conflict of interest

None.

References

- [1] A. Jaiswal, V. Vijay, P. Kori, R. Shukla, Aneurysmal bone cyst of thoracic spine: case report and brief review of literature, *BMJ Case. Rep.* 2013 (2013).
- [2] N.O. Ameli, K. Abbassioun, H. Saleh, A. Eslamdoost, Aneurysmal bone cysts of the spine. Report of 17 cases, *J. Neurosurg.* 63 (1985) 685–690.
- [3] H.J. Mankin, F.J. Hornicek, E. Ortiz-Cruz, J. Villafuerte, M.C. Gebhardt, Aneurysmal bone cyst: a review of 150 patients, *J. Clin. Oncol.* 23 (2005) 6756–6762.
- [4] M. Zileli, H.S. Isik, F.E. Ogut, M. Is, S. Cagli, C. Calli, Aneurysmal bone cysts of the spine, *Eur. Spine J.* 22 (2013) 593–601.
- [5] R. Fahed, F. Clarencon, G. Riouallon, et al., Just a drop of cement: a case of cervical spine bone aneurysmal cyst successfully treated by percutaneous injection of a small amount of polymethyl-methacrylate cement, *J. Neurointerv. Surg.* 8 (2016) e4.
- [6] G. Guarnieri, P. Vassallo, M. Muto, Percutaneous treatment of symptomatic aneurysmal bone cyst of L5 by percutaneous injection of osteoconductive material (Cerament), *J. Neurointerv. Surg.* 6 (2014) e43.
- [7] M.K. Varshney, S. Rastogi, S.A. Khan, V. Tripathi, Is sclerotherapy better than intralesional excision for treating aneurysmal bone cysts? *Clin. Orthop. Relat. Res.* 468 (2010) 1649–1659.
- [8] G.R.E. Rossi, T. Bartalena, A. Gerardi, M. Alberghini, E.L. Staals, C. Errani, G. Bianchi, A. Toscana, M. Mercuri, D. Vanel, Selective arterial embolization of 36 aneurysmal bone cysts of the skeleton with N-2-butyl cyanoacrylate, *Skelet. Radiol.* (2010) 161–167.
- [9] L. Amendola, L. Simonetti, C.E. Simoes, S. Bandiera, F. De Iure, S. Boriani, Aneurysmal bone cyst of the mobile spine: the therapeutic role of embolization, *Eur. Spine J.* 22 (2013) 533–541.
- [10] F. Batisse, A. Schmitt, T. Vendevue, D. Herbreteau, C. Bonnard, Aneurysmal bone cyst: a 19-case series managed by percutaneous sclerotherapy, *Orthop. Traumatol. Surg. Res.* 102 (2016) 213–216.
- [11] V. Topouchian, K. Mazda, B. Hamze, J.D. Laredo, G.F. Pennecot, Aneurysmal bone cysts in children: complications of fibrosing agent injection, *Radiology* 232 (2004) 522–526.
- [12] E. Mascard, C. Adamsbaum, Direct ethibloc injection of aneurysmal bone cysts, *Radiology* 236 (2005) 1111.
- [13] O. Brosjo, P. Pechon, A. Hesla, P. Tsagozis, H. Bauer, Sclerotherapy with polidocanol for treatment of aneurysmal bone cysts, *Acta Orthop.* 84 (2013) 502–505.
- [14] J.J. Verlaan, F.C. Oner, P.J. Slootweg, A.J. Verbout, W.J. Dhert, Histologic changes after vertebroplasty, *J. Bone Joint Surg. Am.* 86-A (6) (2004 Jun) 1230–1238.