



HAL
open science

Lung ultrasound in acute and chronic heart failure. A Clinical Consensus Statement of the European Association of Cardiovascular Imaging (EACVI)

Luna Gargani, Nicolas Girerd, Elke Platz, Pierpaolo Pellicori, Ivan Stankovic, Alberto Palazzuoli, Emanuele Pivetta, Marcelo Haertel Miglioranza, Hatem Soliman-Aboumarie, Eustachio Agricola, et al.

► To cite this version:

Luna Gargani, Nicolas Girerd, Elke Platz, Pierpaolo Pellicori, Ivan Stankovic, et al.. Lung ultrasound in acute and chronic heart failure. A Clinical Consensus Statement of the European Association of Cardiovascular Imaging (EACVI). *European Heart Journal - Cardiovascular Imaging*, 2023, 10.1093/ehjci/jead169 . hal-04168006

HAL Id: hal-04168006

<https://hal.univ-lorraine.fr/hal-04168006v1>

Submitted on 21 Jul 2023

HAL is a multi-disciplinary open access archive for the deposit and dissemination of scientific research documents, whether they are published or not. The documents may come from teaching and research institutions in France or abroad, or from public or private research centers.

L'archive ouverte pluridisciplinaire **HAL**, est destinée au dépôt et à la diffusion de documents scientifiques de niveau recherche, publiés ou non, émanant des établissements d'enseignement et de recherche français ou étrangers, des laboratoires publics ou privés.

1 **Lung ultrasound in acute and chronic heart failure. A Clinical Consensus Statement of the**
2 **European Association of Cardiovascular Imaging (EACVI)**

3 Luna Gargani¹, Nicolas Girerd², Elke Platz³, Pierpaolo Pellicori⁴, Ivan Stankovic⁵, Alberto Palazzuoli⁶,
4 Emanuele Pivetta⁷, Marcelo Haertel Miglioranza⁸, Hatem Soliman-Aboumarie⁹, Eustachio Agricola¹⁰,
5 Giovanni Volpicelli¹¹, Susanna Price¹², Erwan Donal¹³, Bernard Cosyns¹⁴, Aleksandar N. Neskovic⁵.

6 *Reviewers: This document was reviewed by members of the 2020-2022 EACVI Scientific*
7 *Documents Committee: Magnus Bäck, Philippe B. Bertrand, Marc Dweck, Niall Keenan, Leyla*
8 *Elif Sade.*
9

10 ¹ Department of Surgical, Medical and Molecular Pathology and Critical Care Medicine, University of
11 Pisa, Italy.

12 ² Université de Lorraine, Centre d'Investigations Cliniques Plurithématique 1433, Institut Lorrain du
13 Cœur et des Vaisseaux Louis Mathieu, CHRU de Nancy, INSERM DCAC, F-CRIN INI-CRCT, Nancy,
14 France.

15 ³ Cardiovascular Division, Brigham and Women's Hospital and Harvard Medical School, Boston, USA.

16 ⁴ Robertson Centre for Biostatistics and Glasgow Clinical Trials Unit, University of Glasgow, University
17 Avenue, Glasgow, UK.

18 ⁵ Clinical Hospital Centre Zemun, Faculty of Medicine, University of Belgrade, Serbia.

19 ⁶ Cardiovascular Diseases Unit, Cardio-thoracic and vascular Department Le Scotte Hospital
20 University of Siena Italy.

21 ⁷ Medicina d'Urgenza-MECAU, Presidio Molinette, A.O.U. Città della Salute e della Scienza di Torino,
22 Italy.

23 ⁸ Institute of Cardiology, University Foundation of Cardiology, Porto Alegre, Brazil.

24 ⁹ Department of Cardiothoracic Anaesthesia and Critical Care, Harefield Hospital, Royal Brompton and
25 Harefield Hospitals, Guy's and St Thomas NHS Foundation Trust, London, UK. School of
26 Cardiovascular Medicine and Sciences, King's College London.

27 ¹⁰ Cardiovascular Imaging Unit, Cardio-Thoracic-Vascular Department, San Raffaele Hospital, Milan,
28 Italy, Vita-Salute University.

29 ¹¹ Department of Emergency Medicine, San Luigi Gonzaga University Hospital, Torino, Italy.

30 ¹² Departments of Cardiology & Intensive Care, Royal Brompton & Harefield Hospitals, part of Guy's
31 and St Thomas NHS Foundation Trust, and National Heart and Lung Institute, Imperial College
32 London, London, UK.

33 ¹³ University of Rennes, CHU Rennes, Inserm, Rennes, France.

34 ¹⁴ Department of Cardiology, Universitair Ziekenhuis Brussel, Jette, Brussels, Belgium.
35

36 Corresponding author:

37 Luna Gargani, MD, PhD

38 Department of Surgical, Medical and Molecular Pathology and Critical Care Medicine

39 University of Pisa, Italy.
40

1 Introduction

2 Lung ultrasound (LUS) was introduced to intensive care units and emergency departments more
3 than 20 years ago, primarily as a tool for the assessment of patients with acute dyspnoea (1,2). Since
4 then, it has gained popularity as a quick point-of-care examination enabling clinicians to answer crucial
5 clinical questions. Over the last decade, the cardiology community has acknowledged the potential of
6 LUS and expanded its use further, to assist with the diagnosis and management of patients with heart
7 failure (HF) (3–5).

8 The importance of recognizing and treating pulmonary congestion is a cornerstone in the
9 management of patients with HF (6). LUS is a versatile, high sensitivity point of care examination to
10 detect pulmonary deaeration due to increased extravascular lung water. It has many advantages to the
11 extent that an integrated cardiopulmonary ultrasound exam is likely to become the reference standard
12 in HF care. This approach allows the aetiology of HF to be defined, through the assessment of cardiac
13 structure and function by echocardiography, at the same time as the assessment of pulmonary
14 congestion provided by LUS. In addition, it facilitates the exclusion of other highly prevalent conditions
15 that may mimic/overlap with HF (e.g., pneumonia, acute lung injury/acute respiratory distress syndrome
16 [ALI/ARDS], pneumothorax).

17

18 Lung ultrasound in heart failure: the findings

19 B-lines and pleural effusions

20 In a fully aerated lung, the only anatomical structure that can be visualized is the pleura, which
21 appears as a smooth, hyperechoic horizontal line that moves synchronously with respiration. This line
22 is called *pleural line* and its movement is the *lung sliding*, providing visual assessment of lung excursion
23 during ventilation. The sonographic pattern of the aerated lung also includes parallel, hyperechoic,
24 horizontal lines that can be seen at regular intervals from the pleural line (*A-lines*, Figure 1, Video 1) (7).
25 When the air content in the lung decreases and lung density increases, vertical reverberation artifacts
26 appear (*B-lines*, Figure 2, Video 2). B-lines originate from the pleural line and move synchronously with
27 respiration, are laser-like in shape and extend towards the bottom of the US sector as displayed on the
28 screen (8). B-lines are present in patients with HF and pulmonary oedema (9) where an increasing
29 number of visualized B-lines is associated with a decreasing air/water content ratio (10–12).

30 B-lines are not specific for cardiogenic pulmonary oedema and can be detected in patients with
31 non-cardiogenic pulmonary oedema, including those with end stage renal disease and in ALI/ARDS
32 (13), but also in pulmonary fibrosis (interstitial lung disease) (14) and interstitial pneumonia. Certain
33 sonographic characteristics can help differentiate these various causes of B-lines (5) (Table 1).

34 Pleural effusion can be easily detected by LUS, placing the phased array transducer on the
35 surface of the chest wall in an intercostal space, and is displayed as an anechoic space above the

1 diaphragm. Pleural effusion is advised to be sought at first in the dependent zones, i.e. lateral and
2 posterior chest wall (e.g. posterior axillary line) at the level of costophrenic angles (Figure 3, Video 3),
3 which also allows other causes of chest X-ray radio-opacity, such as consolidation, mass, or an elevated
4 hemidiaphragm to be ruled out (Figure 4, Video 4). LUS is more sensitive than chest X-ray in detecting
5 pleural effusions, when using computed tomography (CT) as the reference standard (15,16), and can
6 determine the volume of pleural effusion and monitor its evolution. LUS can also provide information on
7 its likely nature by differentiating between simple and complex effusions, and can help guide the optimal
8 site for needle thoracentesis.

9 10 Other sonographic features of congestion

11 The pathophysiology of congestion in HF includes the different stages of hemodynamic,
12 pulmonary and systemic congestion (17), that can be all assessed by ultrasound. Traditional
13 echocardiography provides indicators of hemodynamic congestion, including a dilated left atrium, a high
14 E/e' , elevated pulmonary artery systolic pressure, and dilated inferior vena cava (IVC). B-lines on LUS
15 are a sign of pulmonary congestion (increased extravascular lung water) due to left sided HF,
16 independent of - yet closely related with hemodynamic congestion. Chronically elevated left-sided filling
17 pressures eventually result in a rise in right atrial pressures and IVC distension. An IVC smaller than 21
18 mm that collapses $>50\%$ during inspiration suggests normal right atrial pressures (18), although this
19 measurement should be interpreted in the context of the overall patient's underlying pathophysiological
20 and hemodynamic status and integrated with other echocardiographic findings; an increased IVC
21 diameter can identify intravascular volume expansion prior to changes in symptoms or body weight, and
22 predicts a high risk of rehospitalization for HF or death in patients with acute or chronic HF (19,20).

23 Using a high-frequency linear transducer, the internal jugular vein (IJV) diameter can be
24 measured. When congestion is severe, IJV distensibility, provoked by Valsalva manoeuvre, is markedly
25 reduced, indicating a poor prognosis (21). Congestion in other organs can be also assessed by
26 ultrasound, such as the kidneys. A comprehensive review of these novel techniques and their potential
27 clinical utility can be found elsewhere (22). Recently, the VExUS score (venous excess ultrasound),
28 including Doppler evaluation of the IVC, hepatic veins, portal vein, and renal venous flow has been
29 proposed to assess presence and severity of venous congestion (23). Whereas systemic venous
30 congestion (as assessed by IVC, IJV, hepatic veins, portal veins, renal veins) can be present in both
31 right and left-sided HF, LUS B-lines indicate pulmonary congestion due to left-sided HF.

32 33 Other sonographic features of deaeration

34 When the pulmonary air content is completely dissipated in areas of pulmonary consolidation (a
35 potential precipitant of acute HF), the lung parenchyma can be directly visualized (Figure 5, Video 5)

1 with a hypoechoic or tissue-like pattern. Different aetiologies of consolidations may have also different
2 sonographic appearance (Figure 5). Compression atelectasis is frequent in patients with HF; here, a
3 large cardiogenic pleural effusion causes direct compression of the pulmonary parenchyma (4).

4 On occasion, a focal interstitial syndrome (i.e. multiple B-lines localized only in a single area of
5 the chest 'zone') can suggest pneumonia. These are thought to represent either the very early phases
6 of pneumonia with the partial deaeration LUS pattern (B-lines) preceding the total deaeration LUS
7 pattern (consolidation), or the focal oedema surrounding any consolidation.

9 **Lung ultrasound in heart failure: the technique**

10 Whenever possible, it is advised to perform LUS exams with a standardized approach, to facilitate
11 interpretation and monitoring, as well as reproducibility (24). Several LUS protocols have been
12 described, with a variable number of examination areas of the chest (zones) to be examined, ranging
13 from 4 to 28 (25–27) (Figure 6). Currently, the 8-zone scanning protocol is the most widely used,
14 balancing the need for a simplified, rapid protocol, and good accuracy; (8) with studies suggesting it
15 the most appropriate approach across multiple settings, including the diagnosis of HF (with the 8-zone
16 C-index non-inferior to the 28-zone C-index) (28), and for risk stratification (29).

17 When integrating LUS during stress echocardiography, a simplified 4-zone scanning protocol is
18 often used, placing the probe at the third intercostal space along the anterior axillary and mid-axillary
19 lines (30,31).

20 In adult patients, both phased-array or convex transducers are sufficient to assess B-lines. If
21 available, the abdominal preset (for the convex transducer) and the cardiac preset (for the phased-array
22 transducer) usually provide adequate image quality. Some machines have also a dedicated lung preset.
23 The transducer should be placed in the intercostal space either perpendicular (longitudinal, sagittal) or
24 in parallel orientation (transverse) to the ribs. Imaging depth depends on the size of the patient, but is
25 usually set at ~15–18 cm (22). Once the transducer position and gain settings are optimised for
26 visualization of the pleural line and B-lines, it is advised to keep the transducer in the same location for
27 at least one respiratory cycle. When a movie clip is recorded, the suggested length is of about 6 seconds
28 (32,33). In each chest zone, the operator should scan all accessible chest surface to increase sensitivity.

29 During the examination, patients can be positioned either sitting upright, semi-recumbent or
30 supine; however, it is preferred to scan patients should be scanned in the same position if serial
31 examinations are being performed (34). In those thoracic zones where a pleural effusion is visualized,
32 B-lines cannot be assessed, and the presence of pleural effusion should be described in the LUS report
33 instead.

34 There are two main approaches to quantify B-lines: score- or count-based methods. Score-
35 based methods consider a minimum number of B-lines in one thoracic zone as a 'positive' zone (typically

1 at least 3 B-lines) (8), then the number of positive zones are added up (25). Count-based methods entail
2 that B-lines are counted to obtain a number for each thoracic zone: B-lines can be counted one by one
3 (27,34) or, when confluent and overlapping, their number can be estimated from the percentage of
4 space they occupy on the screen below the pleural line, divided by 10 (i.e. if about 60% of the screen
5 below the pleural line is occupied by B-lines, it would conventionally count as 6 B-lines, up to a maximum
6 of 10 per zone) (Figure 7). It is advised to count B-lines in the worst (less aerated/with more B-lines)
7 point of each thoracic zone, then the number of B-lines in each zone can be summed up to obtain a
8 total B-line count (4,8,35,36). All these methods have demonstrated good intra- and inter-observer
9 agreement (37,38). A schematic overview of LUS approach in patients with suspected or established
10 HF is shown in Table 2.

11 **Key points: To evaluate pulmonary congestion in patients with suspected or established**
12 **HF, using a phased-array or convex probe may be appropriate (including handheld ultrasound**
13 **devices), in sagittal or transverse orientations (transducer perpendicular or parallel to the**
14 **intercostal space), ideally following the 8-zone protocol and maintaining the patient in the same**
15 **position during serial examinations.**

16 **Clinical applications**

17 Acute heart failure

18 *Diagnosis: Ruling in/out acute cardiogenic dyspnoea*

19 The typical LUS pattern of a patient with acute HF and pulmonary oedema is the presence of
20 *multiple* (at least 3 B-lines in one chest zone), *diffuse* (at least two positive zones per hemithorax) and
21 *bilateral* B-lines. It is important to distinguish this pattern from the presence of a few patchy B-lines,
22 especially when located at the lung bases, that can be seen even in healthy subjects, and which
23 therefore do not qualify as *multiple*, *diffuse* and *bilateral*.

24 LUS is a rapid diagnostic test, which takes less than 5 minutes. Among patients hospitalized
25 with acute dyspnoea, LUS has demonstrated high diagnostic accuracy for acute HF, with a sensitivity
26 of 94-97% and a specificity of 97% (25,26) that has been shown to be superior to both clinical
27 assessment (i.e. history, physical examination, electrocardiogram, and arterial blood gas) and the chest
28 X-ray, even when there is superimposed pneumonia (25,39,40). Indeed, LUS is superior to chest X-ray
29 alone (sensitivity of 91.8% vs. 76.5% and a specificity of 92.3% vs. 87.0%) (41), and has higher accuracy
30 than clinical assessment even when integrated with “traditional” diagnostic test (i.e. natriuretic peptides
31 and chest X-ray) to diagnose acute HF (25,26).

32 *Monitoring: Assessing decongestion*

33

34

1 A higher number of B-lines on admission for an episode of acute HF is associated with greater
2 risk, regardless of left ventricular ejection fraction (LVEF) and presence of HF signs and symptoms (42).
3 This suggests that B-lines might be a potential target for treatment but also useful to monitor response
4 to decongestive therapies.

5 Changes in B-lines are very dynamic and, for those who respond to diuretic therapy and other
6 treatments, the number of B-lines decreases rapidly (27,43,44), regardless of the aetiology of acute HF
7 (45). Serial LUS can guide titration of diuretic therapy, leading to more rapid relief of congestion and,
8 potentially, shortening the length of hospital stay (46–48). Resolution of pulmonary congestion detected
9 by ultrasound during HF hospitalisation is associated with improved survival (combined endpoint of 6
10 month all-cause death or AHF re-hospitalization) (48,49). However, at the moment, there is no evidence
11 that titrating diuretic therapy based on B-lines can improve morbidity and mortality in patients
12 hospitalized with HF (47).

13 Although pleural effusions are typically monitored by chest X-ray in patients with acute HF, serial
14 ultrasound scans are also effective in quantifying changes in the size of pleural effusion associated with
15 decongestive therapy without exposing patients to radiation (50).

16 17 *Prognosis: Determining the timing of discharge*

18 Up to 45% of patients hospitalized with acute HF are either readmitted for HF or die within 12
19 months of discharge (51). Those with a higher degree of residual congestion, including pulmonary
20 congestion, at the time of discharge, are at particularly high risk (51,52). The importance of optimizing
21 decongestion during a HF hospitalisation is consequently highlighted in the 2021 ESC Guidelines (6).
22 Patients with a high number of B-lines at discharge are at higher risk of readmission or premature death
23 than those discharged without or with only mild pulmonary congestion (36,53–56). Prior studies
24 investigating the prevalence and prognostic value of B-lines at discharge in patients hospitalized with
25 HF have employed 4, 8 or 28-zone LUS protocols; specific cut-off values for these protocols are
26 summarized in Table 3. Collectively, these findings suggest that LUS may detect subclinical pulmonary
27 congestion pre-discharge in patients with acute HF, irrespective of ejection fraction, and identify those
28 at greater risk for subsequent adverse outcomes. In addition to B-lines, pleural effusions can be detected
29 with ultrasound in approximately half of the patients discharged after an acute HF episode (27), but it
30 is unclear whether this finding is associated with an increased risk of cardiovascular events post-
31 discharge (57).

32 **Key points: The LUS pattern of pulmonary oedema in acute left- sided HF consists of the**
33 **presence of multiple (at least 3 B-lines), diffuse (in at least 2 zones per hemithorax), bilateral B-**
34 **lines. Using LUS may be appropriate in patients with acute dyspnoea to rule-in or rule-out**
35 **pulmonary oedema in suspected acute left-sided HF. Using LUS may be appropriate to detect**

1 **persistent pulmonary congestion prior to discharge in patients hospitalized with acute HF, to**
2 **identify those at higher risk of readmission for HF or death.**

3
4 Chronic heart failure

5 *During follow-up: guidance of diuretic therapy*

6 The 2021 ESC Guidelines do not recommend serial echocardiography or assessment of B-lines
7 in ambulatory patients with HF unless clinical deterioration is suspected. Indeed, many of those with HF
8 who attend routine clinical appointments usually feel well, do not report any symptoms and are free of
9 congestion at clinical examination (58). However, decompensation is clinically silent in most patients
10 and is often only recognized late, at a point when congestion demands urgent action. Thus, LUS could
11 potentially be implemented in the routine clinical evaluation of outpatients, to facilitate early detection of
12 subclinical congestion. In a single-centre, single-blind, randomized clinical trial, a LUS-guided strategy
13 significantly improved the combined endpoint of urgent visit, re-hospitalisation and death at 6 months
14 after an acute HF episode (59). Subsequently, the CLUSTER-HF trial also showed that LUS-guided
15 treatment was associated with a 45% risk reduction in the primary end point (a composite of urgent HF
16 visits, rehospitalization for worsening HF, and death from any cause), mainly driven by a reduction in
17 urgent HF visits (60). Another trial that randomised outpatients with chronic HF, demonstrated a
18 substantial reduction in hospitalizations for acute HF (by 56% at 90 days), as well as decreasing NT-
19 proBNP concentrations and improving quality-of-life in those patients whose treatment was guided by
20 LUS (61). A summary of the clinical utility of LUS in acute and chronic heart failure is shown in Table 4.

21 **Key points: Integrating LUS into the routine evaluation of ambulatory patients with HF**
22 **may be appropriate, to titrate diuretic therapy and reduce HF-related adverse outcomes, in**
23 **particular the need for urgent visits.**

24
25 *During stress echocardiography*

26 LUS can be easily performed during exercise testing, including stress echocardiography (31,62,63).
27 The number of B-lines increases during exercise in patients with HF more than in control subjects
28 (64,65). In patients with HFrEF, peak B-lines are closely associated with resting NT-proBNP, peak VO_2 ,
29 and stress PASP (62). In patients with heart failure with preserved ejection fraction (HFpEF), the
30 development of pulmonary congestion as measured by B-lines upon exercise correlates with exercise-
31 induced worsening of diastolic function (particularly with peak E/e' and global strain rate during late
32 diastole) (66). Hemodynamic studies further suggest that the acute development of pulmonary
33 congestion during stress is related to an increase in pulmonary capillary hydrostatic pressure and
34 systemic venous hypertension (67). Therefore, LUS during exercise can quantify the pulmonary
35 congestion secondary to the raise in stress-induced intracardiac/pulmonary pressures.

1 Detecting a higher number of B-lines at peak exercise is associated with a greater risk of HF
2 hospitalization and death in patients with both HFrEF (62) and HFpEF. Overall, these findings suggest
3 that LUS may complement standard exercise testing to improve HF diagnosis and risk stratification
4 (68,69).

5
6 In patients with chest pain and acute myocardial infarction

7 Patients with acute coronary syndrome may develop pulmonary congestion, especially during or
8 soon after an ST-elevation myocardial infarction (STEMI). A recent systematic review suggests that a
9 high number of B-lines is a common finding in patients hospitalized with an acute coronary syndrome
10 and identifies patients more likely to have adverse in-hospital and long-term outcomes (70). Whether
11 assessment of B-lines might guide use of therapies that reduce pulmonary congestion after a myocardial
12 infarction and improve morbidity and mortality in the short and long term, remains to be determined.

13
14 In patients with shock/hypotension

15 LUS can provide vital information when integrated with echocardiography in the assessment of
16 hypotension and various types of shock, with the potential of detecting the underlying cause, and
17 improving the quality of care delivered to critically ill patients.

18 In hypovolaemic shock, the presence of a normal LUS pattern confirms the presence of 'dry'
19 lungs which has a very high negative predictive value in ruling out a cardiogenic cause of hypotension
20 (71,72) (Figure 8). Patients in cardiogenic shock due to LV failure or mitral/aortic valvular heart disease,
21 eventually develop pulmonary congestion which would appear by LUS as multiple, diffuse bilateral B-
22 lines, associated with a regular pleural line (13) (Figure 8).

23 In patients with a pneumothorax, LUS has superior diagnostic sensitivity (88% vs. 52%) and
24 similar specificity (99% vs. 100%) to chest X-ray (73). The combination of the absence of lung sliding
25 (generating the barcode sign on M-mode), absence of B-lines, and the presence of a lung point (the
26 transition point between a LUS pattern with lung sliding and without lung sliding) would suggest a
27 pneumothorax as the cause of hypotension/shock (Figure 8) (8). The visualization of a normal LUS
28 pattern along with non-compressible peripheral deep veins due to a thrombus would suggest pulmonary
29 embolism, especially when coupled with RV dilatation and dysfunction (74). Moreover,
30 triangular/polygonal hypoechoic peripheral consolidations with sharp margins may be detected, as
31 the sonographic appearance of pulmonary infarctions (Figure 8) (75).

32 In septic shock, the lungs are a frequent source of sepsis, due to lobar pneumonia which can be
33 diagnosed with LUS with high sensitivity, through the visualization of consolidations often with dynamic
34 air bronchograms, commonly at the most dependant zones of the lungs, with or without adjacent pleural
35 effusion. The presence of punctiform echoes within an otherwise anechogenic pleural effusion could

1 indicate exudative pleural effusion/empyema (76). The lungs can develop B-lines due to ARDS because
2 of septic shock of extrapulmonary origin. LUS can be very useful in monitoring areation/deareation,
3 assessing disease progression and recruitment in ALI/ARDS (including COVID-19 pneumonia) (77).
4 LUS can be performed also during transoesophageal echocardiography through dedicated views of the
5 posterior regions of the lungs where lung consolidations and pleural effusions are most often seen, with
6 promising preliminary results (78).

7 **Key points: In patients with shock/hypotension, LUS can complement the standard**
8 **clinical evaluation to improve diagnostic accuracy.**

9

10 **Integrated cardiopulmonary ultrasound**

11 How to integrate echocardiography and lung ultrasound

12 Transthoracic echocardiography is guidelines-recommended as a key investigation in HF (6) for
13 the assessment of cardiac structure and function, defining HF phenotype based on LVEF measurement,
14 as well identifying potential underlying aetiologies and mechanisms, and guiding the introduction of
15 treatment. The 2021 ESC Guidelines also mention the use of LUS in acute settings to confirm a
16 diagnosis of HF, especially when natriuretic peptide testing is not available (6), since pulmonary
17 congestion is one of the main causes of hospital admission in patients with HF (17).

18 Integrating cardiac and pulmonary assessments on ultrasound can help understand and identify
19 earlier the pulmonary consequences of structural or functional cardiac pathology, and potentially
20 individualise patient management. Real-time interpretation of B-lines, together with the non-invasive
21 hemodynamic signs that can be measured by echocardiography, can provide simultaneous
22 assessments of the cardiac and pulmonary situation, leading to more accurate diagnosis and earlier
23 treatment initiation (79,80). The number of B-lines is related to invasive left ventricular end-diastolic
24 pressure (LVEDP) measurements (81), to E/e' (82), to tricuspid regurgitation velocity (42), to right
25 ventricular (RV) function and RV–pulmonary artery coupling (83). However, in patients with the same
26 hemodynamic profile, the degree of pulmonary congestion as detected by B-lines can vary markedly.
27 Therefore, echocardiography is useful to understand the aetiology of HF, whereas LUS B-lines are
28 especially useful to detect the degree of pulmonary congestion. The routine assessment of B-lines may
29 be particularly appropriate when either a high-end ultrasound machine or the expertise for more complex
30 echocardiographic analyses is not readily available or when cardiac image quality is poor and initial
31 diagnosis difficult. Therefore, whenever possible, these two aspects of the patient's compensation status
32 – hemodynamic congestion and pulmonary congestion - (17) can be evaluated in an integrated
33 ultrasound cardiopulmonary examination (Table 5). This approach can also provide concomitant
34 information regarding perfusion (by the LV outflow tract time-velocity integral as a non-invasive index of
35 cardiac output) and pulmonary congestion (by B-lines), in a less invasive way compared to right heart

1 catheterization. The integration of B-lines with IVC is also valuable and integrates different information,
2 since IVC diameter and collapsibility index is a proxy for right atrial pressure, but also reflects
3 intravascular volume status, whereas B-lines reflect extravascular lung water, which can be present in
4 patients with either a normal or a dilated IVC (19).

5 **Key points: When evaluating patients with known or suspected HF, it is advised to**
6 **integrate LUS B-lines in the echocardiographic assessment to provide information about the**
7 **degree of pulmonary congestion, in both acute and chronic settings.**

8 9 Lung ultrasound in FoCUS

10 Focus cardiac ultrasound (FoCUS) is a point-of-care cardiac ultrasound examination performed
11 according to a standardized, but restricted, scanning protocol in patients presenting with circulatory or
12 respiratory compromise, chest pain or trauma, dyspnoea, syncope or cardiac arrest (84). The FoCUS
13 scanning protocol comprises five echocardiographic views sufficient for crude assessment of left and
14 right ventricular size and function, pericardial effusion, and intravascular volume status.

15 Since cardiovascular and pulmonary diseases frequently coexist and may share clinical
16 presentations, LUS may help in the differential diagnosis of acute dyspnoea and hemodynamic
17 instability and is therefore an integral part of the FoCUS examination (84). The presence of multiple,
18 diffuse, bilateral B-lines in a dyspnoeic patient with LV dysfunction is almost unequivocally consistent
19 with HFrEF. In the presence of left atrial dilation and/or visually-detected LV hypertrophy, multiple,
20 diffuse, bilateral B-lines may indicate HFpEF, and natriuretic peptide measurement and a
21 comprehensive echocardiography should be ordered for further evaluation (84). Figure 8 summarizes
22 the main situations of respiratory and circulatory failure, where LUS integrated with FoCUS can be of
23 particular value.

24 **Key points: Whenever possible, it is advised to integrate assessment of B-lines and**
25 **pleural effusion into the FoCUS examination since it may help in the differential diagnosis of**
26 **acute dyspnoea and hemodynamic instability.**

27 28 **Pitfalls**

29 As with every diagnostic technique, there are some limitations with LUS examinations, which
30 should be acknowledged to master this tool. There are still uncertainties about the exact physical origin
31 of B-lines (11), although they are clearly related to a partial deaeration of the pulmonary parenchyma.
32 LUS is an easy to learn ultrasound technique, with a short learning curve that can be limited to about 20
33 exams (85,86), but some training is needed to ensure reproducibility and the correct interpretation of
34 findings. Initiatives that would ensure quality standards and safe patient care, for instance an LUS
35 certification program, could facilitate the standardisation of this procedure for both clinicians and other

1 healthcare professionals involved in the care of patients with HF, who can successfully assess B-lines
2 (87,88). B-lines are artifacts: although no clinically significant differences have been reported by using
3 different machines and settings, attention should be paid to avoid magnification or deletion of artefactual
4 images. Different LUS scanning protocols have been proposed and used, in research and in clinical
5 practice, as previously discussed.

6 Probably, the main pitfall is the clinical interpretation of B-lines in the absence of an established
7 diagnosis. B-lines are not specific for cardiogenic pulmonary oedema: being a sign of partial pulmonary
8 deaeration, they can be present in patients with interstitial lung disease, such as pulmonary fibrosis, as
9 well as ALI/ARDS, and interstitial pneumonia (including COVID-19 pneumonia). As highlighted in Table
10 1, there are some LUS features that can help differentiate these conditions, taking into account that a
11 strong integration with clinical and other routine diagnostic findings is mandatory. This point further
12 reinforces the need for LUS training, to ensure that healthcare providers will not categorize every patient
13 with B-lines as having HF.

14 Importantly, the absence of substantial pulmonary congestion on ultrasound does not exclude
15 HF, particularly in the context of severe obesity or isolated right-sided HF; therefore, clinicians should
16 not forget to evaluate systemic/venous congestion (89).

17 18 **Gaps in current evidence**

19 In recent years major advances have been made in our understanding of the utility of LUS as an
20 imaging tool in the diagnosis, monitoring and risk stratification of patients with HF, but areas with lack
21 of evidence remain. Table 6 lists selected topics that deserve to be addressed in future clinical research.

22 Whilst waiting for additional evidence regarding the clinical utility of LUS, especially in titrating
23 diuretic therapy, we already have solid data supporting the use of this tool in daily clinical practice to
24 complement either FoCUS or comprehensive echocardiography in the assessment and management
25 of patients with HF.

26 27 **Conclusions**

28 LUS is an easy to learn, rapid and versatile point-of-care diagnostic method. B-lines on LUS are
29 the sonographic sign of a partially deaerated lung, that can be detected in patients with HF, providing a
30 semiquantitative evaluation of pulmonary interstitial oedema.

31 Sonographic B-lines are useful for the diagnosis, monitoring and prognostic assessment of
32 patients with HF. Therefore, it would be useful too integrate routine evaluation of B-lines and pleural
33 effusions into standard transthoracic echocardiographic protocols in patients with suspected or
34 confirmed HF, as well as in the FoCUS examination. This integrated cardiopulmonary ultrasound

- 1 5. Gargani L. Lung ultrasound: a new tool for the cardiologist. *Cardiovascular ultrasound*. 2011;9:6.
- 2 6. McDonagh TA, Metra M, Adamo M, Gardner RS, Baumbach A, Böhm M, et al. 2021 ESC
3 Guidelines for the diagnosis and treatment of acute and chronic heart failure. *European heart*
4 *journal*. 2021 Sep;42(36):3599–726.
- 5 7. Gargani L, Volpicelli G. How I do it: Lung ultrasound. *Cardiovascular ultrasound*. 2014;12(1):1–10.
- 6 8. Volpicelli G, Elbarbary M, Blaivas M, Lichtenstein DA, Mathis G, Kirkpatrick AW, et al. International
7 evidence-based recommendations for point-of-care lung ultrasound. *Intensive care medicine*. 2012
8 Apr;38(4):577–91.
- 9 9. Lichtenstein D, Mezière G, Biderman P, Gepner A, Barré O. The comet-tail artifact. An ultrasound
10 sign of alveolar-interstitial syndrome. *American journal of respiratory and critical care medicine*.
11 1997 Nov;156(5):1640–6.
- 12 10. Jambrik Z, Gargani L, Adamicza Á, Kaszaki J, Varga A, Forster T, et al. B-lines quantify the lung
13 water content: A lung ultrasound versus lung gravimetry study in acute lung injury. *Ultrasound in*
14 *Medicine and Biology*. 2010;36(12).
- 15 11. Soldati G, Inchingolo R, Smargiassi A, Sher S, Nenna R, Inchingolo CD, et al. Ex Vivo Lung
16 Sonography: Morphologic-Ultrasound Relationship. *Ultrasound in Medicine and Biology*.
17 2012;38:1169–79.
- 18 12. Gargani L, Lionetti V, Di Cristofano C, Bevilacqua G, Recchia FA, Picano E. Early detection of
19 acute lung injury uncoupled to hypoxemia in pigs using ultrasound lung comets. *Critical Care*
20 *Medicine*. 2007;35(12).
- 21 13. Copetti R, Soldati G, Copetti P. Chest sonography: a useful tool to differentiate acute cardiogenic
22 pulmonary edema from acute respiratory distress syndrome. *Cardiovascular ultrasound*. 2008
23 Jan;6:16.
- 24 14. Gargani L, Bruni C, Romei C, Frumento P, Moreo A, Agoston G, et al. Prognostic Value of Lung
25 Ultrasound B-Lines in Systemic Sclerosis. *Chest*. 2020 Oct;158(4):1515–25.
- 26 15. Balik M, Plasil P, Waldauf P, Pazout J, Fric M, Otahal M, et al. Ultrasound estimation of volume of
27 pleural fluid in mechanically ventilated patients. *Intensive care medicine*. 2006 Feb;32(2):318–21.
- 28 16. Roch A, Bojan M, Michelet P, Romain F, Bregeon F, Papazian L, et al. Usefulness of
29 ultrasonography in predicting pleural effusions > 500 mL in patients receiving mechanical
30 ventilation. *Chest*. 2005 Jan;127(1):224–32.
- 31 17. Gheorghiade M, Follath F, Ponikowski P, Barsuk JH, Blair JE a, Cleland JG, et al. Assessing and
32 grading congestion in acute heart failure: A scientific statement from the acute heart failure
33 committee of the heart failure association of the European society of cardiology and endorsed by
34 the European society of intensive care medicine. *European Journal of Heart Failure*. 2010;12:423–
35 33.
- 36 18. Rudski LG, Lai WW, Afilalo J, Hua L, Handschumacher MD, Chandrasekaran K, et al. Guidelines
37 for the echocardiographic assessment of the right heart in adults: a report from the American
38 Society of Echocardiography endorsed by the European Association of Echocardiography, a
39 registered branch of the European Society of Cardiology, and t. *J Am Soc Echocardiogr*.
40 2010;23:685–713.

- 1 19. Pellicori P, Carubelli V, Zhang J, Castiello T, Sherwi N, Clark AL, et al. IVC diameter in patients
2 with chronic heart failure: relationships and prognostic significance. *JACC Cardiovascular*
3 *imaging*. 2013 Jan;6(1):16–28.
- 4 20. Pellicori P, Shah P, Cuthbert J, Urbinati A, Zhang J, Kallvikbacka-Bennett A, et al. Prevalence,
5 pattern and clinical relevance of ultrasound indices of congestion in outpatients with heart failure.
6 *European journal of heart failure*. 2019 Jul;21(7):904–16.
- 7 21. Pellicori P, Kallvikbacka-Bennett A, Dierckx R, Zhang J, Putzu P, Cuthbert J, et al. Prognostic
8 significance of ultrasound-assessed jugular vein distensibility in heart failure. *Heart*. 2015 Jul
9 15;101(14):1149.
- 10 22. Pellicori P, Platz E, Dauw J, Ter Maaten JM, Martens P, Pivetta E, et al. Ultrasound imaging of
11 congestion in heart failure: examinations beyond the heart. *Eur J Heart Fail*. 2021 May;23(5):703–
12 12.
- 13 23. Beaubien-Souligny W, Rola P, Haycock K, Bouchard J, Lamarche Y, Spiegel R, et al. Quantifying
14 systemic congestion with Point-Of-Care ultrasound: development of the venous excess ultrasound
15 grading system. *Ultrasound J*. 2020 Apr 9;12(1):16.
- 16 24. Platz E, Jhund PS, Girerd N, Pivetta E, McMurray JJ V, Peacock WF, et al. Expert consensus
17 document: Reporting checklist for quantification of pulmonary congestion by lung ultrasound in
18 heart failure. *European journal of heart failure*. 2019 Jul;21(7):844–51.
- 19 25. Pivetta E, Goffi A, Lupia E, Tizzani M, Porrino G, Ferreri E, et al. Lung ultrasound-implemented
20 diagnosis of acute decompensated heart failure in the emergency department - a simeu
21 multicenter study. *Chest*. 2015;148(1).
- 22 26. Pivetta E, Goffi A, Nazerian P, Castagno D, Tozzetti C, Tizzani P, et al. Lung ultrasound integrated
23 with clinical assessment for the diagnosis of acute decompensated heart failure in the emergency
24 department: a randomized controlled trial. *European journal of heart failure*. 2019 Jun;21(6):754–
25 66.
- 26 27. Platz E, Campbell RT, Claggett B, Lewis EF, Groarke JD, Docherty KF, et al. Lung Ultrasound in
27 Acute Heart Failure: Prevalence of Pulmonary Congestion and Short- and Long-Term Outcomes.
28 *JACC Heart failure*. 2019 Oct;7(10):849–58.
- 29 28. Buessler A, Chouihed T, Duarte K, Bassand A, Huot-Marchand M, Gottwalles Y, et al. Accuracy of
30 Several Lung Ultrasound Methods for the Diagnosis of Acute Heart Failure in the ED: A
31 Multicenter Prospective Study. *Chest*. 2020 Jan;157(1):99–110.
- 32 29. Rastogi T, Bozec E, Pellicori P, Bayes-Genis A, Coiro S, Domingo M, et al. Prognostic Value and
33 Therapeutic Utility of Lung Ultrasound in Acute and Chronic Heart Failure: A Meta-Analysis. *JACC*
34 *Cardiovasc Imaging*. 2022 May;15(5):950–2.
- 35 30. Scali MC, Zagatina A, Simova I, Zhuravskaya N, Ciampi Q, Paterni M, et al. B-lines with Lung
36 Ultrasound: The Optimal Scan Technique at Rest and During Stress. *Ultrasound in Medicine and*
37 *Biology*. 2017 Nov 1;43(11):2558–66.
- 38 31. Merli E, Ciampi Q, Scali MC, Zagatina A, Merlo PM, Arbucci R, et al. Pulmonary Congestion
39 During Exercise Stress Echocardiography in Ischemic and Heart Failure Patients. *Circulation:*
40 *Cardiovascular Imaging*. 2022 May 1;15(5):e013558.

- 1 32. Pivetta E, Baldassa F, Masellis S, Bovaro F, Lupia E, Maule MM. Sources of Variability in the
2 Detection of B-Lines, Using Lung Ultrasound. *Ultrasound in medicine & biology*. 2018
3 Jun;44(6):1212–6.
- 4 33. Platz E, Pivetta E, Merz AA, Peck J, Rivero J, Cheng S. Impact of device selection and clip
5 duration on lung ultrasound assessment in patients with heart failure. *The American journal of*
6 *emergency medicine*. 2015 Nov;33(11):1552–6.
- 7 34. Frasure SE, Matilsky DK, Siadecki SD, Platz E, Saul T, Lewiss RE. Impact of patient positioning
8 on lung ultrasound findings in acute heart failure. *European heart journal Acute cardiovascular*
9 *care*. 2015 Aug;4(4):326–32.
- 10 35. Coiro S, Rossignol P, Ambrosio G, Carluccio E, Alunni G, Murrone A, et al. Prognostic value of
11 residual pulmonary congestion at discharge assessed by lung ultrasound imaging in heart failure.
12 *European Journal of Heart Failure*. 2015;17(11):1172–81.
- 13 36. Gargani L, Pang PSS, Frassi F, Miglioranza MH, Dini FLL, Landi P, et al. Persistent pulmonary
14 congestion before discharge predicts rehospitalization in heart failure: a lung ultrasound study.
15 *Cardiovascular Ultrasound*. 2015;13(1):40.
- 16 37. Jambrik Z, Monti S, Coppola V, Agricola E, Mottola G, Miniati M, et al. Usefulness of ultrasound
17 lung comets as a nonradiologic sign of extravascular lung water. *The American Journal of*
18 *Cardiology*. 2004 May 15;93(10):1265–70.
- 19 38. Gargani L, Sicari R, Raciti M, Serasini L, Passera M, Torino C, et al. Efficacy of a remote web-
20 based lung ultrasound training for nephrologists and cardiologists: a LUST trial sub-project.
21 *Nephrology Dialysis Transplantation*. 2016;31(12):gfw329.
- 22 39. Cibinel GA, Casoli G, Elia F, Padoan M, Pivetta E, Lupia E, et al. Diagnostic accuracy and
23 reproducibility of pleural and lung ultrasound in discriminating cardiogenic causes of acute
24 dyspnea in the Emergency Department. *Internal and Emergency Medicine*. 2012;7:65–70.
- 25 40. Mazzola M, Pugliese NR, Zavagli M, De Biase N, Bandini G, Barbarisi G, et al. Diagnostic and
26 Prognostic Value of Lung Ultrasound B-Lines in Acute Heart Failure With Concomitant
27 Pneumonia. *Front Cardiovasc Med*. 2021;8:693912.
- 28 41. Chiu L, Jairam MP, Chow R, Chiu N, Shen M, Alhassan A, et al. Meta-Analysis of Point-of-Care
29 Lung Ultrasonography Versus Chest Radiography in Adults With Symptoms of Acute
30 Decompensated Heart Failure. *Am J Cardiol*. 2022 Jul 1;174:89–95.
- 31 42. Gargani L, Pugliese NR, Frassi F, Frumento P, Poggianti E, Mazzola M, et al. Prognostic value of
32 lung ultrasound in patients hospitalized for heart disease irrespective of symptoms and ejection
33 fraction. *ESC Heart Fail*. 2021 Aug;8(4):2660–9.
- 34 43. Volpicelli G, Caramello V, Cardinale L, Mussa A, Bar F, Frascisco MF. Bedside ultrasound of the
35 lung for the monitoring of acute decompensated heart failure. *The American journal of emergency*
36 *medicine*. 2008 Jun;26(5):585–91.
- 37 44. Cortellaro F, Ceriani E, Spinelli M, Campanella C, Bossi I, Coen D, et al. Lung ultrasound for
38 monitoring cardiogenic pulmonary edema. *Internal and Emergency Medicine*. 2016;1–7.
- 39 45. Martindale JL, Secko M, Kilpatrick JF, Ian S, Paladino L, Aherne A, et al. Serial Sonographic
40 Assessment of Pulmonary Edema in Patients With Hypertensive Acute Heart Failure. 2017;

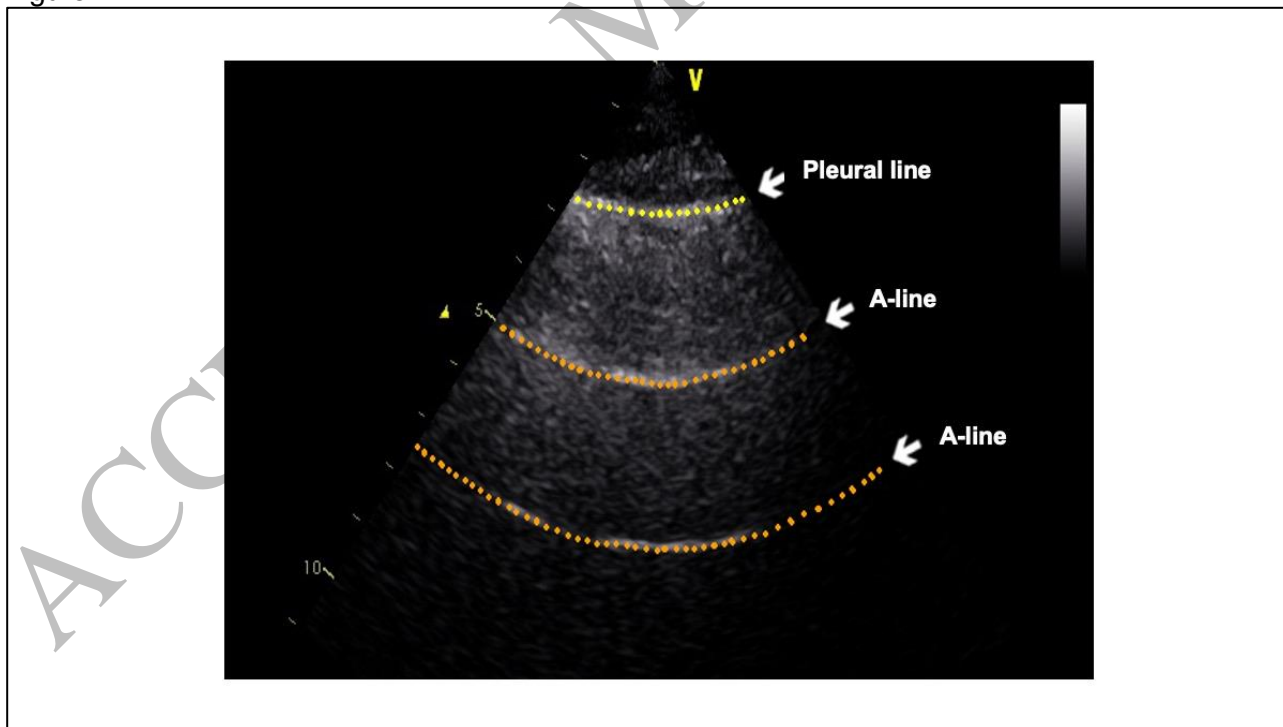
- 1 46. Mozzini C, Di M, Perna D, Pesce G, Garbin U, Meschi T, et al. Lung ultrasound in internal
2 medicine efficiently drives the management of patients with heart failure and speeds up the
3 discharge time Inferior Cave Vein Collapsibility index. *Internal and Emergency Medicine*. 2017;
- 4 47. Pang PS, Russell FM, Ehrman R, Ferre R, Gargani L, Levy PD, et al. Lung Ultrasound-Guided
5 Emergency Department Management of Acute Heart Failure (BLUSHED-AHF): A Randomized
6 Controlled Pilot Trial. *JACC Heart failure*. 2021 Sep;9(9):638–48.
- 7 48. Öhman J, Harjola VP, Karjalainen P, Lassus J. Focused echocardiography and lung ultrasound
8 protocol for guiding treatment in acute heart failure. *ESC heart failure*. 2018 Feb;5(1):120–8.
- 9 49. Öhman J, Harjola VP, Karjalainen P, Lassus J. Assessment of early treatment response by rapid
10 cardiothoracic ultrasound in acute heart failure: Cardiac filling pressures, pulmonary congestion
11 and mortality. *European heart journal Acute cardiovascular care*. 2018 Jun;7(4):311–20.
- 12 50. Brogi E, Gargani L, Bignami E, Barbariol F, Marra A, Forfori F, et al. Thoracic ultrasound for
13 pleural effusion in the intensive care unit: A narrative review from diagnosis to treatment. *Critical*
14 *Care*. 2017;21(1).
- 15 51. Ambrosy AP, Pang PS, Khan S, Konstam MA, Fonarow GC, Traver B, et al. Clinical course and
16 predictive value of congestion during hospitalization in patients admitted for worsening signs and
17 symptoms of heart failure with reduced ejection fraction: findings from the EVEREST trial.
18 *European heart journal*. 2013 Mar;34(11):835–43.
- 19 52. Chioncel O, Mebazaa A, Maggioni AP, Harjola VP, Rosano G, Laroche C, et al. Acute heart failure
20 congestion and perfusion status - impact of the clinical classification on in-hospital and long-term
21 outcomes; insights from the ESC-EORP-HFA Heart Failure Long-Term Registry. *Eur J Heart Fail*.
22 2019 Nov;21(11):1338–52.
- 23 53. Al Coiro et S, Coiro S, Rossignol P, Ambrosio G, Carluccio E, Alunni G, et al. Prognostic value of
24 residual pulmonary congestion at discharge assessed by lung ultrasound imaging in heart failure.
25 *European Journal of Heart Failure*. 2015;17(11):1172–81.
- 26 54. Cogliati C, Casazza G, Ceriani E, Torzillo D, Furlotti S, Bossi I, et al. Lung ultrasound and short-
27 term prognosis in heart failure patients. *International Journal of Cardiology*. 2016;218.
- 28 55. Palazzuoli A, Ruocco G, Beltrami M, Nuti R, Cleland JG. Combined use of lung ultrasound, B-type
29 natriuretic peptide, and echocardiography for outcome prediction in patients with acute HFrEF and
30 HFpEF. *Clinical research in cardiology: official journal of the German Cardiac Society*. 2018
31 Jul;107(7):586–96.
- 32 56. Coiro S, Porot G, Rossignol P, Ambrosio G, Carluccio E, Tritto I, et al. Prognostic value of
33 pulmonary congestion assessed by lung ultrasound imaging during heart failure hospitalisation: A
34 two-centre cohort study. *Scientific Reports*. 2016 Dec 20;6:39426.
- 35 57. Lindner M, Thomas R, Claggett B, Lewis EF, Groarke J, Merz AA, et al. Quantification of pleural
36 effusions on thoracic ultrasound in acute heart failure. *Eur Heart J Acute Cardiovasc Care*. 2020
37 Aug;9(5):513–21.
- 38 58. Pellicori P, Cleland JGF, Zhang J, Kallvikbacka-Bennett A, Urbinati A, Shah P, et al. Cardiac
39 Dysfunction, Congestion and Loop Diuretics: their Relationship to Prognosis in Heart Failure.
40 *Cardiovascular drugs and therapy*. 2016 Dec;30(6):599–609.

- 1 59. Rivas-Lasarte M, Álvarez-García J, Fernández-Martínez J, Maestro A, López-López L, Solé-
2 González E, et al. Lung ultrasound-guided treatment in ambulatory patients with heart failure:
3 a randomized controlled clinical trial (LUS-HF study). *European journal of heart failure*. 2019
4 Dec;21(12):1605–13.
- 5 60. Araiza-Garaygordobil D, Gopar-Nieto R, Martínez-Amezcuá P, Cabello-López A, Alanis-Estrada
6 G, Luna-Herbert A, et al. A randomized controlled trial of lung ultrasound-guided therapy in heart
7 failure (CLUSTER-HF study). *American heart journal*. 2020 Sep;227:31–9.
- 8 61. Marini C, Fragasso G, Italia L, Sisakian H, Tufaro V, Ingallina G, et al. Lung ultrasound-guided
9 therapy reduces acute decompensation events in chronic heart failure. *Heart*. 2020 Dec
10 1;106(24):1934.
- 11 62. Scali MC, Cortigiani L, Simionuc A, Gregori D, Marzilli M, Picano E. Exercise-induced B-lines
12 identify worse functional and prognostic stage in heart failure patients with depressed left
13 ventricular ejection fraction. *European Journal of Heart Failure* [Internet]. 2017 Feb; Available
14 from: <http://doi.wiley.com/10.1002/ejhf.776>
- 15 63. Agricola E, Picano E, Oppizzi M, Pisani M, Meris A, Fragasso G, et al. Assessment of Stress-
16 induced Pulmonary Interstitial Edema by Chest Ultrasound During Exercise Echocardiography and
17 its Correlation with Left Ventricular Function. *Journal of the American Society of*
18 *Echocardiography*. 2006;19:457–63.
- 19 64. Simonovic D, Coiro S, Carluccio E, Girerd N, Deljanin-Ilic M, Cattadori G, et al. Exercise elicits
20 dynamic changes in extravascular lung water and haemodynamic congestion in heart failure
21 patients with preserved ejection fraction. Vol. 20, *European journal of heart failure*. England; 2018.
22 p. 1366–9.
- 23 65. Pugliese NR, Mazzola M, Fabiani I, Gargani L, De Biase N, Pedrinelli R, et al. Haemodynamic and
24 metabolic phenotyping of hypertensive patients with and without heart failure by combining
25 cardiopulmonary and echocardiographic stress test. *Eur J Heart Fail*. 2020 Mar;22(3):458–68.
- 26 66. Simonovic D, Coiro S, Deljanin-Ilic M, Kobayashi M, Carluccio E, Girerd N, et al. Exercise-induced
27 B-lines in heart failure with preserved ejection fraction occur along with diastolic function
28 worsening. *ESC heart failure*. 2021 Dec;8(6):5068–80.
- 29 67. Reddy YN V, Obokata M, Wiley B, Koepp KE, Jorgenson CC, Egbe A, et al. The haemodynamic
30 basis of lung congestion during exercise in heart failure with preserved ejection fraction.
31 *European heart journal*. 2019 Dec;40(45):3721–30.
- 32 68. Coiro S, Simonovic D, Deljanin-Ilic M, Duarte K, Carluccio E, Cattadori G, et al. Prognostic Value
33 of Dynamic Changes in Pulmonary Congestion During Exercise Stress Echocardiography in Heart
34 Failure With Preserved Ejection Fraction. *Circulation Heart failure*. 2020 Jun;13(6):e006769.
- 35 69. Pugliese NR, De Biase N, Gargani L, Mazzola M, Conte L, Fabiani I, et al. Predicting the transition
36 to and progression of heart failure with preserved ejection fraction: a weighted risk score using bio-
37 humoral, cardiopulmonary, and echocardiographic stress testing. *Eur J Prev Cardiol*. 2021 Dec
38 29;28(15):1650–61.
- 39 70. Lindner M, Lindsey A, Bain PA, Platz E. Prevalence and prognostic importance of lung ultrasound
40 findings in acute coronary syndrome: A systematic review. *Echocardiography*. 2021
41 Dec;38(12):2069–76.

- 1 71. Lichtenstein D a, Mezière G a. Relevance of lung ultrasound in the diagnosis of acute respiratory
2 failure: the BLUE protocol. *Chest*. 2008 Jul;134(1):117–25.
- 3 72. Lancellotti P, Price S, Edvardsen T, Cosyns B, Neskovic AN, Dulgheru R, et al. The use of
4 echocardiography in acute cardiovascular care: recommendations of the European Association of
5 Cardiovascular Imaging and the Acute Cardiovascular Care Association. *European heart journal*
6 *cardiovascular Imaging*. 2015;16(2).
- 7 73. Ding W, Shen Y, Yang J, He X, Zhang M. Diagnosis of pneumothorax by radiography and
8 ultrasonography: a meta-analysis. *Chest*. 2011 Oct;140(4):859–66.
- 9 74. Nazerian P, Vanni S, Volpicelli G, Gigli C, Zanobetti M, Bartolucci M, et al. Accuracy of point-of-
10 care multiorgan ultrasonography for the diagnosis of pulmonary embolism. *Chest* [Internet]. 2013;
11 Available from: <http://www.ncbi.nlm.nih.gov/pubmed/24092475>
- 12 75. Copetti R, Cominotto F, Meduri S, Orso D. The ‘Survived Lung.’ An Ultrasound Sign of ‘Bubbly
13 Consolidation’ Pulmonary Infarction. *Ultrasound Med Biol*. 2020 Sep;46(9):2546–50.
- 14 76. Lichtenstein DA. Ultrasound in the management of thoracic disease: *Critical Care Medicine*. 2007
15 May;35(Suppl):S250–61.
- 16 77. Gargani L, Soliman-Aboumarie H, Volpicelli G, Corradi F, Pastore MC, Cameli M. Why, when, and
17 how to use lung ultrasound during the COVID-19 pandemic: enthusiasm and caution. *Eur Heart J*
18 *Cardiovasc Imaging*. 2020 Sep 1;21(9):941–8.
- 19 78. Cavayas YA, Girard M, Desjardins G, Denault AY. Transesophageal lung ultrasonography: a novel
20 technique for investigating hypoxemia. *Canadian Journal of Anesthesia/Journal canadien*
21 *d’anesthésie*. 2016 Nov 1;63(11):1266–76.
- 22 79. Russell FM, Ehrman RR, Cosby K, Ansari A, Tseeng S, Christain E, et al. Diagnosing acute heart
23 failure in patients with undifferentiated dyspnea: A lung and cardiac ultrasound (LuCUS) protocol.
24 *Academic Emergency Medicine*. 2015;22(2).
- 25 80. Čelutkienė J, Lainscak M, Anderson L, Gayat E, Grapsa J, Harjola VP, et al. Imaging in patients
26 with suspected acute heart failure: timeline approach position statement on behalf of the Heart
27 Failure Association of the European Society of Cardiology. *European Journal of Heart Failure*.
28 2020 Feb 1;22(2):181–95.
- 29 81. Hubert A, Girerd N, Le Breton H, Galli E, Latar I, Fournet M, et al. Diagnostic accuracy of lung
30 ultrasound for identification of elevated left ventricular filling pressure. *Int J Cardiol*. 2019 Apr
31 15;281:62–8.
- 32 82. Miglioranza MH, Gargani L, Sant’anna RT, Rover MM, Martins VM, Mantovani A, et al. Lung
33 Ultrasound for the Evaluation of Pulmonary Congestion in Outpatients: A Comparison With Clinical
34 Assessment, Natriuretic Peptides, and Echocardiography. *JACC Cardiovascular imaging*
35 [Internet]. 2013 Sep; Available from: <http://www.ncbi.nlm.nih.gov/pubmed/24094830>
- 36 83. Kobayashi M, Gargani L, Palazzuoli A, Ambrosio G, Bayés-Genis A, Lupon J, et al. Association
37 between right-sided cardiac function and ultrasound-based pulmonary congestion on acutely
38 decompensated heart failure: findings from a pooled analysis of four cohort studies. *Clin Res*
39 *Cardiol*. 2021 Aug;110(8):1181–92.
- 40 84. Neskovic AN, Skinner H, Price S, Via G, De Hert S, Stankovic I, et al. Focus cardiac ultrasound

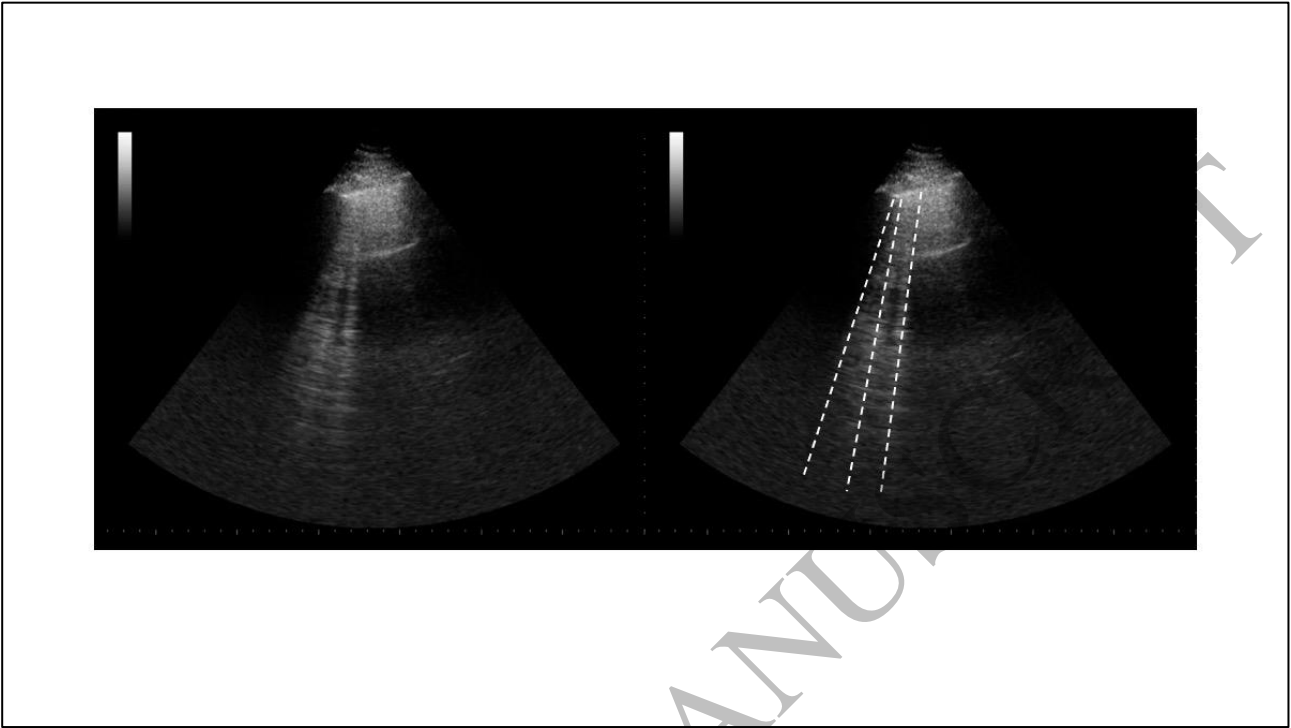
- 1 core curriculum and core syllabus of the European Association of Cardiovascular Imaging. Eur
2 Heart J Cardiovasc Imaging. 2018 May 1;19(5):475–81.
- 3 85. Bedetti G, Gargani L, Corbisiero A, Frassi F, Poggianti E, Mottola G. Evaluation of ultrasound lung
4 comets by hand-held echocardiography. Cardiovascular Ultrasound. 2006;4.
- 5 86. Noble VE, Lamhaut L, Capp R, Bosson N, Liteplo A, Marx JS, et al. Evaluation of a thoracic
6 ultrasound training module for the detection of pneumothorax and pulmonary edema by
7 prehospital physician care providers. BMC medical education. 2009 Jan;9:3–3.
- 8 87. Zisis G, Yang Y, Huynh Q, Whitmore K, Lay M, Wright L, et al. Nurse-Provided Lung and Inferior
9 Vena Cava Assessment in Patients With Heart Failure. J Am Coll Cardiol. 2022 Aug 2;80(5):513–
10 23.
- 11 88. de Souza LAM, Paredes RG, Giraldi T, Franco MH, de Carvalho-Filho MA, Cecilio-Fernandes D,
12 et al. Implementation and Assessment of Lung Ultrasound Training Curriculum for
13 Physiotherapists With a Focus on Image Acquisition and Calculation of an Aeration Score.
14 Ultrasound Med Biol. 2022 Oct;48(10):2119–27.
- 15 89. Palazzuoli A, Ruocco G, Franci B, Evangelista I, Lucani B, Nuti R, et al. Ultrasound indices of
16 congestion in patients with acute heart failure according to body mass index. Clin Res Cardiol.
17 2020 Nov 1;109(11):1423–33.

18
19 Figure 1



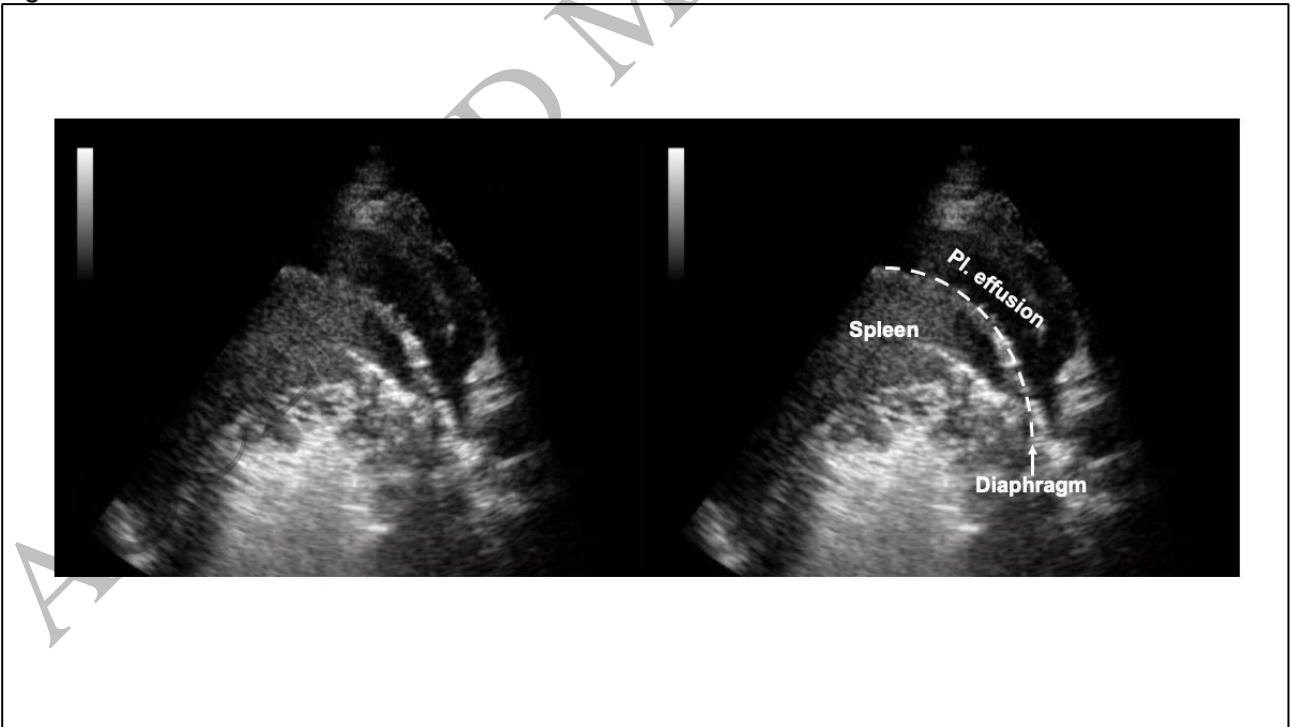
20
21
22
23
24
25
26

1 Figure 2

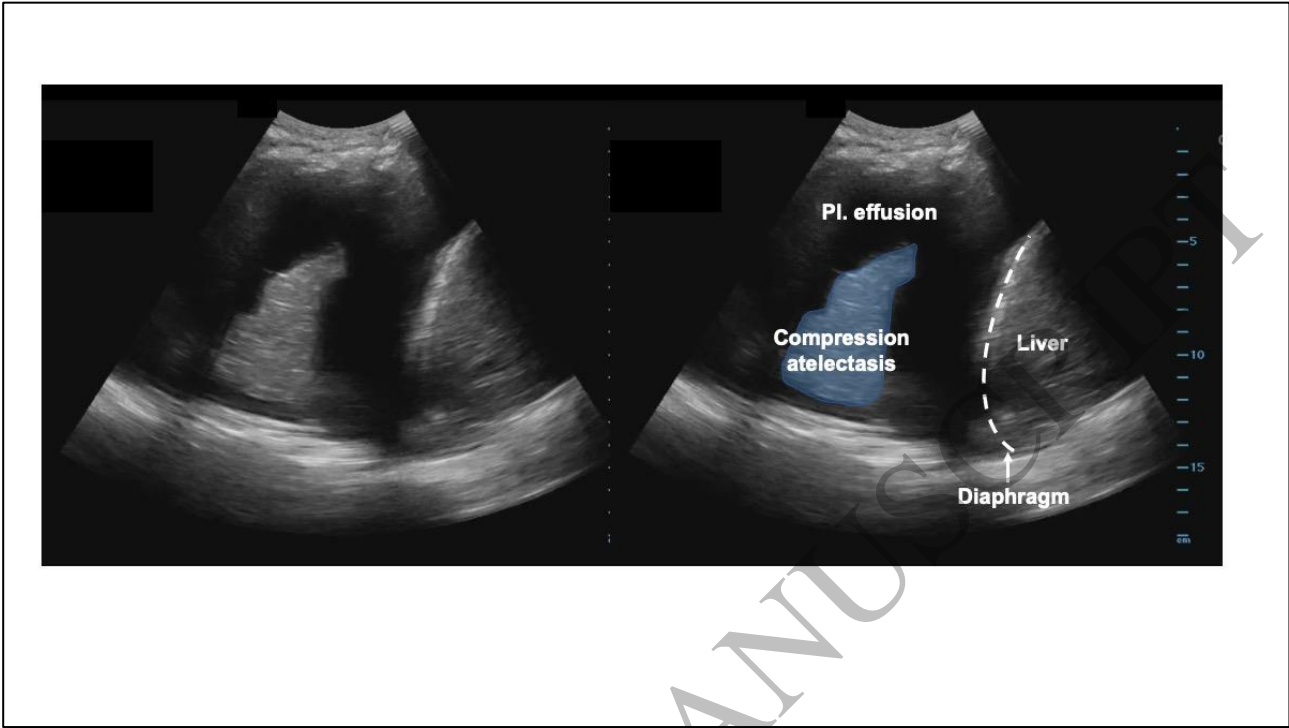


5
6
7
8
9
10
11

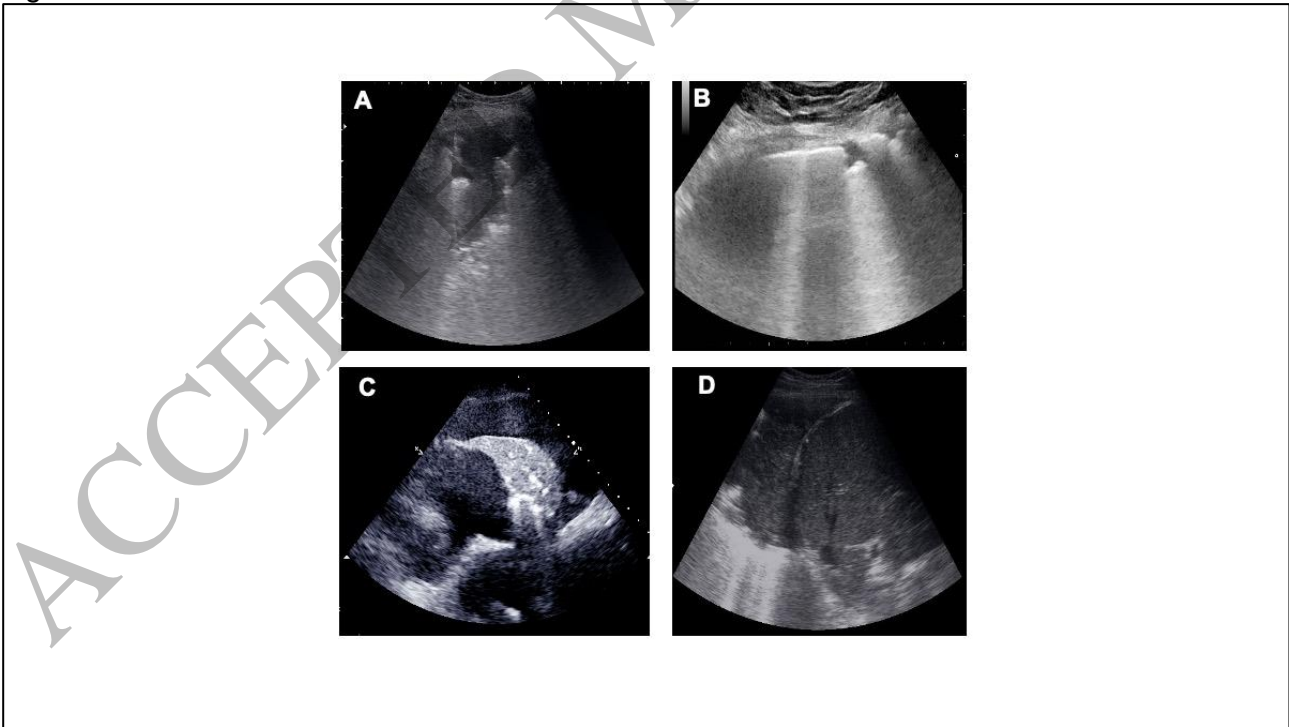
Figure 3



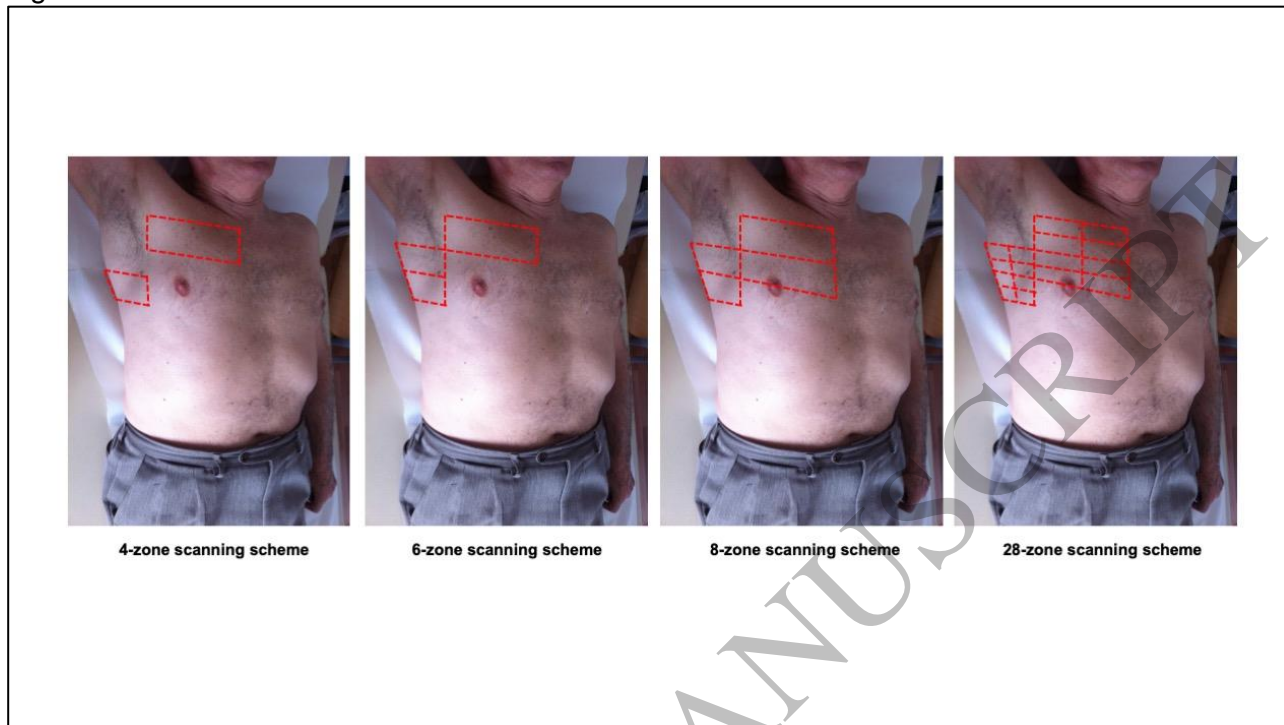
1 Figure 4



5
6
7
8
9
10
11

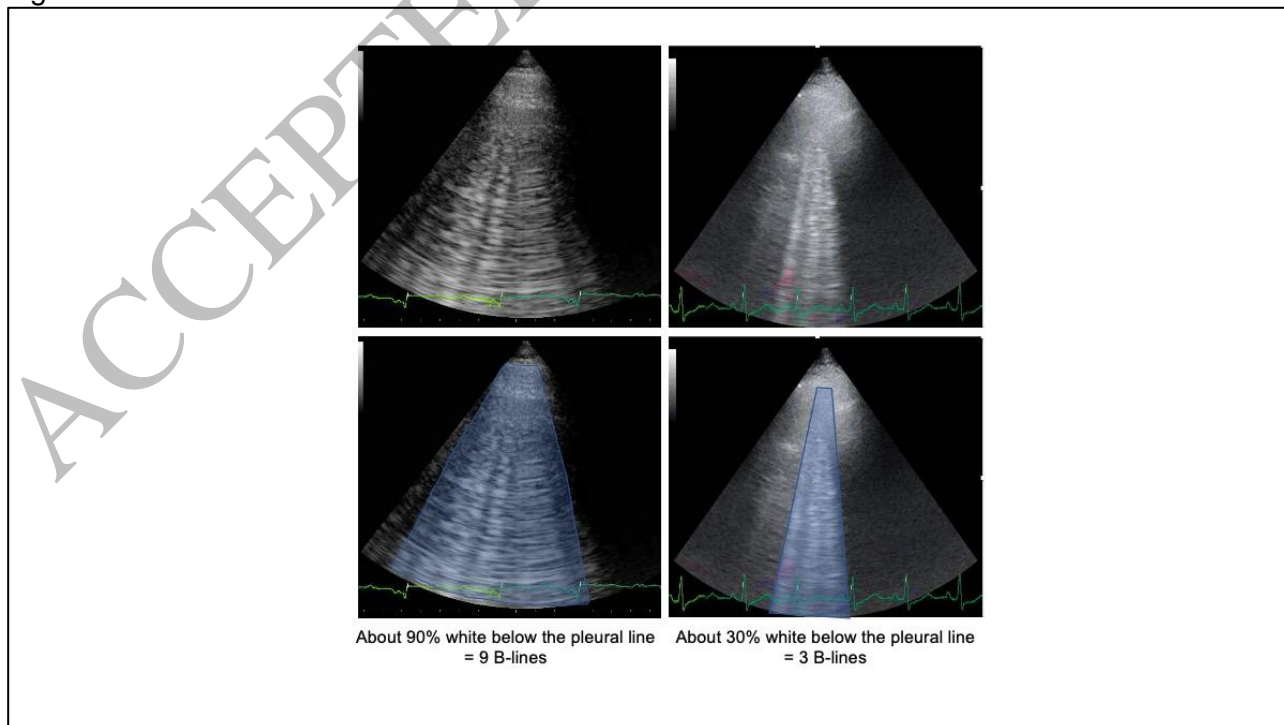


1 Figure 6



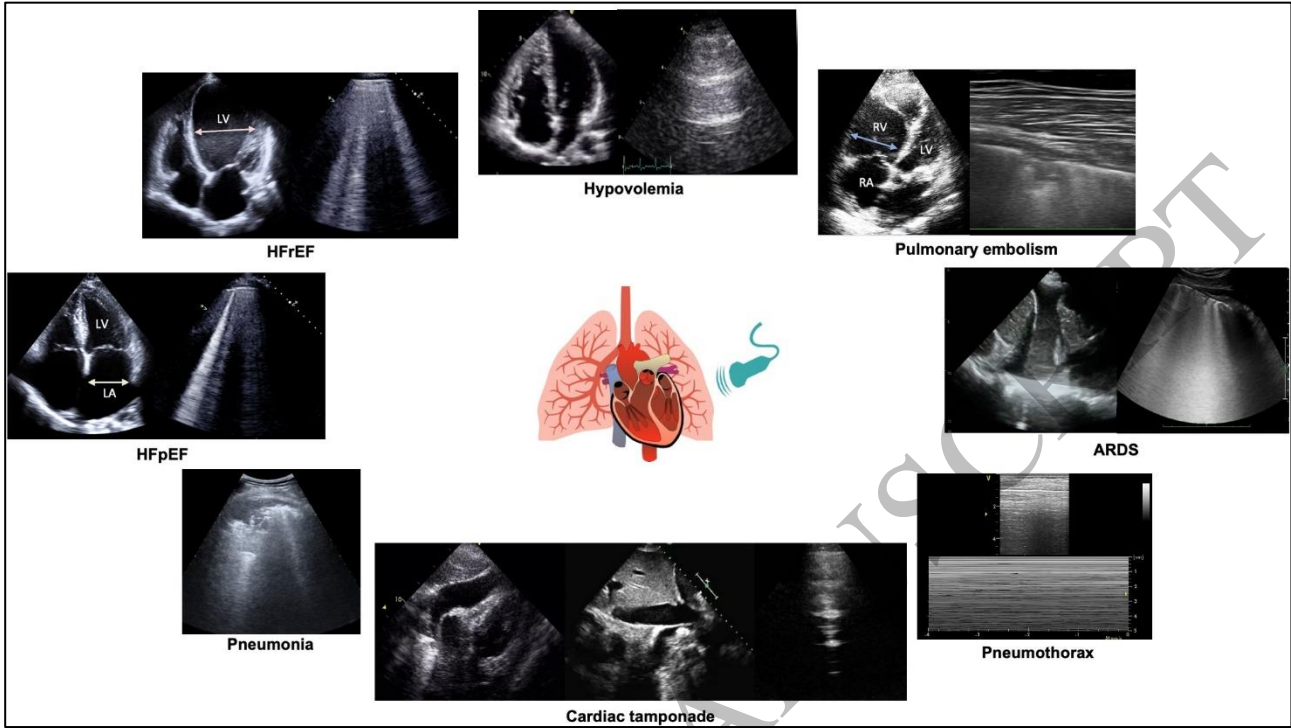
2
3
4
5
6
7
8
9

Figure 7



10
11

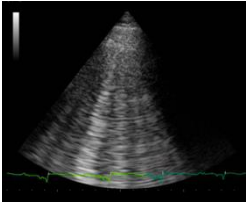

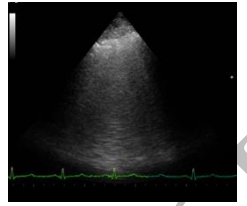
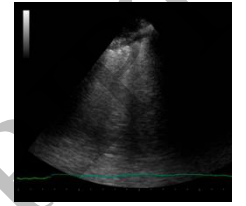
1 Figure 8



2
3
4
5
6
7
8
9
10
11
12
13
14
15
16
17
18
19

1 Table 1. Different LUS features in different conditions where multiple B-lines are present.

2

	Cardiogenic pulmonary edema	ALI/ARDS	Interstitial pneumonia	Interstitial pulmonary fibrosis
				
B-lines distribution	<ul style="list-style-type: none"> • Homogeneous, gravity-related • No spared areas 	<ul style="list-style-type: none"> • Patchy, non-gravity related • Spared areas +++ 	<ul style="list-style-type: none"> • Patchy, non-gravity related • Spared areas ++ 	<ul style="list-style-type: none"> • Usually more numerous at lung bases • No spared areas
Pleural line appearance	<ul style="list-style-type: none"> • Usually thin and regular 	<ul style="list-style-type: none"> • Grossly irregular and "fragmented" 	<ul style="list-style-type: none"> • Irregular and "fragmented" 	<ul style="list-style-type: none"> • Irregular in moderate/severe degree, can seem normal in mild degree
Consolidations	<ul style="list-style-type: none"> • Usually not present unless compressive atelectasis in large pleural effusions 	<ul style="list-style-type: none"> • Frequent peripheral small consolidations and larger consolidations 	<ul style="list-style-type: none"> • Usually not present 	<ul style="list-style-type: none"> • Rarely present unless in acute phases (i.e. alveolitis), and small
Pleural effusion	<ul style="list-style-type: none"> • Frequent, variable size • Transudate, not complex appearance • Usually bilateral (often larger on the right side) 	<ul style="list-style-type: none"> • Usually trivial/mild 	<ul style="list-style-type: none"> • Usually trivial 	<ul style="list-style-type: none"> • Rare, unless in very advanced cases or acute phases, and usually trivial/mild

3

4 ALI= acute lung injury; ARDS= acute respiratory distress syndrome

5

6

7

8

9

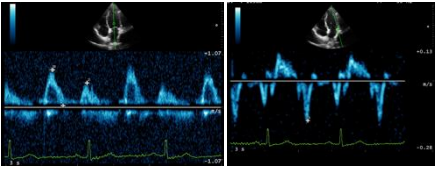
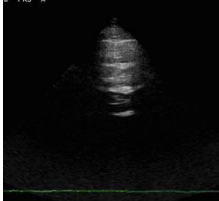
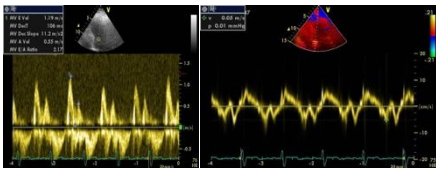

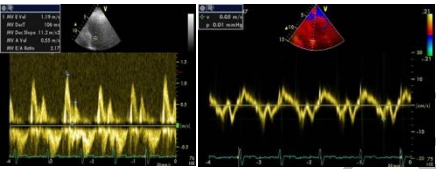
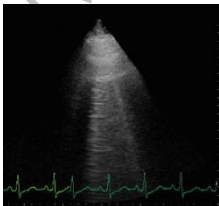
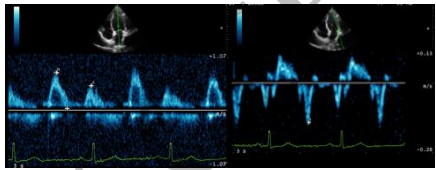
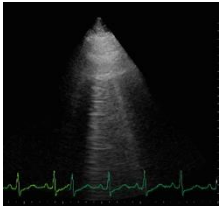
10

11

12

1 Table 4. How to integrate echocardiographic and pulmonary findings to assess congestion status.

2

<p>E/e' and other echocardiographic signs of increased left ventricular filling pressures</p>	<p>B-lines</p>	
<p>Normal</p> 	<p>No B-lines</p> 	<p>No congestion</p>
<p>Increased</p> 	<p>No B-lines</p> 	<p>Hemodynamic congestion</p>
<p>Increased</p> 	<p>Multiple diffuse bilateral B-lines</p> 	<p>Hemodynamic and pulmonary congestion</p>
<p>Normal</p> 	<p>Multiple diffuse bilateral B-lines</p> 	<p>Pulmonary congestion without hemodynamic congestion (check for ALI/ARDS or other causes of B-lines)</p>

3

4 ALI= acute lung injury; ARDS= acute respiratory distress syndrome

5

6

7

8

9

1 Table 5. Gaps in current evidence

2

Setting	Trials/studies needed	Main questions to be addressed
Acute Heart Failure	Additional randomized trials assessing whether LUS can improve the diagnosis and characterization of patients with acute HF beyond traditional approaches.	<ul style="list-style-type: none"> -Can the use of LUS facilitate the classification of acute HF phenotypes that can benefit from specific therapeutic interventions? -Can LUS imaging be used to improve management decisions in patients with AHF, e.g. hospital admission vs. early discharge from the Emergency Department? -Is the use of LUS imaging effective and safe as part of a strategy to improve congestion relief in AHF, including intensification/de-intensification of diuretic therapy? -Can the use of LUS improve post-discharge outcomes in patients with AHF?
Chronic heart failure	Development and validation of diagnostic protocols assessing the utility of LUS at rest or during exercise in the diagnosis of HFpEF.	<ul style="list-style-type: none"> -Can the use of LUS improve the clinical course of patients with chronic HF (HFReEF and/or HFpEF)? -Can the use of LUS facilitate the identification of subsets of patients with chronic HF that can benefit from specific therapeutic interventions? -Is the use of LUS in the management of patients with chronic HF cost-effective? -Can the use of LUS improve the clinical course of specific HF phenotypes (myocarditis, cardiotoxicity, inherited cardiomyopathies, post-partum cardiomyopathy, amyloidosis)?
Acute coronary syndromes	Additional randomized trials assessing whether LUS can improve the diagnosis of the etiology of chest pain beyond traditional approaches.	<ul style="list-style-type: none"> -Can the use of LUS facilitate the identification of subsets of patients with ACS that can benefit from specific therapeutic interventions?

3

4 LUS= lung ultrasound; HF= heart failure; AHF= acute heart failure; HFReEF= heart failure with reduced ejection fraction;
 5 HFpEF= heart failure with preserved ejection fraction