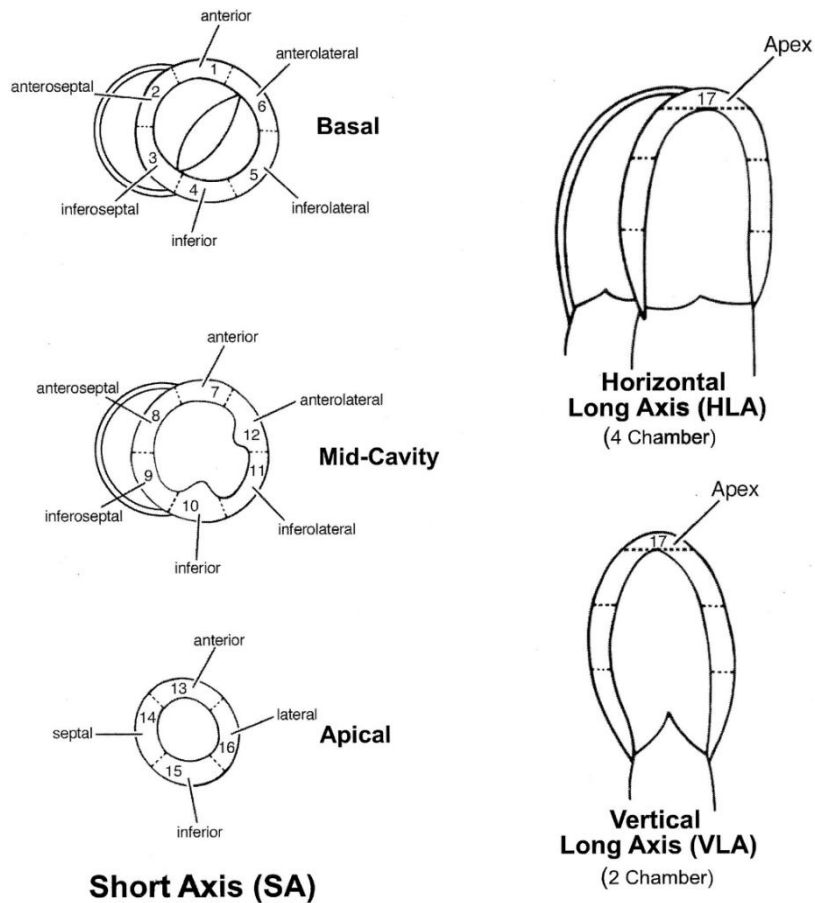


Cardiac MRI Methodology

MRIs were performed on a 3 or 1.5 Tesla scanner (Siemens Medical Solution, Erlangen, Germany), according to an already published methodology from our team*: (i) LV function and mass were measured from contiguous short-axis slices recorded with a compressed sensing SSFP sequence, (ii) late gadolinium enhancement (LGE) images were recorded with a phase-sensitive inversion recovery sequence, 10 to 15 min after injection of 0.1 mmol.kg⁻¹ body weight of Dotarem® (GUERBET, France), (iii) transversal relaxation (T2) maps were obtained with 2D Truefisp (1.5T Magnet) or TurboFlash (3T Magnet) sequences, and (iv) longitudinal relaxation (T1) maps were obtained with Modified Look-Locker sequences.

Because the normal ranges of T1 and T2 values are different between our 1.5 and 3T scanners, these parameters were normalized and expressed in percentages of mean normal values for the present study.

*: Filippetti L, Pace N, Louis JS, et al. Long-Lasting Myocardial and Skeletal Muscle Damage Evidenced by Serial CMR During the First Year in COVID-19 Patients From the First Wave. *Front Cardiovasc Med.* 2022;9:831580.



Supplemental Figure 1: Standardized myocardial segmentation and nomenclature for tomographic heart imaging.*

*: Cerqueira MD, Weissman NJ, Dilsizian V, et al. Standardized myocardial segmentation and nomenclature for tomographic imaging of the heart. A statement for healthcare professionals from the Cardiac Imaging Committee of the Council on Clinical Cardiology of the American Heart Association. *Circulation*. 2002;105:539-542.