



HAL
open science

Case report: Laryngeal oncocytic cyst found during a screening for upper aerodigestive tract cancer

Romina Mastronicola, Elise Kayser, Jacques Thomas, Gilles Dolivet

► To cite this version:

Romina Mastronicola, Elise Kayser, Jacques Thomas, Gilles Dolivet. Case report: Laryngeal oncocytic cyst found during a screening for upper aerodigestive tract cancer. *International Journal of Surgery Case Reports*, 2024, 125, pp.110594. 10.1016/j.ijscr.2024.110594 . hal-04810055

HAL Id: hal-04810055

<https://hal.univ-lorraine.fr/hal-04810055v1>

Submitted on 29 Nov 2024

HAL is a multi-disciplinary open access archive for the deposit and dissemination of scientific research documents, whether they are published or not. The documents may come from teaching and research institutions in France or abroad, or from public or private research centers.

L'archive ouverte pluridisciplinaire **HAL**, est destinée au dépôt et à la diffusion de documents scientifiques de niveau recherche, publiés ou non, émanant des établissements d'enseignement et de recherche français ou étrangers, des laboratoires publics ou privés.



Case report

Case report: Laryngeal oncocytic cyst found during a screening for upper aerodigestive tract cancer

Romina Mastronicola^{a,b,*}, Elise Kayser^a, Jacques Thomas^a, Gilles Dolivet^{a,b}^a Institut de Cancérologie de Lorraine, 6 avenue de Bourgogne, 54519 Vandœuvre-lès-Nancy, France^b CRAN, CNRS, UMR 7039, Université de Lorraine, Vandœuvre-lès-Nancy, France

ARTICLE INFO

Keywords:

Oncocytic cyst
Laryngeal lesion
Case report

ABSTRACT

Introduction and importance: Oncocytic cysts are benign lesions seldom found in the region of the larynx. The phenomenon leading to their appearance is currently not well known but could be linked with aging and smoking. This article describes the case of a patient in whom a laryngeal oncocytic cyst was found.

Case presentation: A 52-year-old man presented during a screening for upper aerodigestive tract cancer with a lesion on the anterior third of the left vocal cord. He reported no symptoms but had tobacco use. Other medical history was unremarkable. Laryngoscopy revealed a cyst arising from the left vocal cord. It was excised with CO₂ laser and measured 0,3 × 0,2 × 0,1 cm. Histopathology revealed that the cyst was composed of oncocytic cells lining the epithelium, with eosinophilic and granular aspect in the cytoplasm, with a small and dark nucleus. Thus far, there is no sign of recurrence with this patient.

Clinical discussion: Laryngeal oncocytic cysts are unusual lesions which can appear with different types of symptoms or with no symptoms. They are formed with oncocytes, with eosinophilic cytoplasm and dark nuclei. Oncocytic cysts have generally no recurrence, but follow-up care is required for mechanisms of such lesions are not well known. Metaplasia in this type of lesions would be caused by physiological exhaustion and inflammation.

Conclusion: A patient presented with an oncocytic cyst fortuitously discovered and underwent CO₂ laser to remove it. The causes may have been smoking and aging, but it remains a rare and atypical case.

1. Introduction

Oncocytic cysts are benign and slow-growing lesions, in most cases lined by oncocytes [1]. Oncocytes are large columnar cells, with an eosinophilic and granular cytoplasm, and a small dense nucleus of dark staining [2]. The cytoplasm gives a swollen aspect to oncocytes because of the presence of hypertrophied mitochondria with mitochondrial DNA changes. Oncocytic transformation is related with metaplasia, a phenomenon which often occurs in epithelial endocrine cells, with metabolic activity [3]. Consequently, oncocytic cysts have been identified in sites like epithelial lining of glands or mucosae, in the upper and lower respiratory tract, tongue, pharynx, esophagus and thyroid for instance. Thus, laryngeal localisation is very rare for oncocytic cysts, and studies showed that it represented less than 1 % of laryngeal biopsies [4]. They are commonly found in supraglottic larynx or laryngeal ventricles, because of the presence of seromucinous glands, but they can occur anywhere save the free edge of the false vocal cord, where there is no

glandular epithelium [1,5,6]. Thus far, 150 cases of laryngeal oncocytic cysts have been described in the literature.

2. Case report

During a screening for upper aerodigestive tract cancer, a 52-year-old man presented with a lesion on the anterior third of the left vocal cord. This was a serendipitous discovery. The patient did not report any dysphonia or hoarseness, nasal obstruction, dysphagia, shortness of breath, cough or haemoptysis, but he did use tobacco during his lifetime. The other medical and social history was unremarkable. Trachea nasofibroscope revealed an exophytic lesion, of whitish color, on the anterior third of the left vocal cord. The rest of the examination was normal. Direct laryngoscopy was indicated then, with biopsy.

* Corresponding author at: Institut de Cancérologie de Lorraine ICL, France.
E-mail address: r.mastronicola@nancy.unicancer.fr (R. Mastronicola).

<https://doi.org/10.1016/j.ijscr.2024.110594>

Received 16 October 2024; Received in revised form 4 November 2024; Accepted 9 November 2024

Available online 12 November 2024

2210-2612/© 2024 The Authors. Published by Elsevier Ltd on behalf of IJS Publishing Group Limited. This is an open access article under the CC BY-NC-ND license (<http://creativecommons.org/licenses/by-nc-nd/4.0/>).

3. Investigations

Three weeks later, direct laryngoscopy and biopsy revealed that it was a cyst, arising from the anterior third of the left vocal cord. The cyst was excised with CO₂ laser. It measured 0,3 × 0,2 × 0,1 cm. Histopathology revealed that the sample was made up of Malpighian mucous membrane, underpinned with a cystic formation bistratified with epithelial foundation and oncocytic partially metaplasia (Fig. 1). The conclusion given was of an oncocytic cyst of the left vocal cord, without atypia and malignancy on the surface.

4. Discussion

Laryngeal oncocytic cysts are unusual lesions which occur preferentially in women, after the age of fifty, and remain rare [2]. The social history includes usually a positive use of smoking. Oncocytic cysts can have various shapes: sessile, pedunculated or polypoid [1]. Depending on the presentation of the cyst, obstruction or breath difficulties can occur. The main symptom is hoarseness, but others can appear like pain, foreign body sensation, or stridor for example [4]. In some cases, like in ours, patients can be asymptomatic, and this makes the diagnosis uneasy or serendipitous.

Treatment is based on conservative management with complete excision of the cyst, with CO₂ laser, like in our case, or cold steel. Follow-up care is required because of the risk of recurrence, especially in case of multiple cysts or multiple involvement [7]. However, in most cases cysts are ordinarily solitary without diffuse involvement, except in cases with papillary projections [6]. Malignant potential is currently not known but could be low, due to the low proliferate rate of the concerned cells [8]. Differential diagnosis in this type of cyst can be carcinoma, like laryngeal squamous cell carcinoma [9].

The development of laryngeal oncocytic cysts would be caused by the metaplasia of the respiratory epithelium, a phenomenon which increases with aging [10,11]. Moreover, oncocytic cysts are normally not found in young patients, but their appearance steps up with advancing age, especially in salivary glands. There are hypotheses conjecturing that oncocytic change would be the result of physiological transformation, due to cellular functions exhaustion [3]. Consequently, the increasing number of mitochondria in oncocytes would act like a compensatory process, and finally give the typical aspect (swollen, eosinophilic) to this type of cells. In addition, the mucosa inflammation caused by smoking can stimulate the appearance of oncocytic change in the larynx.

5. Conclusion

Laryngeal oncocytic cysts are rare, benign and slow-growing lesions, but they can occur almost everywhere in the larynx, preferentially near seromucinous glands. The main causes are aging, with functional exhaustion; and smoking, with inflammation of the mucosa. Treatments are based on excision, with cold steel or CO₂ laser, and follow-up care is required for recurrence is not impossible, especially in case of multiple cysts.

This work has been reported in line with the SCARE criteria [12].

Informed consent statement

Informed consent was obtained from all subjects involved in this case report.

Consent

Written informed consent was obtained from the patient for publication and any accompanying images. A copy of the written consent is available for review by the Editor-in-Chief of this journal on request.

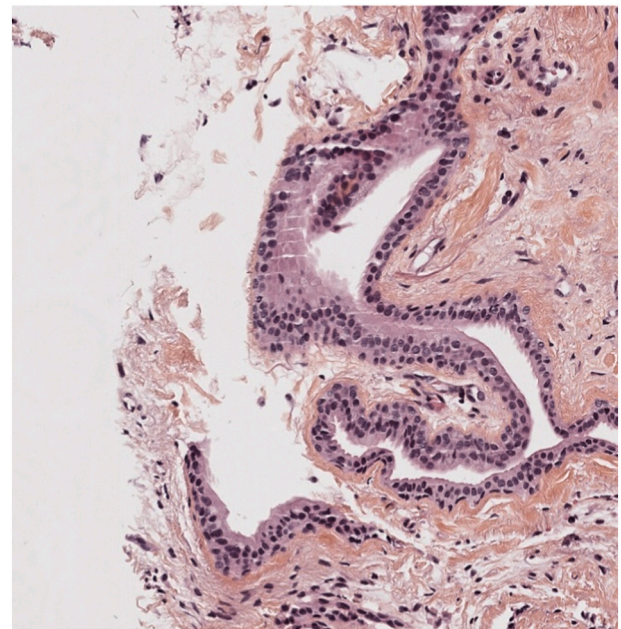


Fig. 1. Oncocytic cyst with cell lining showing eosinophilic cytoplasm and dark nuclei.

Ethical approval

Ethics Committee of the Lorraine Cancer Institute. There is no reference number as all patients give written consent by signing a consent form at their first appointment.

Guarantor

KAYSER Elise

Funding

This research did not receive any specific grant from funding agencies in the public, commercial or not-for-profit sectors.

Author contribution

MASTRONICOLA Romina, PhD: supervision of the writing, management of the case, study concept, data collection and analysis

KAYSER Elise: writing of the paper, data collection and analysis

THOMAS Jacques: providing some of the results (anatomopathological)

DOLIVET Gilles, PhD: study concept, data collection

Conflict of interest statement

The authors have no conflicts of interest to declare.

References

- [1] Baird S, Mann H, Salinas-La Rosa CM, Ozdemir H. Oncocytic cyst of the larynx: a rare finding. *BMJ Case Rep.* 18 janv 2019;12(1):bcr-2018-227214.
- [2] A. Busuttill, Oncocytic lesions of the upper respiratory tract, *J. Laryngol. Otol.* 90 (1976) 277–288.
- [3] G. Salerno, C. Mignogna, M. Cavaliere, L. D'Angelo, V. Galli, Oncocytic cyst of the larynx: an unusual occurrence, *Acta Otorhinolaryngol Ital.* août 27 (4) (2007) 212–215.
- [4] P. Puttasiddaiah, S. Berry, H. Whittet, Laryngeal oncocytic cyst presenting with an acute onset of stridor, *Ear Nose Throat J.* 88 (2009) 1003–1004.
- [5] M.J. Bullock, X.S. Jiang, Top ten Oncocytic head and neck lesions to contemplate, *Head Neck Pathol.* mars 17 (1) (2023) 53–65.

- [6] Uğur Kilinç AN, Ünlü Y, Yücel A. Laryngeal Oncocytic cystadenoma with rare location and Clinicopathological aspects. *Head Neck Pathol.* 13 oct 2020;15(3): 1004–6.
- [7] R. Heyes, C.M. Tomblinson, D.G. Lott, [Multiple and recurrent Oncocytic cysts of the larynx](#), *Ear Nose Throat J.* juin 99(5):NP54-5 (2020).
- [8] Protts FLMS, Goh S. Unusual cause of airway obstruction: subglottic oncocytic cyst. *BMJ Case Rep.* 25 juin 2019;12(6):e228663.
- [9] Sireci F, Lorusso F, Dispenza F, Immordino A, Gallina S, Salvago P, et al. A prospective observational study on the role of Immunohistochemical expression of Orphanin in laryngeal squamous cell carcinoma recurrence. *J Pers Med.* 30 juill 2023;13(8):1211.
- [10] Arens C, Glanz H, Kleinsasser O. Clinical and morphological aspects of laryngeal cysts. *Eur Arch Otorhinolaryngol.* 6 mars 1997;(254):430–6.
- [11] E. Kanioura, D. Riga, S. Potamianos, G. Kafiri, [Oncocytic papillary cystadenoma: a case of a misdiagnosed laryngeal mass](#), *Cureus.* janv 16 (1) (2024) e52147.
- [12] Sohrabi C, Mathew G, Maria N, Kerwan A, Franchi T, Agha R. The SCARE 2023 guideline: updating consensus Surgical CAse REport (SCARE) guidelines. 2023;109 (5):1136.