



HAL
open science

Case report: A laser and radiofrequency ablation in a laryngeal chondrosarcoma

Romina Mastronicola, Artur Gil, Agathe Barrat, Elise Kayser, Mathilde Treffel, Gilles Dolivet

► To cite this version:

Romina Mastronicola, Artur Gil, Agathe Barrat, Elise Kayser, Mathilde Treffel, et al.. Case report: A laser and radiofrequency ablation in a laryngeal chondrosarcoma. *International Journal of Surgery Case Reports*, 2024, 125, pp.110611. 10.1016/j.ijscr.2024.110611 . hal-04813763

HAL Id: hal-04813763

<https://hal.univ-lorraine.fr/hal-04813763v1>

Submitted on 2 Dec 2024

HAL is a multi-disciplinary open access archive for the deposit and dissemination of scientific research documents, whether they are published or not. The documents may come from teaching and research institutions in France or abroad, or from public or private research centers.

L'archive ouverte pluridisciplinaire **HAL**, est destinée au dépôt et à la diffusion de documents scientifiques de niveau recherche, publiés ou non, émanant des établissements d'enseignement et de recherche français ou étrangers, des laboratoires publics ou privés.



Case report

Case report: A laser and radiofrequency ablation in a laryngeal chondrosarcoma

Romina Mastronicola^{a,b,*}, Artur Gil^a, Agathe Barrat^a, Elise Kayser^a, Mathilde Treffel^a, Gilles Dolivet^{a,b}^a Institut de Cancérologie de Lorraine, 6 avenue de Bourgogne, 54519 Vandœuvre-lès-Nancy, France^b CRAN, CNRS, UMR 7039, Université de Lorraine, Vandœuvre-lès-Nancy, France

ARTICLE INFO

Keywords:

Chondrosarcoma

Larynx

Radiofrequency ablation

Laser

ABSTRACT

Introduction and importance: Chondrosarcoma is a tumor which arises from cartilage, and whose apparition can occur in any site. However, it remains rare in the larynx. Management depends on the grade and the stage of the tumor at the time of the presentation. Here is described the case of a 73-year-old man, who presented with a one-month history of dyspnea due to a low-grade (grade I) laryngeal chondrosarcoma. The tumor was successfully treated through a laser and radiofrequency ablation.

Case report: A 73-year-old man presented with dyspnea that appeared one month earlier. He underwent clinic examination and CT-scan analysis, which revealed a laryngeal lesion. Histological analysis of the lesion led to the conclusion of a low-grade chondrosarcoma. A non-surgical management was chosen during a multidisciplinary consultation meeting, to preserve laryngeal functions. The patient underwent repeated laser and radiofrequency ablation, to reduce the tumor volume. At present, there is still a mass in the area, but the patient doesn't present any other symptoms. However, he has a close follow up, in order that the signs of an early tumoral evolution are promptly detected.

Clinical discussion: Total laryngectomy is often used for laryngeal chondrosarcoma, but it leads to a complete loss of the laryngeal functions, among which we can quote the speaking. Thereby, it would be better for patients to find other ways of conservative management. Consequently, our case presents the success of laser and radiofrequency ablation in the treatment of a laryngeal chondrosarcoma, which allowed to protect laryngeal functions. Nevertheless, this is a non-curative method showing some limitations but improving surgery outcomes and patient quality of life.

Conclusion: This report highlights the importance of quick grading in primary laryngeal chondrosarcoma. In this case, localized low-grade chondrosarcoma was treated without surgery, with a successful outcome thanks to laser and radiofrequency ablation.

1. Introduction

Cartilaginous lesions (chondromas, chondrosarcomas) represent 0.1 % to 1 % of all laryngeal neoplasms [1]. The most common impacted localization in the upper aerodigestive tract is the cricoid cartilage, but chondrosarcomas can also arise from thyroid and arytenoid cartilage, or epiglottis [2]. The average age of patients presenting this type of lesion is 62.5 years [3], and it occurs preferentially in men. The etiology is not well known, but could be correlated with an initial disorder in the ossification of the laryngeal cartilage [4,5]. Moreover, the apparition of chondrosarcoma would not be related to alcohol and tobacco

consumption [6]. The main symptoms are hoarseness, dyspnea and dysphonia [5]. Chondrosarcoma is associated with a good prognosis compared to other laryngeal cancers, and has high 5-year and 10-year survival rates (88 % and 66 % respectively) [7].

Chondrosarcomas are divided into three grades based upon their histopathology: grade I shows the low-grade tumor (locally aggressive), also known as the atypical cartilaginous tumor; grade II presents a higher degree of nuclear atypia and hyperchromia; grade III refers to more pleomorphic tumors than in grade II. At grade III, peripheral lobular cells are less differentiated and are spindle shaped. There is a fourth grade in chondrosarcomas, which are called dedifferentiated

* Corresponding author at: Institut de Cancérologie de Lorraine ICL, France.

E-mail address: r.mastronicola@nancy.unicancer.fr (R. Mastronicola).<https://doi.org/10.1016/j.ijscr.2024.110611>

Received 18 October 2024; Received in revised form 8 November 2024; Accepted 11 November 2024

Available online 14 November 2024

2210-2612/© 2024 The Authors. Published by Elsevier Ltd on behalf of IJS Publishing Group Limited. This is an open access article under the CC BY-NC-ND license (<http://creativecommons.org/licenses/by-nc-nd/4.0/>).

chondrosarcomas. They represent 10 % of all chondrosarcomas. Dedifferentiation occurs in a small subset of patients and is defined by the presence of a high-grade, often spindled or pleomorphic tumor, without significant cartilaginous matrix. Dedifferentiated chondrosarcoma is, by definition, a high-grade neoplasm with an worse prognosis [8].

Even though one third of patients undergo a total laryngectomy, classical treatment of this type of lesion is based on surgical excision [9]. In case of large-sized tumors and to avoid relapses, recent literature suggests doing non-surgical management for laryngeal chondrosarcomas, especially if it is low-graded [10,11]. Other ways of treatment include partial laryngectomy, local resection, radiofrequency ablation, laser excision or transoral robotic surgery [12].

Chondrosarcomas have a slow progression and present a low rate of metastasis (up to 10 %), which explains the uselessness of chemotherapy [13]. Due to the low radiosensitivity of cartilaginous tissues, radiotherapy is used as a last resort, either for extensive and aggressive lesions, or inoperable lesions and in case of recurrence [14]. Moreover, chemotherapy and radiotherapy can also be used in a palliative way [15]. However, due to the inconstant and late local relapses, patients need to undergo a long-term follow-up [16].

Here is described the case of a 73-year-old man, who presented with a one-month history of dyspnea due to a low-grade (grade I) laryngeal chondrosarcoma. The tumor was successfully treated through a laser and radiofrequency ablation.

2. Case report

A 73-year-old man presented in consultation with a respiratory obstruction that appeared one month earlier. The patient had a World Health Organization (WHO) performance status of 1, which means that he had a little restriction for strenuous activities. This scale (from 0 to 4) gives an idea of the patient ability to face activity, like standing up without any help, being capable of self-care, etc. The patient was treated for high blood pressure. He had tobacco use, at a rate of one pack of cigarettes per day for fifteen years, but at the time of the case was weaned for 42 years. Concerning medical and personal history, the patient underwent cordectomy for polyps on the vocal cords twenty-five years before. Many members of his family had cancer: his father, mother and brother.

The patient underwent nasofibroscopy, which revealed a laryngeal lesion. Computed tomography (CT) scan examination Fig. 1A and anatomopathological analysis confirmed that the lesion was a low-grade left hemilaryngeal chondrosarcoma.

CT-scan showed a 39 mm × 31 mm × 51 mm (anteroposterior x transverse x height) mass arising from the arytenoid cartilage and crossing the center line. It showed no subglottic extension and no

cervical adenopathy. Pictures suggested a cartilaginous tumor at first sight. Chondronecrosis or carcinoma less seemed to be possible as the mass did not take contrast.

This case was also submitted to a sarcoma multidisciplinary consultation meeting that proposed an endoscopic conservative surgery, according to the histological type, grade, and localization of the lesion. This approach made it possible to keep laryngeal functions like deglutition, breathing, and phonation, especially because arytenoid cartilages are essential for laryngeal functions. Consequently, the patient underwent a radiofrequency ablation of chondrosarcoma. During the follow-up care, the patient had a CT-scan four months after the surgery Fig. 1B.

Cellular atypia on the histological section was characterized by a high number of cells and by large and hyperchromatic nuclei, with sometimes binucleation Fig. 2A. Cartilage containing chondrocytes with vacuolated cytoplasm, mild cytological atypia and few mitoses is visible. In addition, several areas showed lacunae, which means zones without chondrocytes Figure 2B. Neither necrosis nor hemorrhage are present, and there is no lymphovascular invasion. This case was referred to the RESOS network, whose aim is to improve the supply of care for adult patients with rare cancers. They confirmed the low grade of the chondrosarcoma.

Radiofrequency ablation consists in the creation of a thermocoagulation zone, to produce an intratumoral hyperthermia, and, consequently, the tumor necrosis. Indeed, electrodes are inserted upon contact with the tumor, thanks to a needle, to deliver a current heating the tumor at 55 °C, a temperature which is lethal for cells. The number of electrodes enables to increase the diameter of the treated zone [15].

Concerning the follow-up care, the patient was treated every three months and had one unblocking per year. He still had some dietary difficulties after the intervention, and a little worsening of phonation.

3. Discussion

In cartilaginous tumors, chondromas are benign and chondrosarcomas are malignant, but the distinction is not easy to do. Therefore, in practice, if there are symptoms, a cartilaginous lesion is always considered as a chondrosarcoma. In our case, the symptoms were dyspnea, dysphonia and hoarseness, caused by the tumor mass and the luminal obstruction.

According to the literature, the most part of laryngeal chondrosarcomas are low-graded (80 %) [6]. There was initially a diagnostic criteria for the establishment of the tumor grade in non-laryngeal chondrosarcomas, the one of Lichtenstein and Jaffe [17]. Then, a new classification was adapted for laryngeal chondrosarcomas, describing three tumor grades: low, intermediate and high. The grades depend on the differentiation degree of the tumor [18]. Moreover, the WHO

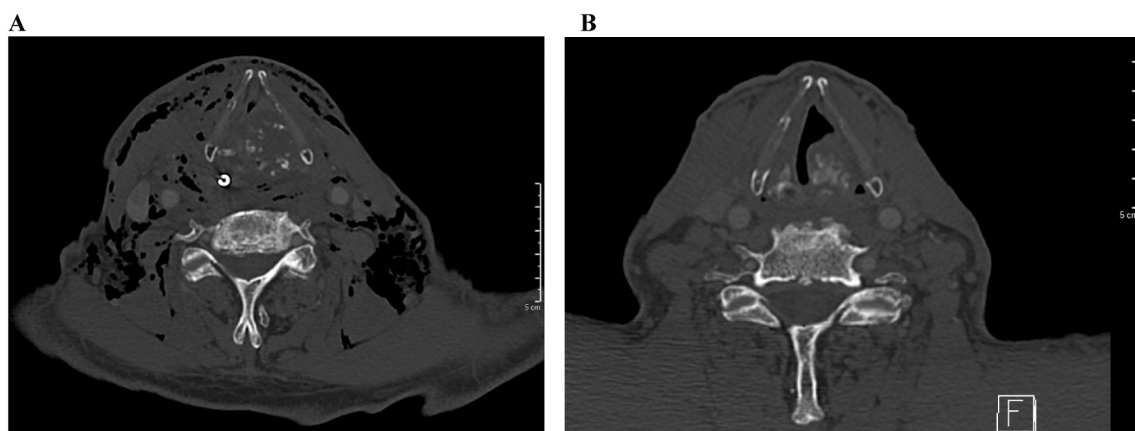


Fig. 1. Axial CT scan photomicrograph of the neck centered on the glottis; A: Initial image showing obstructed airway; B: Four months after resection, tumor mass still present but a clear airway of the larynx.

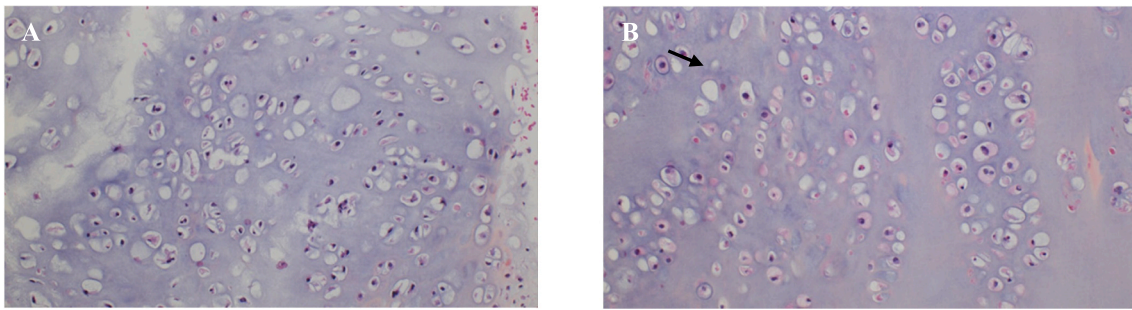


Fig. 2. Histological photomicrograph of the chondrosarcoma; A: Atypical cartilaginous structure attributable to malignancy lesion; B: Cartilaginous tissue presenting signs of necrosis (the black arrow points out a lacuna). Hematoxylin and eosin (H&E), magnification $\times 60$.

classification of otorhinolaryngological tumors also proposes several grades in the diagnosis of head and neck chondrosarcomas. However, in practice, chondrosarcomas are directly considered as low grade when localized in the upper aerodigestive tract.

In case of chondrosarcomas affecting femur, rib, or pelvis chondrocytes, for the most frequent localizations, total ablation surgery of the lesion is the preferential treatment [19]. However, this approach remains debatable concerning laryngeal chondrosarcomas.

Chin et al. study shows that among 592 cases, 30.1 % of laryngeal chondrosarcomas had a local resection, 29.4 % had total laryngectomy, 15 % had partial laryngectomy and 3.9 % had laser excision [3]. Usually, total laryngectomy is indicated when there are recurrences or histological anaplasia [20]. Furthermore, total laryngectomy is commonly carried out when tumor mass involves >50 % of the cricoid plate [3,21], whose partial ablation would cause the destabilization of the larynx [18].

Total laryngectomy is also performed as a salvage intervention in laryngeal chondrosarcoma recurrences [3]. However, recurrences do not affect overall survival and total laryngectomy does not present additional survival compared to partial laryngectomy and local excision [11,22]. According to Chin et al., the tumor grade and the associated treatment do not affect the 5-year survival. In the Adeola et al. study, similar results are pointed out for 5-year survival [16]. 10-year survival probability seems to be better in local resection (LR) and partial laryngectomy (PL) (10-year: LR (86.4 %)/ PL (85.0 %); p -value (0,001) than in total laryngectomy (10-year, 65.9 %, p -value $<0,001$).

Radiofrequency ablation is a minimally invasive technique, which allows a good tissues preservation in head and neck cancer [23]. Consequently, it appears to be an interesting new way of treatment. Due to its less aggressive nature, compared to excision surgery, radiofrequency ablation arises as a more suitable solution for this type of lesion.

However, this technique has many limitations. Firstly, the tumorous mass needs to be accessible by laryngoscopy to be burned by radiofrequency. Secondly, it cannot completely remove the tumor mass and does not prevent recurrences. But, as emphasized in some articles [7,11], positive margins do not influence overall survival or prognostic factor [5]. This management is used especially for this type of lesion knowing that chondrosarcoma is a slow growing lesion and presents a low rate of metastases. In terms of complications, the main which can occur are edema, hematoma, cough, or transient recurrent laryngeal nerve palsy [24]. This approach requires a close follow-up, with repeated intervention to reduce the airway obstruction following the tumorous growth. Nevertheless, it confers better surgery outcomes, and a better quality of life for the patient.

4. Conclusion

Despite the large tendency of laryngeal low-grade chondrosarcoma to relapse, the use of radiofrequency ablation preserves laryngeal functional properties and therefore gives a better quality of life for the

patient. This conservative approach requires long-term surveillance, as recurrences are still possible, as well as repeated interventions if needed (tracheotomies, radiofrequency ablation and gastrostomy), since there is no complete excision of the tumor. As far as this type of case remains rare, close follow-up care is essential to get a better understanding of the outcomes of such a way of treatment.

This work has been reported in line with the SCARE criteria [25].

Consent

Written informed consent was obtained from the patient for publication and any accompanying images. A copy of the written consent is available for review by the Editor-in-Chief of this journal on request.

Ethical approval

Ethics Committee of the Institution. There is no reference number as all patients give written consent by signing a consent form at their first appointment.

Guarantor

KAYSER Elise.

Funding

This research did not receive any specific grant from funding agencies in the public, commercial or not-for-profit sectors.

Author contribution

Dr. MASTRONICOLA Romina, PhD: supervision of the writing, interpretation.

GIL Artur: data collection, writing of the paper.

BARRAT Agathe: study concept, data analysis, revision of the paper.

KAYSER Elise: data collection, revision of the paper.

TREFFEL Mathilde: data collection, data analysis.

Dr. DOLIVET Gilles, PhD: data collection.

Conflict of interest statement

The authors have no conflicts of interest to declare.

Acknowledgments

The authors would like to express their gratitude to Sophie Cortese and Emilie Beulque for their help in the study concept.

References

- [1] A. Ferlito, K.O. Devaney, A.A. Mäkitie, Differing characteristics of cartilaginous lesions of the larynx, *Eur. Arch. Otorhinolaryngol.* 276 (10) (Jul 23 2019) 2635.
- [2] S.E. Düzcü, Z. Coşgun, H.M. Astarci, Laryngeal chondrosarcoma of the thyroid cartilage, *Türk. Patoloji Derg.* 37 (2) (2021) 178–182.
- [3] O.Y. Chin, P.M. Dubal, A.B. Sheikh, A.A. Unsal, R.C.W. Park, S. Baredes, et al., Laryngeal chondrosarcoma: a systematic review of 592 cases, *Laryngoscope* 127 (2) (Feb 2017) 430–439.
- [4] S. Bathala, S. Berry, R.A. Evans, S. Brodie, O. Altaan, Chondrosarcoma of larynx: review of literature and clinical experience, *J. Laryngol. Otol.* 122 (10) (Oct 2008) 1127–1129.
- [5] J. Choi, H. Dharmarajan, A. Victores, A. Wenaas, J. Ongkasuwan, Chondrosarcoma of the epiglottis: a case report and literature review, *J. Voice Off. J. Voice Found.* 32 (4) (Jul 2018) 484–487.
- [6] I. Buda, R. Hod, R. Feinmesser, J. Shvero, Chondrosarcoma of the larynx, *Isr. Med. Assoc. J. IMAJ* 14 (11) (Nov 2012) 681–684.
- [7] V.M. Talati, M.J. Urban, T.R. Patel, C. Wojcik, B.A. Tajudeen, K. Stenson, et al., Laryngeal chondrosarcoma characteristics and survival analysis in the National Cancer Database, *Otolaryngol. Head Neck Surg.* 166 (1) (Jan 2022) 101–108.
- [8] F. Limaïem, D.D. Davis, K.L. Sticco, Chondrosarcoma, in: *StatPearls [Internet]*, StatPearls Publishing, Treasure Island (FL), 2024 [cited 2024 Nov 5]. Available from: <http://www.ncbi.nlm.nih.gov/books/NBK538132/>.
- [9] C. Piazza, A. Paderno, P. Nicolai, Conservative surgery for laryngeal chondrosarcoma: a review of the most recently proposed approaches, *Curr. Opin. Otolaryngol. Head Neck Surg.* 25 (2) (Apr 2017) 93–100.
- [10] C.M. Moen, A.E. Lim, R.B. Townsley, Low-grade chondrosarcoma of the posterior cricoid plate, *Cureus* 13 (6) (Jun 2021) e15400.
- [11] K. Rüller, C. Sittel, J.C. Kölmel, M. Burghartz, J. Steimer, F. Fiz, et al., Organ preservation strategies in laryngeal chondrosarcoma, *Laryngoscope* 132 (4) (Apr 2022) 838–843.
- [12] A.J. Guthrie, R.L. Chai, Transoral robotic surgery for the treatment of laryngeal chondrosarcoma: a case report, *Am. J. Otolaryngol.* 39 (3) (2018) 352–354.
- [13] S. Righi, P. Boffano, D. Pateras, D. Chiodo, F. Zanardi, R. Patetta, Chondrosarcoma of the laryngeal thyroid cartilage, *J. Craniofac. Surg.* 26 (6) (Sep 2015) e478–e479.
- [14] J.F. dos S. Oliveira, F.A.P.L. Branquinho, A.R.R.T.N. Monteiro, M.E.C.C. Portugal, A.M.F.S. Guimarães, Laryngeal chondrosarcoma—ten years of experience, *Braz. J. Otorhinolaryngol.* 80 (4) (2014) 354–358.
- [15] C. Perrot, S. Cortese, H. Eluecque, R. Mastronicola, C. Sergeant, F. Marchal, et al., Laryngeal chondrosarcoma: repeated laser and radiofrequency ablation in the palliative setting, *Eur. Ann. Otorhinolaryngol. Head Neck Dis.* 130 (2) (Apr 2013) 91–93.
- [16] J.O. Adeola, J.S. Patel, R. Povolotskiy, G.L. Barinsky, J.G. Grube, W.D. Hsueh, et al., Clinicopathologic characteristics of laryngeal chondrosarcoma: an analysis of the national cancer database, *Auris Nasus Larynx* 48 (5) (Oct 2021) 956–962.
- [17] L. Lichtenstein, H.L. Jaffe, Chondrosarcoma of bone, *Am. J. Pathol.* 19 (4) (Jul 1943) 553–589.
- [18] S. Ghatak, T. Jana, P.K. Majumdar, D. Barman, J. Saha, Chondrosarcoma of the arytenoids- a rare laryngeal malignancy, *Indian J. Otolaryngol. Head Neck Surg.* 60 (4) (Dec 2008) 376–378.
- [19] A. Sauter, C. Bersch, K.L. Lambert, K. Hörmann, R. Naim, Chondrosarcoma of the larynx and review of the literature, *Anticancer Res* 27 (4C) (2007) 2925–2929.
- [20] H. Gelderblom, P.C.W. Hogendoorn, S.D. Dijkstra, C.S. van Rijswijk, A.D. Krol, A. H.M. Taminiau, et al., The clinical approach towards chondrosarcoma, *Oncologist* 13 (3) (Mar 2008) 320–329.
- [21] H.M. Jones, Cartilaginous tumours of the head and neck, *J. Laryngol. Otol.* 87 (2) (Feb 1973) 135–151.
- [22] E.M. Potochny, A.R. Huber, Laryngeal chondrosarcoma, *Head Neck Pathol.* 8 (1) (Mar 2014) 114–116.
- [23] R.P. Owen, J.S. Lee, C.E. Silver, L. Bäck, J.J. Beitler, A. Rinaldo, et al., Radiofrequency ablation in advanced head and neck cancer, *Eur. Arch. Oto-Rhino-Laryngol. Off. J. Eur. Fed. Oto-Rhino-Laryngol. Soc. EUFOS Affil. Ger. Soc. Oto-Rhino-Laryngol - Head Neck Surg.* 271 (2) (Feb 2014) 207–210.
- [24] P.P. Issa, K. Cironi, L. Rezvani, E. Kandil, Radiofrequency ablation of thyroid nodules: a clinical review of treatment complications, *Gland Surg.* 13 (1) (Jun 2023) 77.
- [25] C. Sohrabi, G. Mathew, N. Maria, A. Kerwan, T. Franchi, R. Agha, The SCARE 2023 Guideline: Updating Consensus Surgical CASE REport (SCARE) Guidelines 109(5), 2023, p. 1136.