



HAL
open science

Case report: Rare case of laryngeal hypertrophic lichen planus

Elise Kayser, Jacques Thomas, Sophie Cortese, Emilie Beulque, Gilles Dolivet,
Romina Mastronicola

► To cite this version:

Elise Kayser, Jacques Thomas, Sophie Cortese, Emilie Beulque, Gilles Dolivet, et al.. Case report: Rare case of laryngeal hypertrophic lichen planus. *International Journal of Surgery Case Reports*, 2025, 126, pp.110809. 10.1016/j.ijscr.2024.110809 . hal-04892397

HAL Id: hal-04892397

<https://hal.univ-lorraine.fr/hal-04892397v1>


Submitted on 16 Jan 2025

HAL is a multi-disciplinary open access archive for the deposit and dissemination of scientific research documents, whether they are published or not. The documents may come from teaching and research institutions in France or abroad, or from public or private research centers.

L'archive ouverte pluridisciplinaire **HAL**, est destinée au dépôt et à la diffusion de documents scientifiques de niveau recherche, publiés ou non, émanant des établissements d'enseignement et de recherche français ou étrangers, des laboratoires publics ou privés.



Distributed under a Creative Commons Attribution - NonCommercial - NoDerivatives 4.0
International License



Case report

Case report: Rare case of laryngeal hypertrophic lichen planus

Elise Kayser^{a,*}, Jacques Thomas^a, Sophie Cortese^a, Emilie Beulque^a, Gilles Dolivet^{a,b}, Romina Mastronicola^{a,b}

^a Institut de Cancérologie de Lorraine, 6 avenue de Bourgogne, 54519 Vandœuvre-lès-Nancy, France

^b CRAN, CNRS, UMR 7039, Université de Lorraine, Vandœuvre-lès-Nancy, France



ARTICLE INFO

Keywords

Hypertrophic lichen planus
Larynx
Surgery

ABSTRACT

Introduction and importance: Lichen planus is an inflammatory and chronic disease with multifactorial causes. Hypertrophic subtype of lichen planus is an extremely rare lesion when found in the larynx. This article describes the case of a man with such a lesion.

Case presentation: A 54-year-old man presented after respiratory distress with a suspicious mass on the left hemilarynx. The patient consumed a lot of tobacco and alcohol. He underwent nasofibroscope, CT scan and numerous direct laryngoscopies with biopsy. Histopathological analysis finally revealed a mucosal hypertrophic lichen planus. Nowadays, the patient has undergone a partial laryngectomy.

Clinical discussion: Lichen planus is a chronic immune disease with multifactorial causes like stress or genetic susceptibility, for example. Presentations may vary, and histological features include hyperkeratosis and lymphocytic infiltration, which could be the primary cause of tissue damage. Hypertrophic lichen planus is an extremely rare laryngeal lesion, and there are few examples of how it is treated. As in topical treatments for other types of lichen planus, corticosteroids may be helpful. In addition, the potential carcinogenic transformation of this type of lesion is not well known, and follow-up care is therefore required.

Conclusion: A patient presented with a hypertrophic lichen planus lesion in the larynx, which is an extremely rare location. Thus far, he has undergone surgery to treat it.

1. Introduction

The lichen planus (LP) is an inflammatory disease, immune-mediated and chronic which can occur in both men and women [1,2]. Moreover, it would be caused by a T cell-mediated immune response whose origin is unknown [3]. It can affect many areas, among them the skin, the hair, the nails or the mucous membranes [4]. Presentations can include polygonal and violaceous papules, generally pruritic [5]. LP affects between 1 and 2 % of the world's population [6]. The most common type encountered is oral lichen planus, which can occur in the buccal mucosae, gingivae or in the tongue, with white striations. Hypertrophic lichen planus (HLP) is a variant of LP, whose diagnostic can be more difficult. Histologically, HLP includes epithelial hyperplasia, lymphocytic infiltration with presence of eosinophils, and hyperkeratosis [2]. Differential diagnosis can be quite broad and embraces malignant neoplasms like squamous cell carcinoma, connective tissue diseases like hypertrophic lupus erythematosus, fungal infections or even viral verrucae [2]. Rare cases of HLP have been described on the lip

or in the external auditory canal [3,4]. Very few cases have been reported of HLP in the laryngeal area, and the malignant potential of this type of lesions is not well known [1,7].

2. Case report

A 54-year-old man presented after a respiratory distress with a suspicious mass on the left hemilarynx. At this stage, the lesion was uncharacterizable. Medical history included chronic obstructive pulmonary disease and high blood pressure. Moreover, the patient reported a 6-months dysphonia. Social history showed that the patient had huge tobacco (one pack of cigarettes per day for forty years) and alcohol use. Trachea nasofibroscope revealed an exophytic lesion, of whitish colour, on the left vocal cord, with a mobile glottic plan. The patient underwent an ear, nose and throat CT scan, showing a laryngeal process reaching the glottic and supraglottic area. Direct laryngoscopy was indicated then, with biopsy.

* Corresponding author.

E-mail addresses: elisekayser.pharma@gmail.com, r.mastronicola@nancy.unicancer.fr (E. Kayser).

<https://doi.org/10.1016/j.ijscr.2024.110809>

Received 29 November 2024; Received in revised form 21 December 2024; Accepted 28 December 2024

Available online 30 December 2024

2210-2612/© 2024 The Authors. Published by Elsevier Ltd on behalf of IJS Publishing Group Limited. This is an open access article under the CC BY-NC-ND license (<http://creativecommons.org/licenses/by-nc-nd/4.0/>).

3. Investigations

The anatomopathological analysis of the biopsy of the left hemilarynx revealed a papillomatous Malpighian lesion with parakeratosis, with dysplasia aspects, from medium to severe. There was no invasive carcinomatous structure, but at this time, the hypothesis of a well-differentiated carcinomatous lesion could not be moved aside. The lesion kept growing for one year and a half, causing the entire larynx to stiffen. A supplementary direct laryngoscopy with biopsy was indicated. Ten days before the operation, the patient had a new episode of acute respiratory distress, entailing the placement of a tracheostomy. The patient then underwent the direct laryngoscopy and many biopsies of the left larynx. A Tucker (frontolateral) partial laryngectomy by cervicotomy was realized. The conclusion of the anatomopathological analysis revealed then a mucosal hypertrophic lichen planus. Figs. 1–3 describe the complete histological analysis. Figs. 4–6 describe the immunohistochemical status of various genes. Fig. 7 shows the computed tomography scan (CT scan) performed 9 months after the partial laryngectomy. The patient no longer has any breathing space except his trachea, because of the complete invasion of the larynx by the lesion. Consequently, total laryngectomy is considered as the final treatment.

4. Discussion

Lichen planus is an immune chronic disorder, whose cause can be a multifactorial process. Indeed, it may be induced by stress, mucous exciting factors or allergy, endocrine disorders, genetic susceptibility or immunological illnesses [8]. It is known to be an adult disorder, with a female predominance, even though a few cases have been reported in pediatric population [9].

Hypertrophic lichen planus, also known as lichen planus verrucous, may appear with various clinical presentation, like thickened papules or plaques [5]. Histological characteristics are the same as cutaneous lichen planus, and embrace hypergranulosis, hyperkeratosis, and lymphocytic infiltration. HLP occurs mainly in the ankles or in the upper and lower limb. Consequently, laryngeal localization is extremely rare. Pathogenesis of lichen planus has not been completely elucidated, but there are many trails to explain its apparition. Indeed, lichen planus is a T cell-mediated phenomenon, with infiltration of such cells in the concerned tissues. Therefore, the infiltration causes tissue damages and creates an inflammatory environment [2,10]. This immune

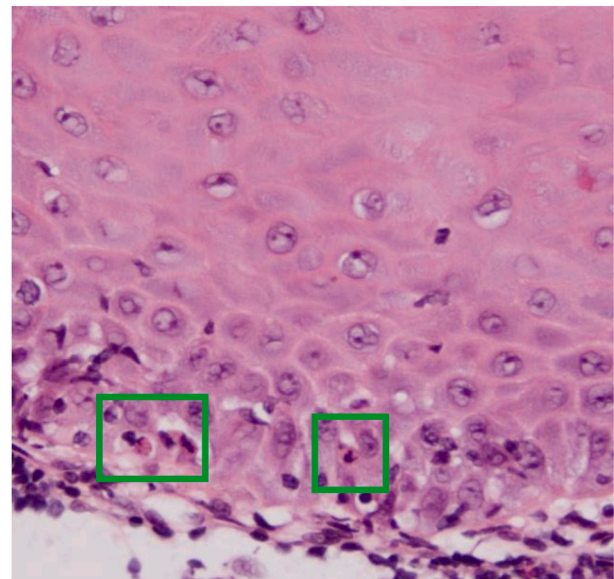


Fig. 2. Histological view of hypertrophic lichen planus at magnification $\times 40$; the green frames show apoptotic bodies. (For interpretation of the references to colour in this figure legend, the reader is referred to the web version of this article.)

phenomenon could be worsened by tobacco and alcohol consumption.

The potential carcinogenic transformation of HLP is not well known, but could be the result of either the intrinsic to the lichen planus lesions or the consequence of the patient's immune system [11].

The treatment of lichen planus can be managed in various ways. For cutaneous cases, topically treatments exist, based on immunosuppressants, with most commonly corticosteroids [8]. Antioxidants can be used in the case of oral lichen planus. For laryngeal LP, there are too few cases referenced, but there is one example of steroids-based treatment where the patient had no recurrence [7]. Literature reports no cases like ours treated by surgery. However, since the laryngeal area is completely invaded by the lesion, this lead to massive respiratory distress. The larynx is no longer functional and affects one of the systems of which it is a part. In this case report, surgery through partial or total laryngectomy is the way of treatment considered in order to re-establish the breathing capacity of the patient. He will then undergo close follow-up care (every

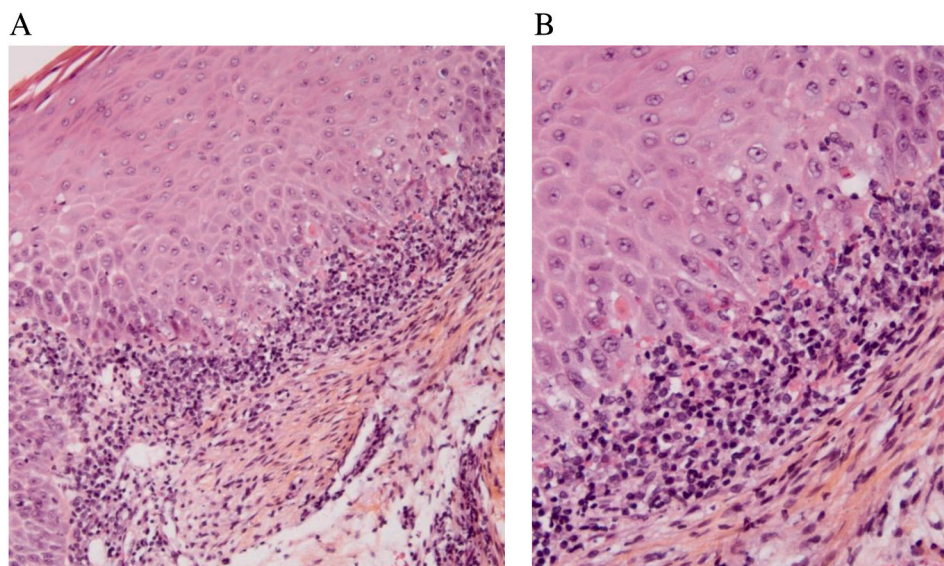


Fig. 1. Histological view of hypertrophic lichen planus; A: magnification $\times 10$; B: magnification $\times 20$.

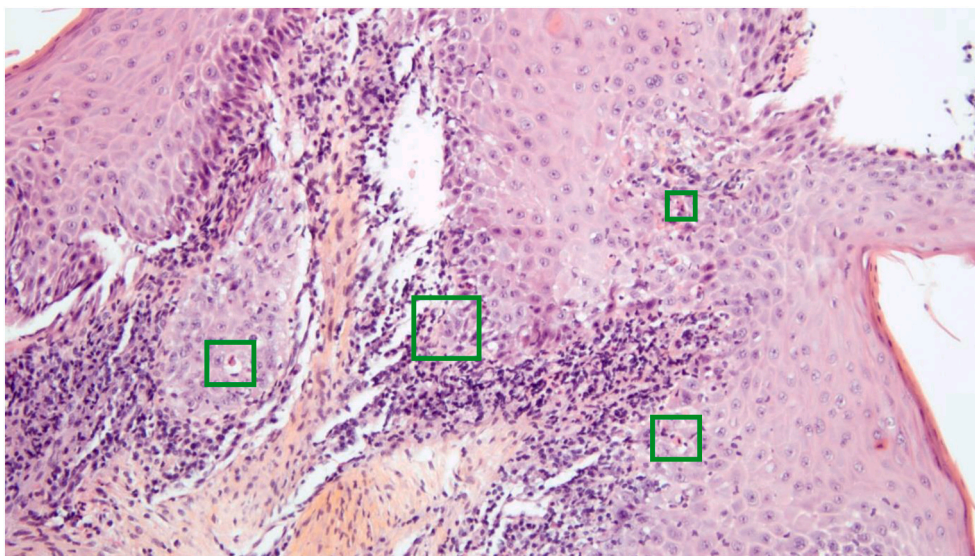


Fig. 3. Large view of histological hypertrophic lichen planus at magnification $\times 10$; the green frames show apoptotic bodies.

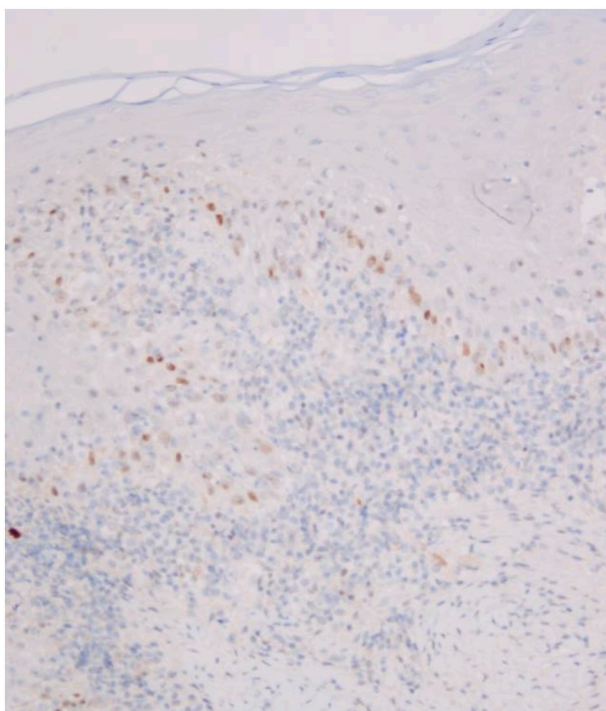


Fig. 4. Immunohistochemical view; p53: basal and low heterogenous.

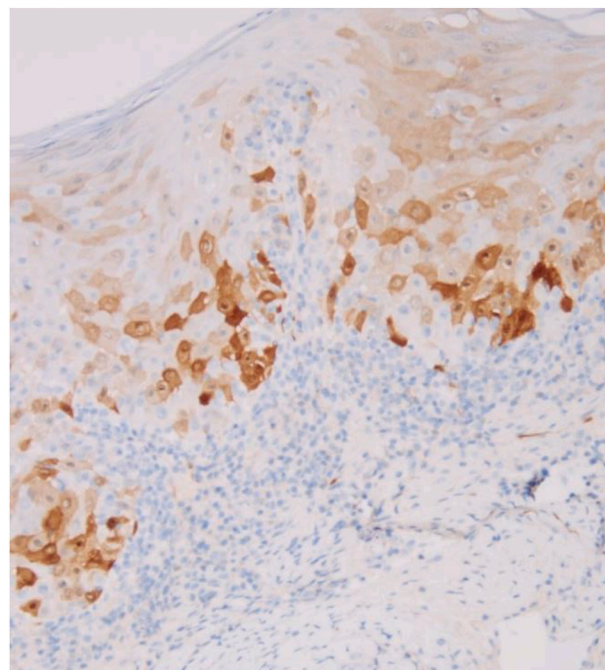


Fig. 5. Immunohistochemical view; p16: not overexpressed (patchy < 50 %).

three months at least), to examine the results of this treatment.

5. Conclusion

Lichen planus lesions impact 1 to 2 % of the world's population and have many clinical presentations. Their apparition is multifactorial, and their potential carcinogenic transformation is currently not well known. However, laryngeal hypertrophic lichen planus is extremely rare. Therefore, there are very few ways of treatment described in the literature. This case has presented surgical management and the steps leading to this decision.

This work has been reported in line with the SCARE criteria [12].

CRedit authorship contribution statement

KAYSER Elise: writing of the paper, data collection and analysis.
 THOMAS Jacques: data collection, data analysis, providing some of the results (anatomopathological).
 CORTESE Sophie: study concept, data analysis.
 BEULQUE Emilie: study concept, data analysis.
 DOLIVET Gilles, PhD: study concept, data collection.
 MASTRONICOLA Romina, PhD: supervision of the writing, management of the case, study concept, data collection and analysis.

Consent

written informed consent was obtained from the patient for publication and any accompanying images. A copy of the written consent is

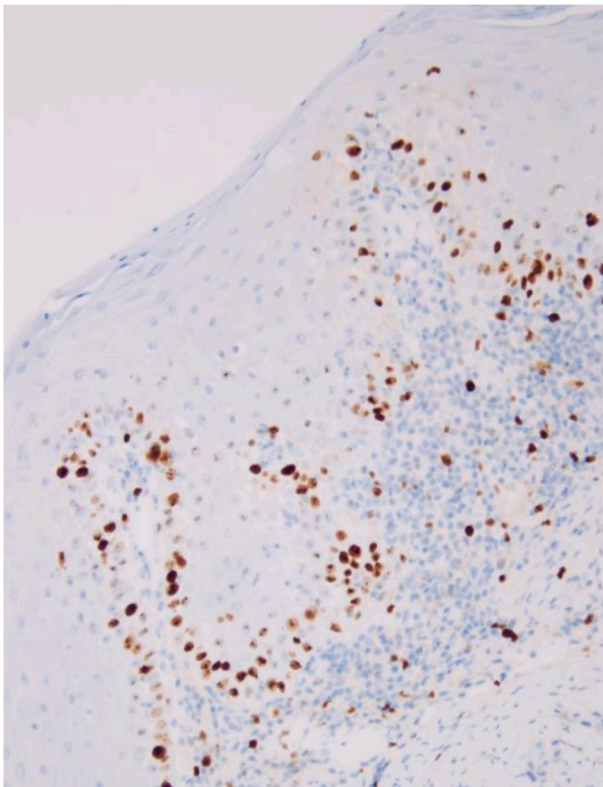


Fig. 6. Immunohistochemical view; Ki67: basal and non-ascended.

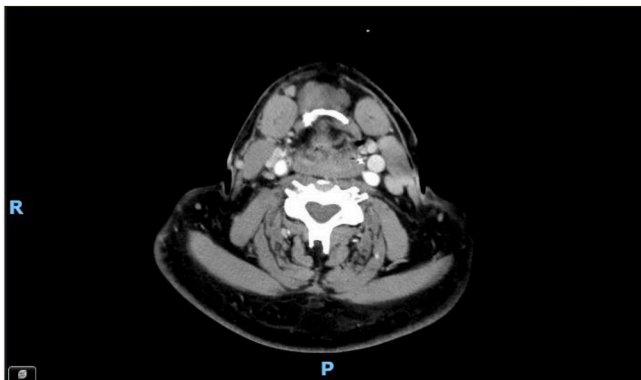


Fig. 7. 9 months-post-operative CT scan; no respiratory space can be seen, showing that the patient can only breathe with his trachea.

available for review by the Editor-in-Chief of this journal on request.

Ethical approval

Ethics Committee of the Institute. There is no reference number as all patients give written consent by signing a consent form at their first appointment.

Guarantor

KAYSER Elise

Sources of funding

this research did not receive any specific grant from funding agencies in the public, commercial or not-for-profit sectors.

Funding

This research did not receive any specific grant from funding agencies in the public, commercial or non-profit sectors.

Declaration of competing interest

None.

References

- [1] A.M. Bulfamante, U. D'Agostino Fiorenza, P. Castellarin, C. Pipolo, G. Cacioppo, G. Felisati, et al., Identification of putative laryngeal and pharyngeal lichen planus lesions: an endoscopic preliminary evaluation in 16 patients, *Clin Otolaryngol Off J ENT-UK Off J Neth Soc Oto-Rhino-Laryngol Cervico-Facial Surg.* janv 46 (1) (2021) 84–87.
- [2] Whittington CP, Saleh JS, Bresler SC, Patel RM. Hypertrophic lichen planus: an up-to-date review and differential diagnosis. *Arch. Pathol. Lab. Med.* 1 juin 2024;148 (6):659–65.
- [3] A. Košec, M. Kostić, J. Ajduk, M. Ries, Hypertrophic recurring lichen planus of the external auditory canal, *Eur Ann Otorhinolaryngol Head Neck Dis.* avr 136 (2) (2019) 123–126.
- [4] N. Mozafari, F. Bidari-Zerehpooosh, M. Movahedi, S. Dadkhahfar, Hypertrophic lichen planus on lip mimicking SCC, *Clin Case Rep.* août 10 (8) (2022) e6191.
- [5] G. Weston, M. Payette, Update on lichen planus and its clinical variants, *Int J Womens Dermatol.* août 1 (3) (2015) 140–149.
- [6] P. Parashar, Oral lichen planus, *Otolaryngol Clin North Am.* févr 44 (1) (2011) 89–107 (vi).
- [7] C.E. Rennie, R.C. Dwivedi, A.S. Khan, N. Agrawal, W. Ziyada, Lichen planus of the larynx, *J Laryngol Otol.* avr 125 (4) (2011) 432–435.
- [8] Nosratzahi T. Oral Lichen Planus: an Overview of Potential Risk Factors, Biomarkers and Treatments. *Asian Pac J Cancer Prev APJCP.* 26 mai 2018;19(5): 1161–7.
- [9] J.J. Lee, R. Kim, M.Y. Lee, J.Y. Byun, Y.W. Choi, H.Y. Choi, A case of linear hypertrophic lichen planus in a pediatric patient, *Ann. Dermatol.* 35 (Suppl. 2) (2023) S256–S259.
- [10] P.B. Sugerman, N.W. Savage, L.J. Walsh, Z.Z. Zhao, X.J. Zhou, A. Khan, et al., The pathogenesis of oral lichen planus, *Crit Rev Oral Biol Med Off Publ Am Assoc Oral Biol.* 13 (4) (2002) 350–365.
- [11] F. Gorouhi, P. Davari, N. Fazel, Cutaneous and mucosal lichen planus: a comprehensive review of clinical subtypes, risk factors, diagnosis, and prognosis, *ScientificWorldJournal* 2014 (2014) 742826.
- [12] Sohrabi C, Mathew G, Maria N, Kerwan A, Franchi T, Agha RA, et al. The SCARE 2023 guideline: updating consensus Surgical CAse RReport (SCARE) guidelines. *Int J Surg Lond Engl.* 1 mai 2023;109(5):1136–40.